

ANNALS

—OF—

GYNÆCOLOGY AND PÆDIATRY.

VOL. VI.

MAY, 1893.

No. 8

ORIGINAL COMMUNICATIONS.

My Recent Ureteral Work.¹

BY HOWARD A. KELLY,

*Professor of Gynæcology and Obstetrics in the Johns Hopkins University,
Baltimore.*

INTRODUCTORY.

I HAVE elected to bring before you this evening my practical experience in ureteral work, because I know of no subject within the wide range of gynæcology at the present time more deserving of our close critical attention, for two reasons, *first, the eminently valuable practical results attainable* by an intelligent application of the knowledge already in hand, and *second, because the immediate future is destined to evolve new facts of paramount importance*, and to the credit of our past history we ought to be among the pioneers.

Let me fix your attention, therefore, on the subject in hand by reminding you for a moment of the anomalously

important position occupied by the ureters in the animal economy. Their function is that of transmitting the fluid excrement from those vitally-important emunctories, the kidneys. Disease of one of these delicate tubular excretory conduits affects its lumen, interferes with transmission of the urine, and thus involves the corresponding kidney. Complete stoppage of the ureter quickly destroys the functional value of its kidney. A serious affection of both ureters is incompatible with prolonged life.

The gynæcologist has a three-fold reason for his interest in this field adjoining his own territory. In the *first place, definite causal relations often exist between pelvic diseases and ureteral and kidney affections*. Thus a tuberculous bladder is an initial stage of a tuberculous ureter. Cancer of

¹ Read before the Philadelphia Obstetrical Society, April 6, 1893.

the uterus often destroys life by uræmia induced by pressure on the ureters.

I have observed in my own work the association of a pyosalpinx choking the pelvis on the left side with an extensive pyelonephrosis of the same side.

I have seen death occur from the pressure of a large myoma upon both ureters. Both kidneys were very greatly enlarged ($17 \times 7 \times 5\frac{1}{2}$ cm. and $17 \times 6 \times 4\frac{1}{2}$ cm.) and filled with purulent foci. The ureters were dilated above and slightly adherent to the tumor (*vide* Johns Hopkins Hospital Reports, Vol. II, Nos. 3 and 4, Gynæcology, p. 168). Dr. Arthur Johnstone has observed and reported a similar

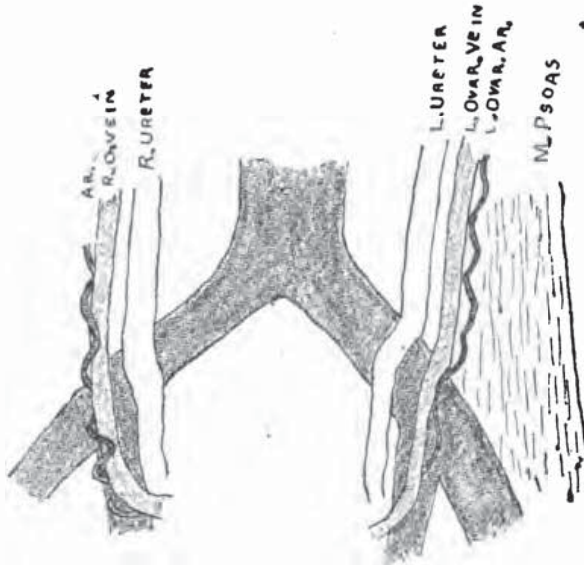


FIG. 7.—Relation of ureters at pelvic brim.

effect from the pressure of an ovarian tumor. (Plate I, Fig. 1).

A death from the pressure of an ovarian tumor on the ureter is reported by Bert (*vide* Frommel's *Jahresbericht*, Vol. IV, p. 684). (Plate I, Fig. 2).

I have observed in a little girl a large right hydro-ureter coursing over the anterior face of a retro-peritoneal sarcoma which filled the pelvis and expanded into the abdomen.

Dr. Skene was stimulated to write his valuable paper on "Injuries to the Ureters During Labor," in the *Proc. of the Amer. Gyn. Soc.*, Vol. XV, p. 149, by a death from involvement of the left ureter in a tear during labor coming under his observation.

A distinguished Boston surgeon cut off a piece of a ureter in removing an ovarian tumor.

In enucleating an enormous cysto-

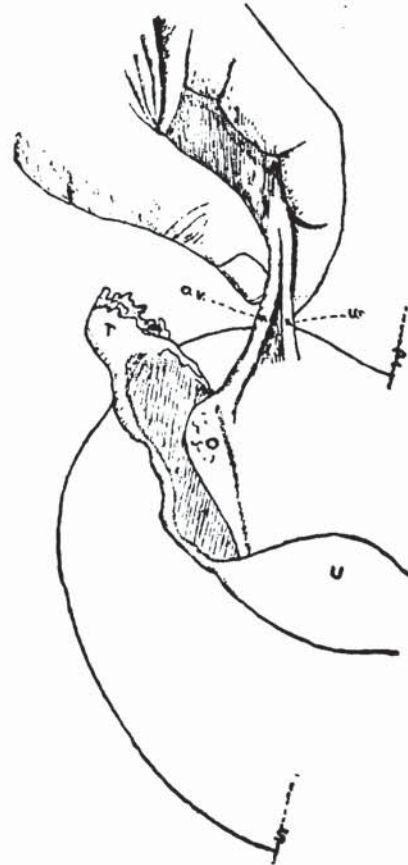


FIG. 8.—Sketch showing danger of ligating ureter.

myoma I ligated the ureter, and in another case, in attempting an abdominal hysterectomy for cervical cancer, I ligated the left ureter low down on the pelvic floor.

These are a few illustrations which might be multiplied many times.

The gynæcologist has a further quickening interest in ureteral work in that *the ureter is accessible to exploration, and a special skill and tact are*

required, which he has already developed in his work.

Lastly, the gynæcological field has been so rapidly narrowing and tending to crystalize, that it is refreshing to find close by a *new* and interesting field of investigation, one which brings with it as well a large part of the domain of renal pathology, up to the present often approached by the gynæcologist with an apology.

ANATOMY OF THE URETERS.

The ureters are flattened white

10 or 12 cm. long, while the abdominal portion is from 12 to 15 or more.

The most inaccessible portion is that nearest the kidney, where it lies concealed by the ribs, from 4 to 4.5 cm. from the median line, and about the same distance posterior to the anterior face of the vertebral column. (Plate II, Fig. 3).

The middle part of the abdominal portion lies from 2.5 to 3 cm. from the median line, on the psoas muscle, on a plane on a level with the anterior faces of the vertebral bodies. The

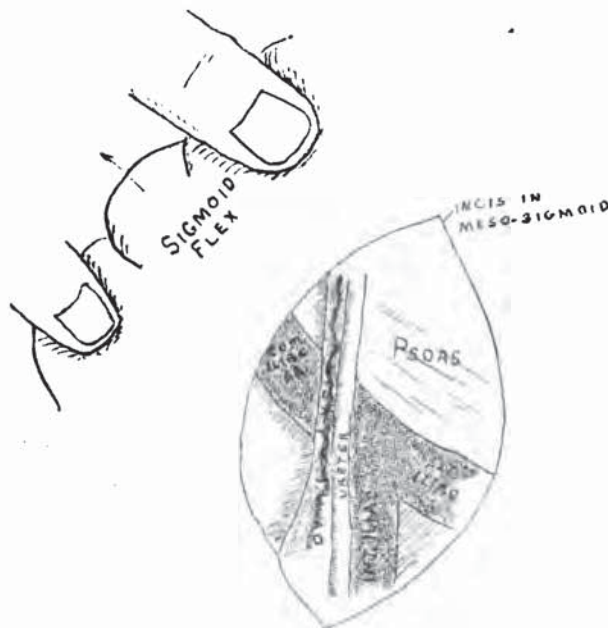


FIG. 9.—Ureter in relation to mesosigmoid.

cords about .5 cm. in diameter, from 25 to 30 cm. in length, extending from the pelvis of each kidney high up in the loins under the vaulted arch of the thorax down to their embouchure in the urinary bladder.

Each ureter is naturally and for practical purposes divided into two parts—an abdominal and a pelvic portion—by the bend over the common iliac artery at a plane about 3 cm. above the brim of the superior strait.

The pelvic portion is not more than

ureter crosses the psoas obliquely to the internal iliac artery at or just above its bifurcation, where it is about 3 cm. from the middle of the promontory of the sacrum. The course is thus obliquely downward and inward, exhibiting a slight inward convexity, and always with marked convexity forward, due to its course over the psoas.

The ureters lie in the loose cellular tissue back of the peritonæum and partly under the caput coli and the

ascending colon on the right, and descending colon and sigmoid flexure on the left side.

The abdominal ureter holds no relations to important vessels until joined somewhere about or above the middle of its course by the ovarian vessels, artery, and vein, which cross it to descend into the pelvis along its outer border. At the brim of the pelvis on the right side the ureter lies just behind the peritonæum, where it can be seen with the ovarian vessels. The peritonæum can be incised at this point, and the ureter thus easily laid bare. (Plate II, Fig. 4; Plate III, Fig. 5; Plate I, Fig. 6.)

On the left side the relations of the ureter to the sigmoid flexure and the rectum depend entirely upon the length of the meso-sigmoid and the variable position over the superior strait at which the rectum enters the pelvis. Thus in one case the ureter lies behind the sigmoid veins and arteries, and in another directly behind the intestine. (Fig. 9).

After crossing the psoas it crosses the common iliac artery obliquely above its bifurcation, dropping into the pelvis at this point. The pelvic portion of the ureter usually lies at first to the inner side of the internal iliac artery, occasionally it lies to the outside, it is again crossed by the ovarian vein and artery, which leave it at an acute angle just above the brim of the pelvis (the brim as made by the muscle, and not the bony pelvis). The pelvic portion of the ureter descends to the floor of the pelvis in the loose cellular tissue in a forward direction, it passes directly under the uterine artery and the base of the broad ligament, alongside the upper lateral vaginal wall, and finally curves in over

the anterior vaginal wall, following its uppermost converging folds, and terminates in the bladder, where the two ureteral orifices are connected by the inter-ureteric ligament. (Figs. 11, 12, 13).

PALPATION OF THE URETERS.

I have thus dwelt upon the course and the relations of the ureters that I may be able to demonstrate clearly the feasibility of palpating them more extensively than has ever been done. The ureter can be palpated through the anterior vaginal wall from its terminus in the bladder up to the point where it passes beneath the broad ligament. It is rolled in the loose cellular tissue under the index finger, or often better bimanually under two fingers, or in advanced pregnancy on the head of the child like a narrow tape or flattened cord, without hardness. It must not be mistaken in this position for the obturator artery or nerve, or the upper border of the levator ani, or fibres of the obturator muscle, or the rim of the foramen.

A diseased ureter becomes nodular and thickened, and is peculiarly prone to be mistaken for a cellulitis or an adherent ovary. I have demonstrated this fact on numerous occasions for a number of years.

A large percentage of cases under treatment to-day for cystitis and for irritable bladder are in reality tender thickened ureters, and an intelligent palpation will detect the tube now hard and cord-like, bringing out the characteristic complaint of intense desire to urinate. One patient in whom I persisted in making the examination was actually forced to urinate on my hand.

An enlarged ureter can easily be

further palpated per rectum behind the broad ligament, and followed from there up over the posterior pelvic wall, as I was also able to demonstrate only last week on a case in the hospital.

I have found that *the normal ureter can also be traced and minutely examined in the upper part of the pelvic*

the rectum, on the catheter, and any alterations in its calibre noted almost as minutely as when laid bare by dissection.

At the pelvic brim the ureter can also be felt per rectum.

It can be felt at the brim less distinctly through the anterior abdominal

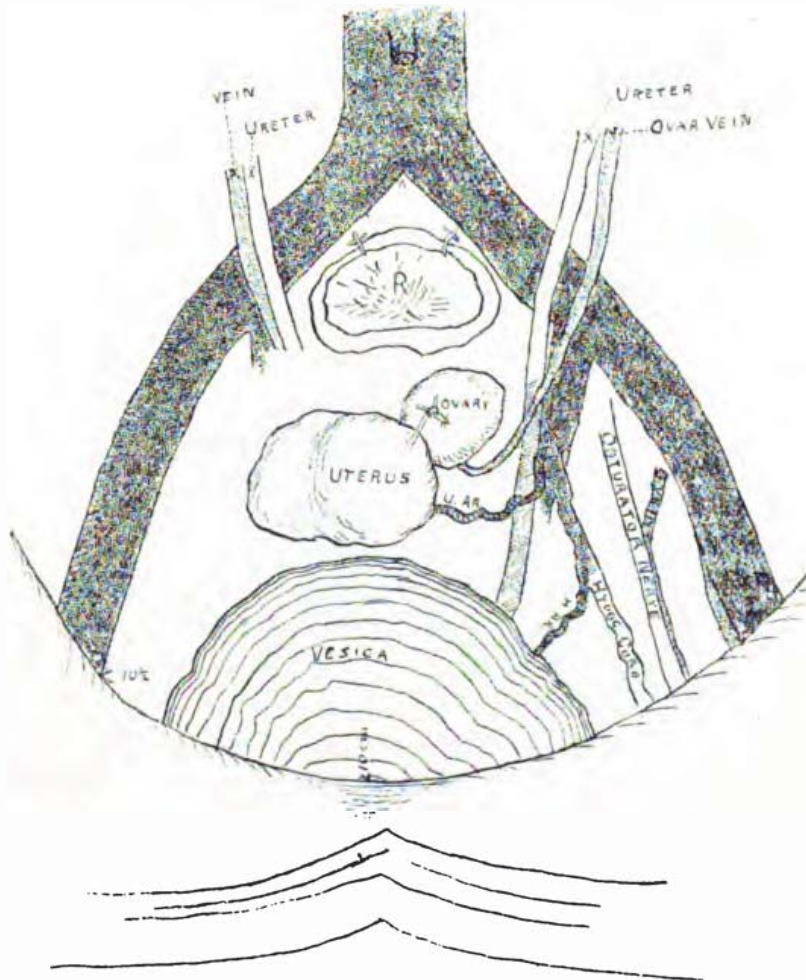


FIG. 11.—Pelvic portion of ureter from below.

course by introducing a ureteral catheter through the urethra and bladder into the ureter, and carrying it up to or over the brim of the pelvis. When an inflexible catheter is thus carried over the brim, the ureter is displaced upward and straightened out. It can now be palpated almost as plainly through

the rectum, where it can also be followed for 6 or 8 cm. up toward the kidney, while the catheter remains in place.

My landmark for the upper portion of the pelvic ureter is the internal iliac artery, which can readily be felt per rectum.

In some cases the artery can be pal-

pated up to the common iliac artery. Close along the inside of this artery the ureter can be felt; if nothing is felt, the conclusion that this portion of the ureter is not enlarged is safe.

Among the efforts made to locate the abdominal portion of the ureters by surface landmarks, I know none which have thus far proven satisfactory.

My own method is to locate the promontory of the sacrum by pressure through the abdominal wall, and from this to locate the point at which the ureter enters the pelvis from 3 to 3½ cm., outside of and a little below the promontory; by pressing deeply at this point, the fingers at once recognize the pulsations of the common iliac artery, a sign that the correct spot has been found. A large ureter can be felt at this point through thin walls. The patient will always complain of severe pain, and often of a desire to urinate when a sensitive or inflamed ureter is touched. (Plate IV, Fig. 14.)

A woman entered my office last week complaining of old-standing bladder trouble, for which she said she had taken in the past year hundreds of injections. I found no evidence at all of bladder disease; the ureters were found thickened and tender through the vagina, and on pressing through the abdomen upon this point she at once complained of severe pain, not felt either inside or just outside a certain spot. Upon asking what kind of pain it was, without any hint as to my expectation, she replied it was accompanied with a strong desire to urinate. The left side exhibited the same peculiarity in lesser degree.

I have also palpated the thickened pelvic ureter after incising the vault of the

vagina, when I was able to follow it up to the posterior wall of the pelvis. I palpated the ureter four years ago through an abdominal incision made for the purpose of examining into the condition of the whole ureter.

A direct examination of the ureter from a point four or five centimeters below the pelvic line up into the abdomen to the kidney is easily made through an abdominal incision, but being part of the technique of certain procedures to be described later, will not be dwelt upon here.

CATHETERIZATION, SOUNDING AND DILATING.

By catheterization of either ureter we are able to secure, isolated, the urine from the respective kidney of that side, containing evidence of disease of the ureter, pelvis of the kidney, or the kidney itself above the catheter, according to the microscopic character of its sediment, associated with the history and physical signs. (Plate IV, Figs. 16, 17, 18.)

I observe the following routine in catheterizing: First all the urine in the bladder is drawn off and put to one side, then the bladder is distended with 150 to 200 cc. (about six ounces) of a methyl-blue solution. It is now evident that if the catheter enters the ureter in the catheterization and clear urine is discharged by the catheter it does not come from the bladder. There is one possible source of error—when the lower part of the ureter is so distended that the water from the bladder backs up into it and so escapes through the catheter; this will be obviated by carrying the catheter still higher up. I have noted this peculiarity twice.

There are two ways of introducing the catheter: the usual method is the one followed by Pawlik, by retracting the posterior vaginal wall and introducing the ureteral catheter into the bladder, and turning its point forward and trying to introduce it by observing the play of the point of the catheter over the anterior wall, as it seeks the ureteral orifices in the ureteral folds described by Pawlik in his admirable work¹ which I have here. The ureters lie a little above or in the upper part of this fold, one or two

during an extensive cauterization, thus avoiding injury of the ureter, which was dangerously close to the infection, and which could now be distinguished by touch so long as the catheter remained in place.

In unilateral disease I have found the urine from one kidney alkaline and from the other acid.

Hæmaturia.—In two cases treated within the past six months the patients had been weakened and rendered profoundly anæmic by a prolonged persistent hæmaturia of un-

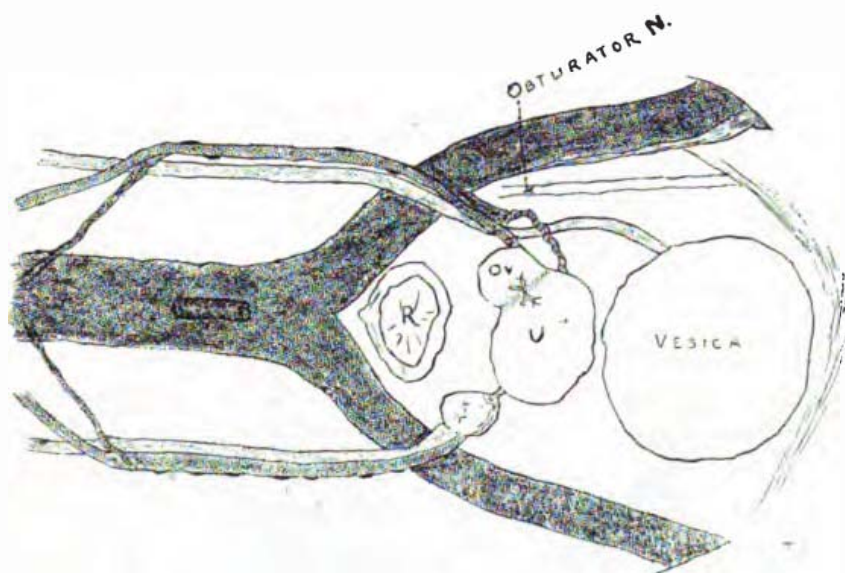


FIG. 12.—Pelvic portion of ureter from side.

centimetres to the right and left of the median line.

Carcinoma.—Neighboring inflammatory trouble and neoplasms distort the normal relations of the ureteral orifices, and catheterization may prove difficult. In a case examined a few weeks ago I found the orifice, after a long search, high up to the left on the anterior face of a prominent ridge in the bladder. The patient had a cancerous infiltration of the left parametrium, and I introduced the ureteral catheter and left it in place as a guide

certain origin. Proceeding to catheterize the ureters for the purpose of making a diagnosis as to its source, I collected and preserved the urine in the bladder, which was of a deep red color, due to the presence of large numbers of red blood corpuscles. The bladder was washed out and the blue aniline solution injected. A catheter was then introduced into each ureter and in one case from the right and in the other from the left catheter, red drops, apparently of pure blood, were discharged at intervals, while from the opposite catheter clear urine flowed. Upon mixing the two I

¹ v. Langenbeck's Archiv., Band xxxiiii, Heft 3.

secured a fluid of the same shade of red as that drawn from the bladder before injecting the aniline.

Hydro-ureter.—In another case, while clear urine flowed at intervals of a few seconds drop by drop from the catheter in the right kidney, no urine at all flowed, during ten minutes, from the left. I then persisted in my attempt to get the catheter, which was introduced as far back as the posterior pelvic wall, up over the brim. Finally it passed an obstruction, and there at once followed a discharge of 100 cc. of turbid lemon-yellow urine, demonstrating that I had passed a stricture and tapped a hydro-ureter. The stricture was dilated by bougies shortly to be exhibited, but the patient left the hospital before she was cured.

Kolpo-ureterotomy for Treatment of Stricture of the Ureter.—In another instance¹ I demonstrated a tight stricture posterior to the right broad ligament and a hydro-ureter above this, and as I could not then treat a tight stricture in this position through the bladder, I introduced a sound into the ureter and cut down upon it in the vault of the vagina, just in advance of the cervix, laid the ureter open for about one centimetre, and sutured it to the vaginal mucosa by means of a delicate needle and fine silk, making an artificial uretero-vaginal fistula. From this position through the fistula I dilated the stricture at several sittings, finally even carrying in uterine dressing forceps. The stricture overcome, the edges of the fistula were denuded and the opening closed by silk sutures without difficulty. The patient was relieved for some months,

¹ Johns Hopkins Hospital Report in Gynecology, No. 1, Article xiv, Balt., Sep., 1890.

but her old pains came back, requiring eventually the performance of a ureterectomy removing the kidney with the ureter down below the pelvic brim. When this patient returned to me, three and a half years later, I found that the ureter was not lessened in calibre at the point where it had been laid open, but that there was a long tubular stricture back of the broad ligament, extending up toward the pelvic brim, and on passing this, *a steady flow of turbid, yellow, watery fluid escaped in a continuous stream*, amounting in all to about 120 cc. in five minutes, *demonstrating the presence of hydro-ureter.*

The bite of the stricture on the sound in this case, as in the first, was plainly recognized by eight or ten physicians present, who took hold of the catheter and pulled on it, perceiving clearly that it was fixed.

The examination of this fluid was entrusted to Dr. Russell, of the gynecological staff, who found numerous tubercle bacilli, *demonstrating the existence of a tuberculous ureteritis*, probably associated with a tuberculous nephritis. Urine from the opposite kidney contained no bacilli, and was normal except for some blood corpuscles, which were supposed to come from trauma from the catheter.

Enlarged Spleen Mistaken for Kidney.—A case recently in the private ward is this: Miss J. came complaining of a tumor discovered in her left side. At the first examination, relying upon a tympanitic percussion note over the mass and the location of the tumor between the umbilicus and the posterior lumbar region, together with the presence of splenic dulness in its normal position, I thought the tumor was a kidney. Her urine was,

moreover, alkaline. I catheterized both ureters. The left catheter passed well back toward the loin instead of forward into the tumor, and it moved but slightly on pushing the tumor about, and an equal amount of normal acid urine was drawn from both kidneys. There was presumptively no renal disease. A more careful examination proved it to be a leucocythæmic spleen.

be an enlarged right kidney. The important questions were "Does the pus come from this kidney?" "Is the other kidney sound enough to do the work of two if the right is removed?"

After emptying and washing the bladder clean and injecting the aniline solution I passed catheters into both kidneys. From the left came pure, clear urine. On the right side nothing came after waiting for ten

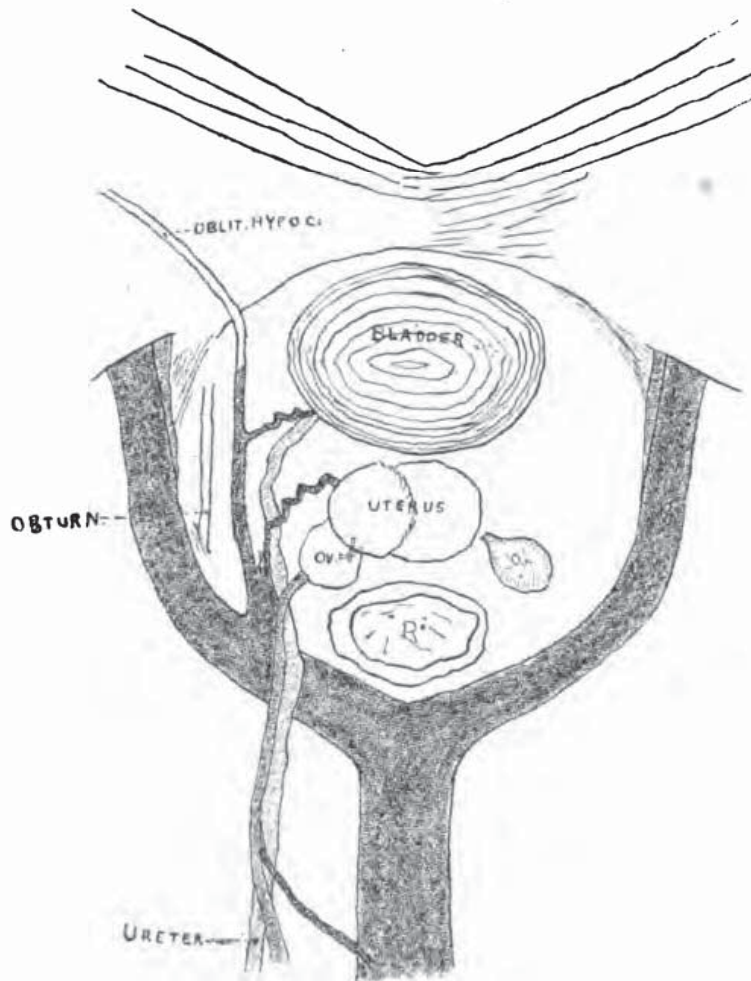


FIG. 13.—Pelvic portion of ureter from above.

Pyelonephrosis.—A case which has just gone home from the common ward was this: Mrs. G. was losing flesh and feeling utterly prostrated, but without any pain or definite complaint. I found a large quantity of pus constantly in the urine. In the right groin was a fluctuant swelling, not tender on pressure, believed to

minutes. The catheter was withdrawn, and a little pus found in the eye. It was reintroduced and carried higher, passing a stricture below the brim rendering well up into the abdomen, when drops of pure pus at once began to flow into the collecting vessel. I then without fear cut down into the right kidney and opened a large abscess, letting out

about 500 cc. of pus and removing a large calculus choking the pelvis, projecting into the ureter and into the kidney substance, and a number of smaller calculi, which I show here.

The patient made a rapid, uninterrupted convalescence, and now passes clear urine. She went home some weeks ago.

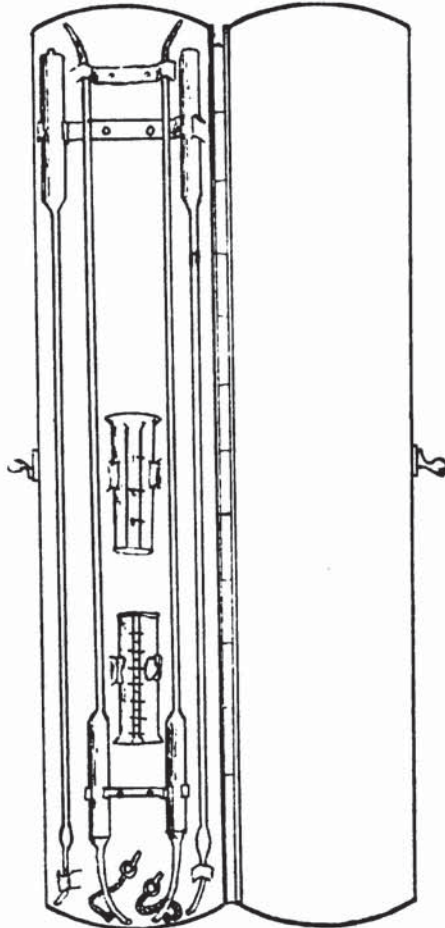


FIG. 19.—Case of ureteral instruments.

THE URETERAL SOUND.

A solid sound is of advantage in searching for ureteral calculi. The accompanying graduated sound is intended to measure the distance of a stone from the urethra, as well as to sound for stone in the pelvis of the kidney.

URETERAL BOUGIES.

Bougies bulbous behind the tip in a

graduated series such as are here shown are valuable in dilating strictures in the lower half of the ureter. Simple strictures, however, will rarely be found. They will almost always be associated with calculus, pyelonephrosis or multiple strictures involving the whole ureter, or tuberculous infiltration or fibrous thickening of the whole ureter.

I have devised the instruments here shown, and use them in my clinic at the Johns Hopkins Hospital.

In order to carry the ureteral catheter or sound over the brim of the pelvis, it is not necessary to use a flexible instrument. This can be effected by first filling the bladder with sufficient fluid (150-200 cc.), to distend its folds and introduce the catheter into the ureter, and then drawing off all the contents of the bladder, a finger introduced into the rectum high up, gently lifts the catheter and assists it over the brim and on up into the abdomen. This manœuvre is rendered possible by the loose cellular tissue in which the pelvic organs lie, allowing a wide displacement of bladder, ureter and broad ligament without injury. The contracted bladder can be lifted up, while it is impossible to displace the full bladder in this way.

ESTIMATION OF THE QUANTITY OF URINE FROM EACH KIDNEY.

One of the valuable uses of the ureteral catheter is in determining the functional activity and value of both kidneys, as well as the condition of the urine. In one case of tuberculous ureter I drew, as I have stated, acid urine from the right ureter, and alkaline urine from the diseased left side.

I always make the urine drawn the basis of a calculation of the day's secretion of urine. If it is drawn from but one kidney, it must be remembered that but half the full amount is called for in the calculation. *I leave the catheter in place a definite number of minutes, ten or fifteen, or even thirty, and every drop of urine escaping is caught in a minim or cubic centimetre graduate, and the twenty-four hours urine is calculated from this.* In numerous instances, to my surprise, this has amounted to precisely, or close to, 1500 cc. About half a cc. a minute from each kidney, or one cc. from both is the normal quantity. That is 60 cc. an hour, or in twenty-four hours $24 \times 60 = 1440$ cc., in the neighborhood of three pints. The urine does not begin to escape from the catheter at once; sometimes it is three or four minutes before beginning. Time must be allowed for it to fill the lumen of the catheter before it begins to run out, and the urine in the catheter must be added to that collected.

The catheter is kept from collecting fluid from the bladder during its introduction into the ureter by coating the metal plug which stops the end with a little vaseline, thus rendering it air-tight. As soon as it is in the ureter the plug is withdrawn.

The urine flows by gushes at intervals of ten or fifteen or thirty seconds. It is evident from this that the urine collects in the pelvis of the kidney, passes into the ureter, and is forced down by a peristaltic wave more or less rhythmic in character. It would appear to inspection like a little bolus being swallowed. It is thus forced into the bladder in intermittent jets, as observed in the margins of vesico-

vaginal fistula. By this examination I have found one kidney secreting no urine in a case now in my ward, while the other is doing all the work.

Here is a metal case containing the necessary instruments for ureteral investigation, two catheters, for simultaneous catheterization of both ureters, bougies, and two graduates marked in minims and cubic centimetres, serving to collect the urine in separate vessels and affording the means of estimating immediately the quantity secreted in twenty-four hours.

I do not present here in this number of the ANNALS that portion of my paper entitled "Ureterectomy," or extirpation of the ureter, as I have not yet secured satisfactory pictures of the steps of the operation, and wish also to be able to give a full report of the pathological condition of the kidney and ureter removed.

DESCRIPTION OF FIGURES.

FIG. 1.—The large central bilobed tumor is the myoma uteri. Above, at the angles, are the enlarged kidneys. The intimate attachments of the lower portion of the ureters to the tumor are well shown. The right ureter appears sacculated just above its attachment, the left is enlarged throughout almost its whole extent. For complete autopsy, see Johns Hopkins Hospital Report in Gynecology, No. 1, Article III, Balt., Sept., 1890.

FIG. 2.—Enormous "fibro-cystic" (cystomyoma) tumor of the uterus in a mulatto. The patient had hydro- and pyelo-nephrosis before the operation. At the operation enucleating the mass the left ureter was tied. For full autopsy see Johns Hopkins Hospital Report in Gynecology, No. 2, *in print*.

FIG. 3.—Dissection of a negress by the writer, showing the topographical relations of the abdominal portion of the ureters. The abdominal walls are turned back by a crucial incision, and the intestines lifted out. The left kidney in this, as in each of three cases dissected, lay lower than the right.

The ureters, U, U, U, can easily be traced

from the pelvis of each kidney coming forward over and crossing obliquely the psoas muscle, and passing over the common iliac arteries immediately above the bifurcation, to enter the pelvis close to the inner side of the internal iliac artery. The ovarian veins [V] and arteries [A] are seen crossing in front of the ureters on the psoas. The entrance of the left vein into the left renal is especially well shown.

FIG. 4.—The position at which the ureters are to be located on the pelvic brim. The sigmoid flexures, SS, with the lax meso-sigmoid, is pulled over to the right, and the following structures are evident, though faintly outlined, through the peritonæum, at the pelvic brim on the left.

Ps. is the psoas muscle, Ar the external iliac artery, and Ur. the ureter, and Ov v the ovarian vessels crossing the brim into the pelvis, Ov is the left ovary, and U the uterus, R the rectum, and B. the bladder.

FIG. 5.—The right ureter, U, is here exposed by an incision in the peritonæum at the brim of the pelvis. Here the sigmoid flexure is held well over to the left, while the caput coli is drawn to the right. P locates the promontory of the sacrum.

FIG. 6.—The right ureter shown in Fig. 5, brought forward from the cellular tissue on a needle, showing its position and relation more distinctly.

FIG. 7.—A sketch from nature of the relations of the ureters to the vessels at the pelvic brim.

FIG. 8.—The right half of the pelvis. In this case drawn from nature the ovarian vessels were simply picked up above the brim of the pelvis as if for ligation. The ureter was found grasped with the vessels, showing the danger of ligating the ureter in this position.

O. v, ovarian vessels.

Ur, ureter.

P, sacral promontory.

T, Fallopian tube.

O, ovary.

U, uterus.

S, symphysis.

FIG. 9.—The left ureter is exposed by drawing the sigmoid flexure *to the right*, and incising the peritonæum over the common iliac artery just above the bifurcation.

FIG. 10.—The meso-sigmoid is here drawn to the left, showing the impossibility of exposing the left ureter, which is covered by it in this position, without cutting the sigmoid vessels.

FIG. 11.—Diagram made directly from subject, looking into pelvis from below, to show the relations of the left ureter to the iliac vessels, ovarian vessels and uterine artery.

FIG. 12.—Same subject as Fig. 11, looking into pelvis from side showing same relations.

FIG. 13.—Same subject as Figs. 11 and 12, looking into pelvis from above.

FIG. 14.—The landmarks for locating the ureters at the brim of the pelvis through the skin. Straight line indicates the promontory of the sacrum. X X the position of the ureters.

FIG. 15.—The course of the ureters indicated on the skin of the abdomen. The abdomen has been opened and the line of the ureters projected on the skin by direct examination and measurement. The abdomen is then held closed by the hand above, while the subject is photographed. The left kidney is lower than the right.

FIG. 16.—Catheterization of the left ureter. Some thirty minims of urine has been collected in the minim glass. The time during which the urine is flowing is carefully noted.

FIG. 17.—Both ureters catheterized simultaneously.

FIG. 18.—Ureteral catheters.

FIG. 19.—Case containing ureteral instruments. Two catheters and two bougies for dilating strictures, as well as two glasses measuring minims and cubic centimeters.