BULLETIN

OF

THE JOHNS HOPKINS HOSPITAL.

Vol. XII.—No. 118.] BALTIMORE, JANUARY, 1901. [Price, 15 Cents.

CONTENTS.

THE REMOVAL OF PELVIC INFLAMMATORY MASSES BY THE ABDOMEN AFTER BISECTION OF THE UTERUS.[1]

BY HOWARD A. KELLY, M. D.

I pointed out but recently (JOHNS HOPKINS HOSPITAL BULLETIN, 1900, XI, p. 56, and *Amer. Jour. Obst.*, 1900, XLII, August) the great advantages which accrue from the bisection of the myomatous uterus in an abdominal enucleation in certain complicated cases. I now desire to call your attention to the great value of a somewhat similar procedure in certain cases of pelvic inflammatory diseases.

In most instances of pelvic infections, the ovaries are innocently, only accidently, involved in the inflammatory process, and as a rule one or both of them can be saved even though it is found necessary to sacrifice both uterine tubes. If one ovary is saved, the uterus must also be saved if possible, as by doing this we conserve the function of menstruation as well as that of internal secretion of the ovary.

Where the ovaries are seriously involved in the disease, where they are converted into abscess sacs or into large hematomata, or where they are so densely and intimately matted in with the inflamed tubes that it is useless to attempt to save them, the removal of all the diseased organs together with the uterus is demanded whenever it is possible in this way: by freeing the tube and the ovary on the least adherent side first, and then after tying off the broad ligament and pushing down the bladder, and securing the uterine artery, the most difficult side is easily reached and enucleated, by cutting across the cervix and exposing the opposite uterine vessels and ligating them. The uterus is then pulled up until the round ligament is caught and divided.

[1] An address delivered before The Southern Surg. & Gyn. Assoc., Atlanta, Ga., November 13, 1900.

At this point the operation may follow one of two courses according to the difficulties encountered: in the first place, if, after dividing the uterus and pulling it up, the remaining tube and ovary can be readily enucleated by peeling them out from below upwards by working with the fingers in the lower and anterior part of the pelvis, then the enucleation may be concluded by removing all the structures in one mass. In the second place, if the tube and ovary on the far side are densely adherent and offer any serious difficulties in the enucleation, then I would clamp off the uterus at its cornu and remove it with one tube and ovary, and so leave the more difficult side to be dissected out after emptying the pelvis, securing all the advantages of increased space and light (v. Figs. 1 and 2). I have previously described this method as that of enucleation by a continuous transverse incision from left to right or from right to left.

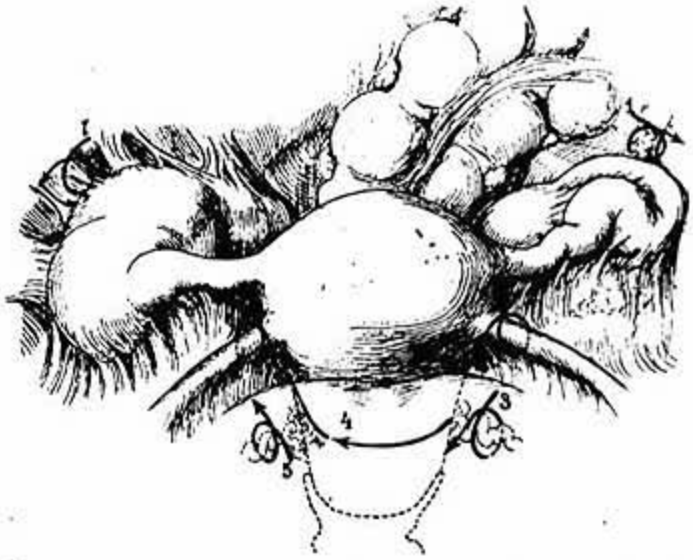

Fig. 1 shows the method of removing the uterus, in a case of pelvic inflammatory disease, by a continuous transverse incision beginning on the left side.

1 controls the left ovarian vessels.

2 controls the left round ligament; the next step is to free the vesical peritoneum from the uterus and to push the bladder down; this exposes the left uterine vessels which are now controlled by 3.

4 represents the division of the cervix exposing the right uterine vessels controlled by 5.

The division of the cervix is not directly across, a sliver or a snipe (4 to 6), is left in order to clamp the uterine vessels at a higher point.

6 is the ligature on the right round ligament and 7 that on the right ovarian vessels.

It is now my desire to describe a method of enucleation through an abdominal incision which is applicable to a class of cases still more difficult than those just referred to. Let us suppose, for example, a case in which there are *pelvic abscesses on both sides densely adherent to all the surrounding structures*, including the uterus; we will also suppose that the uterus itself is almost or quite buried in a mass of adhesions. In such a case the plan I have just described is scarcely applicable, inasmuch as there is no easier side on which to begin to start the enucleation, for both sides present extreme difficulties.

The method of a continuous transverse incision does actually give us, it is true, a great advantage over the older method of tying down on both sides, for the simple reason that the enucleation of the farther side, wherever we begin, is always easier, even though the difficulties of the first side are just the same by either method.

If, now, I could devise any method by which the enucleation of *both tubes* and *ovaries* in such a case could be effected in a direction from below upwards, it is manifest that a great advantage would be gained.

The vaginal hysterectomists have thus far had a decided advantage over those of us who prefer to operate above the symphysis, in the greater facility with which the adherent structures can be detached when they are attacked in the direction from the pelvic floor upwards. In the method I am now about to describe, this decided advantage is secured

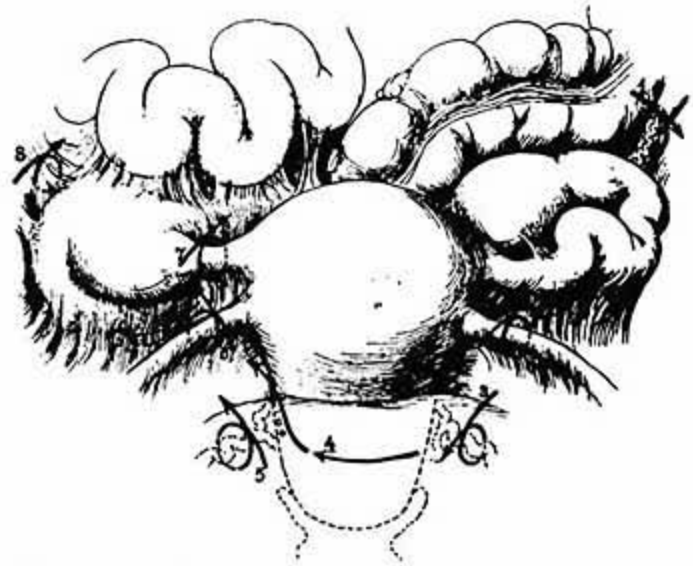

Fig. 2 shows an important modification of the method of enucleation described and shown in Fig. 1. When one side is densely adherent, it is best then to begin the enucleation with the opposite side in the order already described, and then after tying the round ligament at 6.

The next step then is to clamp the cornu uteri and remove the uterus with the tube and ovary of the side on which the enucleation was started.

The final step in the enucleation now is to remove the densely adherent side with forceps and scissors with all the advantages of abundant room and light afforded by the removal of the uterus.

for, and combined with the other great advantages of the abdominal route, that of increased room, and increased facilities of handling, abundant illumination, as well as the detection of various complicating conditions.

The steps are these: If the uterus is buried out of view, the bladder is first separated from the rectum and the fundus uteri found; then, if there are any large abscesses, adherent cysts, or hematomata, they are evacuated by aspiration or by puncture; the rest of the abdominal cavity is then well packed off from the pelvis.

The right and left cornua uteri are each seized by a pair of stout museau forceps and lifted up, the uterus is now incised in the median line in an antero-posterior direction,

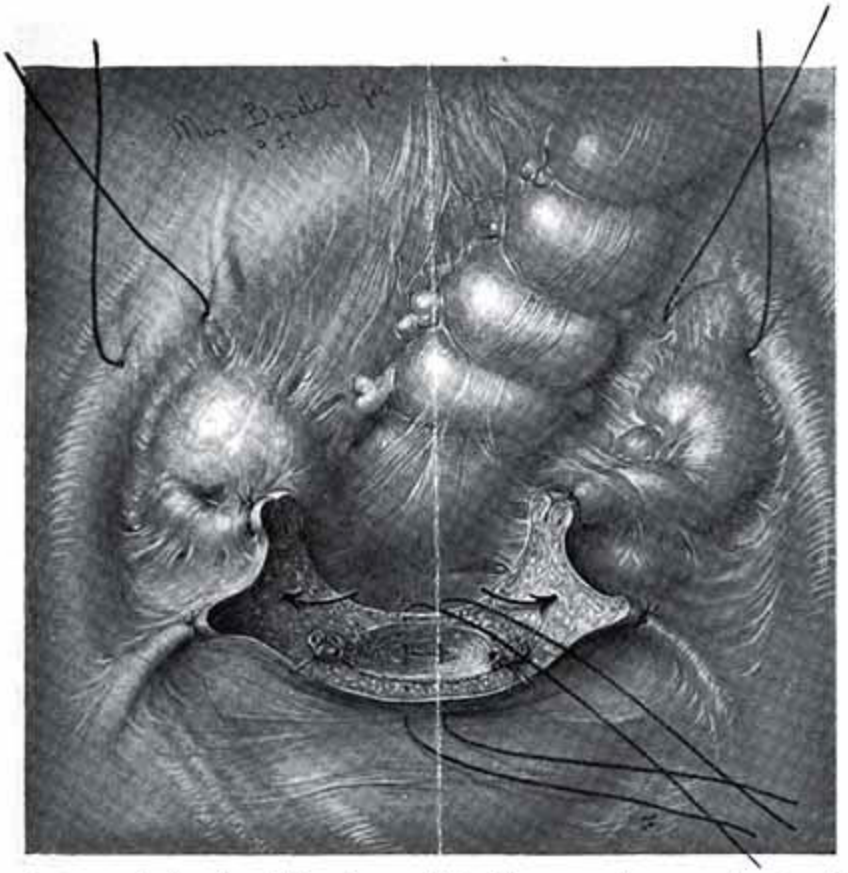

FIG. 3 shows the advantages of a bisection of the uterus enabling the surgeon to remove the uterus before removing either tube and ovary, thus affording all the conveniences of more room, abundant illumination and new avenues of approach indicated by the arrows.

Ligatures may be placed on the ovarian vessels as shown before enucleating the uterine tubes and the ovaries, when the vessels are accessible.

FIG. 4 shows the first step in the bisection of an adherent retroflexed uterus. The forceps catch the anterior face which is opened, then the bladder is pushed down and the cervix divided from side to side as indicated by the arrows.

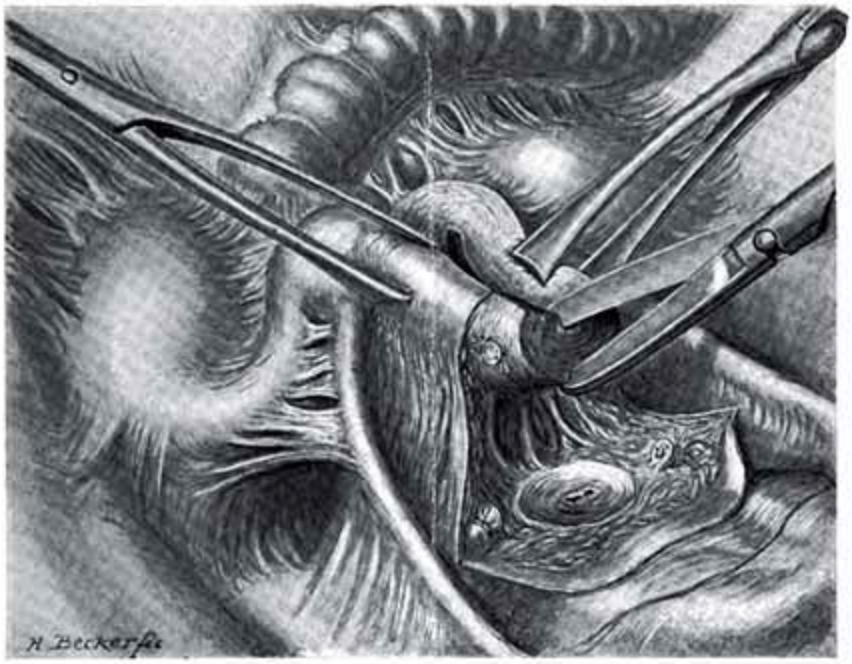

FIG. 5.—After freeing the cervix from its vaginal end it is held up and the bisection completed as shown here, in a direction from below up.

FIG. 6 shows the bisection completed. Each half of the uterus is now removed by applying ligatures as indicated by the arrows on the round ligaments and the uterine cornua. The lateral inflammatory masses are removed last of all.

and as the uterus is bisected, its cornua are pulled up and drawn apart. With a third pair of forceps the uterus is grasped on one side on its cut surface, as far down in the angle as possible, including both anterior and posterior walls. The museau forceps of the same side is then released and used for grasping the corresponding point on the opposite cut surface, when the remaining museau forceps is removed. In this way two forceps are in constant use at the lowest point. I commonly apply them three or four times in all. As the uterus is pulled up the halves become everted and it is bisected further down into the cervix; if the operator prefers to do a pan-hysterectomy, the bisection is carried all the way down into the vagina. The uterine canal must be followed in the bisection, if necessary using a grooved director to keep it in view. The museau forceps are now made to grasp the uterus well down in the cervical portion, if it is to be a supra-vaginal amputation, and the cervix is divided on one side. As soon as it is severed and the uterine and vaginal ends begin to pull apart, the under surface of the uterine end is caught with a pair of forceps and pulled up and the uterine vessels, which can now be plainly seen, are clamped or tied. As the uterus is pulled still further up, the round ligament is exposed and clamped, then finally a clamp is applied between the cornu of the bisected uterus and the tubo-ovarian mass, and one-half of the uterus is removed. The opposite half of the uterus is also taken away in the same manner.

The pelvis now contains nothing but rectum and bladder, with right and left tubo-ovarian masses plastered to the sides of the pelvis and the broad ligaments, affording abundant room for investigation of their attachments, as well as for deliberate and skillful dissection; the wide exposure of the cellular area over the inferior median and anterior surfaces of the masses, offers the best possible avenue for beginning their detachment and enucleation.

The operator will sometimes find on completing the bisection of the uterus that he can just as well take out each tube and ovary together with its corresponding half of the uterus, reserving for the still more difficult cases, or for a most difficult side, the separate enucleation of the tube and ovary after removal of the uterus.

The operation which I have just described is not recommended to a beginner in surgery; the surgeon who undertakes it must be calm and deliberate, and must bear in mind at each step the anatomical relations of the structures.

The most critical point is the bisection of the cervix and controlling the uterine vessels; if the cervix is slowly and cautiously severed with a steady traction on the uterus under perfect control, there is no danger of seeing the organ suddenly tearing out with rupture of the uterine vessels and frightful hemorrhage. As the divided cervix is pulled apart, the uterine vessels are beautifully exposed and easily caught, only a clumsy operator will plunge his needle or a pair of forceps deep down into the tissues and clamp a ureter. By cutting up the cervix so as to leave a snipe on each side the uterine vessels can be caught at a higher level than that of the division of the cervix.

There is no danger of injuring the bladder, which needs less attention than in any other method of hysterectomy; when the bisection reaches the vesico-uterine fold it may be continued carefully behind this fold well down into the cervix under the bladder which is then easily pushed down as the divided cervix is pulled apart. A simple and a safe way is also to incise the vesico-uterine peritoneum from side to side and push it down with a sponge on a staff and so bare the cervix.

If the uterus is densely adherent to the rectum all the way up to the fundus, a modification of this plan of operating may be followed; the anterior face of the uterus may be bisected and the cervix divided horizontally and the uterine vessels caught, then the rest of the uterus may be carefully divided up its posterior surface in a direction from the cervix towards the fundus. The relations to the rectum are examined as the division is made, and at any point where it seems necessary, a piece of the uterine tissue may be left adherent to the bowel. After the bisection the rest of the enucleation is effected as described above.

I have had abundant opportunity to demonstrate the practical value of this method of treatment in my clinic this year.

In one case (Ward H, 12 April, 1900) the uterus, *tubes and ovaries were so densely adherent* that an effort to free them by the vaginal route failed when I opened the abdomen and caught the uterus by its cornua and bisected it half way down the cervix, and then removed each half uterine body, then with a maximum space under sight and touch the tubes and ovaries were dissected out.

In another instance (W., 5 May, 1900) the entire uterus was bisected and removed and after its removal a large pelvic abscess was extirpated on the right side.

In a case operated upon 7 Nov., 1900 (W., H) the sigmoid on the left and the rectum on the right were the seat of *fistulous openings into the uterine tubes.* Here the fistulæ and other complications did not have to be treated until the uterus was divided and brought out into the surface.

Another patient in my private hospital had *tubercular disease of both tubes* (S., April, 1900), which was extirpated with bisection of the uterus.

In one instance (B., 17 Oct., 1900) there were extensive *hematomata of both ovaries* with dense adhesions and a most difficult enucleation was rendered safe by bisection.

In a case of a large *cancerous right ovary* (B., 19 May, 1900), extending into the pelvic cellular tissue, I found a bisection most helpful in clearing out the pelvis and exposing the disease on its median and under sides, and so making possible a much completer enucleation.

The dangers of the method are those of any novel procedure, and must arise for the most part from want of due attention to the details; for example, one can by reckless cutting divide the uterus obliquely so as to cut directly into the broad ligament among the uterine vessels instead of following the uterine canal and making a true coronal section. Again, rashly cutting, one can divide one-half of the cervix and divide the uterine vessels at the same time with frightful hemorrhage; by clamping the bleeding uterine

vessels in an indiscriminate fashion the ureter may be easily included in the clamp.

I suppose, too, that it is easily possible with sufficient carelessness to cut a hole in the bladder.

The risk of sepsis from opening the uterine cavity is practically nil if gauze is packed in around the uterus; furthermore the study of many of these uteri has shown that the infection rarely ever lingers in its cavity.

The advantages of a bisection and enucleation of the uterus as a preliminary to a complete enucleation of uterine tubes and ovaries for pelvic inflammatory and other diseases by the abdominal route are briefly recapitulated:

1. Additional space for handling adherent adnexæ, afforded by the removal of the uterus.

2. Great increase in facility for dealing with intestinal complications.

3. Better access by new avenues from below and in front to adherent lateral structures.

4. Elevation of structures to or above pelvic brim or even out into the abdomen, bringing them within easy reach of manipulation and dissection.

5. The same advantage in approaching both uterine vessels by cutting from cervix out towards the broad ligaments as is secured in approaching one of them in the continuous transverse incision method.

In general, the time of the operation is shortened; its steps are conducted with greater precision; surrounding structures are far less liable to be injured. In this way there are fewer troubles and sequelæ and the mortality is lessened.

I take it that in intraligamentary tumors of both sides this procedure will prove of the utmost advantage in exposing the tumors at a point low down in the loose cellular tissue of the broad ligament.

I have found since writing this that a similar plan of operating has been advocated by J. L. Faure of Paris.