

# GYNÆCOLOGICAL DIAGNOSIS

A Manual for Students and Practitioners

BY

*e*  
ARTHUR E. GILES

M.D., B.Sc. LOND.; F.R.C.S. ED.; M.R.C.P. LOND.  
GYNÆCOLOGIST TO THE TOTTENHAM HOSPITAL; SURGEON TO OUT-PATIENTS,  
CHELSEA HOSPITAL FOR WOMEN

*WITH THIRTY-FIVE ORIGINAL ILLUSTRATIONS*

NEW YORK  
WILLIAM WOOD & COMPANY  
MDCCCXVI

## PREFACE

THE importance of diagnosis in gynæcology, my hope that this book may help the practitioners therein, and the reasons for adopting the plan of working from symptoms to diseases, are duly set forth in the introductory chapter. It only remains for me to say a word about the scope of the book. Diagnosis is carried only up to the point to which the practitioner may be expected to go. There are various conditions in which microscopic examination is necessary for the scientific completion of diagnosis, but this final step is open to few besides pathological experts, and I have therefore omitted it.

Eliminating microscopic appearances, gynæcological diagnosis does not lend itself to extensive pictorial illustration. For the few drawings and diagrams that I have employed I am myself responsible.

ARTHUR E. GILES.

10, UPPER WIMPOLE STREET, W.

*February, 1906.*

# CONTENTS

## PART I

### GENERAL CONSIDERATIONS

CHAPTER	PAGE
I. INTRODUCTION - - - - -	3
II. METHOD OF CASE-TAKING - - - - -	6
III. METHOD OF EXAMINATION - - - - -	16
IV. THE USE OF INSTRUMENTS FOR DIAGNOSIS - - - - -	31
V. THE SIGNIFICANCE OF SYMPTOMS - - - - -	38
VI. THE INTERPRETATION OF PHYSICAL SIGNS - - - - -	56
VII. THE INTERPRETATION OF PHYSICAL SIGNS ( <i>continued</i> )-	70

## PART II

### DIAGNOSIS OF INDIVIDUAL CASES

VIII. LEADING SYMPTOM : AMENORRHOEA - - - - -	91
IX. LEADING SYMPTOM : PAIN - - - - -	100
X. LEADING SYMPTOM : HÆMORRHAGE - - - - -	118
XI. LEADING SYMPTOM : DISCHARGE - - - - -	135
XII. LEADING SYMPTOM : PRURITUS - - - - -	142
XIII. LEADING SYMPTOM : DYSPAREUNIA - - - - -	146
XIV. LEADING SYMPTOM : STERILITY - - - - -	152
XV. LEADING SYMPTOM : REPEATED ABORTIONS - - - - -	158
XVI. LEADING SYMPTOM : BEARING DOWN - - - - -	162
XVII. LEADING SYMPTOM : BOWEL OR BLADDER DISTURBANCE	169
XVIII. LEADING SYMPTOM : SWELLING OF THE VULVA - - - - -	179
XIX. LEADING SYMPTOM : SWELLING OF THE ABDOMEN - - - - -	187
XX. CONCLUSION - - - - -	205
INDEX - - - - -	208


## LIST OF ILLUSTRATIONS

FIG.	PAGE
1. BIMANUAL PALPATION OF THE NORMAL UTERUS - - - -	26
2. BIMANUAL PALPATION BEHIND THE UTERUS - - - -	27
3. BIMANUAL PALPATION IN FRONT OF THE UTERUS - - - -	28
4. BIMANUAL PALPATION OF THE BROAD LIGAMENT AND FALLOPIAN TUBE - - - - -	29
5. DIAGRAM TO ILLUSTRATE THE METHOD OF PASSING THE SOUND INTO A NORMAL UTERUS - - - -	35
6. METHOD OF PASSING THE SOUND INTO A RETROVERTED UTERUS - - - - -	36
7. RESPIRATORY MOVEMENT OF THE ABDOMEN IN THE ABSENCE OF A TUMOUR - - - - -	58
8. RESPIRATORY MOVEMENT OF THE ABDOMEN IN THE PRESENCE OF A TUMOUR - - - - -	58
9. DIAGRAM TO ILLUSTRATE THE POSITION OF ABDOMINAL SWELLINGS - - - - -	59
10. DIAGRAM TO ILLUSTRATE THE POSITION OF ABDOMINAL SWELLINGS - - - - -	60
11. HYPERPLASIA OF THE VAGINAL PORTION OF THE CERVIX -	66
12. HYPERPLASIA OF THE SUPRAVAGINAL PORTION OF THE CERVIX - - - - -	66
13. PROLAPSE OF THE UTERUS - - - - -	66
14. TWO POSITIONS OF THE FUNDUS WHEN THE CERVIX POINTS BACKWARDS - - - - -	68
15. TWO POSITIONS OF THE FUNDUS WHEN THE CERVIX POINTS FORWARDS - - - - -	68
16. RUDIMENTARY UTERUS - - - - -	73
17. INFANTILE UTERUS - - - - -	73

## List of Illustrations

FIG.		PAGE
18.	UTERUS UNICORNIS - - - - -	74
19.	UTERUS SEPTUS UNICOLLIS - - - - -	74
20.	UTERUS SEPTUS - - - - -	75
21.	UTERUS BICORNIS UNICOLLIS - - - - -	75
22.	UTERUS BICORNIS - - - - -	76
23.	UTERUS DIDELPHYS - - - - -	76
24.	THE NORMAL NULLIPAROUS CERVIX - - - - -	82
25.	THE NORMAL PAROUS CERVIX - - - - -	82
26.	CONICAL CERVIX WITH PINHOLE OS - - - - -	83
27.	BILATERAL LACERATION OF THE CERVIX - - - - -	83
28.	UNILATERAL LACERATION OF THE CERVIX WITH 'EROSION' - - - - -	84
29.	CERVIX-ADENOMA ('GRANULAR EROSION') - - - - -	84
30.	CERVIX-ADENOMA ('FOLLICULAR EROSION') - - - - -	85
31.	BILATERAL LACERATION OF THE CERVIX WITH EVERSION AND ADENOMA - - - - -	85
32.	MUCOUS POLYPUS OF THE CERVIX - - - - -	86
33.	FIBROID POLYPUS OF THE CERVIX - - - - -	86
34.	CARCINOMA OF THE CERVIX - - - - -	87
35.	DOUBLE CERVIX - - - - -	87

**PART I**  
**GENERAL CONSIDERATIONS**



## CHAPTER I

### INTRODUCTION

THE expert diagnostician makes the most successful practitioner in any department of medicine and surgery ; because when a case is beset with difficulties, these are nearly always due to the fact that the nature of the case is not clear. Once the diagnosis is established, the question of treatment is relatively easy ; if still in doubt, one can refer to a treatise, look up the condition diagnosed, and find the appropriate treatment adequately set forth.

But when the diagnosis is not clear, treatment is haphazard, and a matter of guesswork ; one plan is tried, and then another, till the patient and the friends come to that most damaging conclusion—that the medical attendant ‘ does not understand the case.’ Such a conclusion strikes at the very root of, and undermines, the confidence in the medical attendant on which successful practice ultimately depends. It is true that by a frank admission of the difficulties and doubts of the case confidence may yet be maintained or restored : but, on the other hand, any attempt to conceal his doubts and gloss over his difficulties may lead the attendant into further trouble, till the patient calls in his nearest rival, or, without his knowledge, seeks the advice of the ‘ specialist.’ The outcome is that relations are strained, or the doctor loses his patient.

Probably few practitioners have escaped these difficulties and worries, even though they may be exceptionally frank or richly endowed with tact.

What is true of medicine in general applies, perhaps, with even greater force to the department of gynæcology; because gynæcological conditions are such that the patient is necessarily unable to have any cognizance of the actual disease or disorder, except in the matter of symptoms; if the doctor decides that there is a tumour, a displacement, or an 'internal inflammation,' the patient has no means of judging whether the diagnosis is right or wrong, and in her attitude towards her physician, must 'trust him all in all or not at all.'

Gynæcological diagnosis possesses some inherent difficulties. In the first place, it is impossible that a practical knowledge of the female organs can be acquired by all students. A surgical or medical case can generally be examined by ten or twenty students without detriment; whilst not more than two or three can make a gynæcological examination in a particular case. And yet it is impossible to become familiar with pelvic conditions unless the fingers are trained by repeated examinations. In the second place, a knowledge of diseased conditions cannot be solidly obtained until the student is fairly familiar with the normal pelvic organs. For some it is possible to supplement the teaching acquired in student days by a course of training at a special women's hospital; but many must wait until they get into practice, and the opportunities they want only come when they require to be already equipped with practical knowledge. They must, therefore, perforce acquire knowledge by practice, instead of applying their knowledge to their practice. This is, of course, the more arduous way.

It has, therefore, seemed to me that a manual which



should facilitate the diagnosis of the diseases of women would need no apology for its appearance. Whether or not the present effort will fulfil that object must be left to the test of time and experience, and in the meantime I shall reserve the apology.

I have aimed at presenting the subject of diagnosis from a different standpoint from that usually adopted in books on the Diseases of Women. The characteristic feature of text-book descriptions is this: Given a disease or disorder, what are its symptoms? I propose to proceed in the inverse order, and to ask: Given certain symptoms, what disorder or disease may we expect to find? The first plan is necessary for the purposes of a text-book, which aims at systematic description; the second is of special value from the practical standpoint of the practitioner, because it is, after all, the plan which he must adopt when the responsibility of the diagnosis and treatment of an actual case is placed upon him.

This plan necessarily involves a certain amount of repetition, because starting from different prominent symptoms the same diagnosis may be arrived at. But I have preferred the repetition to the only alternative of constant cross-references, which are apt to prove irritating to the reader.

In this First Part we shall discuss general considerations, such as case-taking and the method of examination, the use of instruments for diagnosis, the general significance of gynæcological symptoms and interpretation of physical signs. This will leave us free, in Part II., to investigate individual cases without digressing to consider why certain symptoms are important, how the presence of certain physical signs can be determined, or what the conditions found on examination may represent.

## CHAPTER II

### METHOD OF CASE-TAKING

IN some departments of medicine and surgery the objective examination of the patient gives nearly all the information that is needed in order to arrive at a correct diagnosis ; in others, the knowledge derived from an examination of physical signs must be supplemented by information on various points contained in the statements of the patient. The statements of the patient constitute the ' Anamnesis.' Gynæcological diagnosis is essentially of the type that demands the combination of anamnesis or symptomatology, and objective examination. The reason of this is that similar symptoms may be present in divers diseases ; and that various morbid conditions may present much the same characteristics when felt in the course of an examination. For example, a patient who complains of backache, bearing-down, menorrhagia, and leucorrhœa, may be suffering from a retroversion, a prolapse, an endometritis, or a subinvolution ; and, on the other hand, when a swelling is felt on one side of the uterus, it may be impossible to tell by the examination alone whether it is a diseased tube, an outlying fibroid, a small ovarian tumour, or a tubal pregnancy.

In order that both the anamnesis and the physical examination may be complete, and that no pertinent

## GYNÆCOLOGICAL NOTES.

No. ....

Series .....

Date .....

Name.....Age.....Civil State (married, single,  
or widow).

Residence and Occupation.....

Diagnosis .....

## I.—ANAMNESIS.

## Family History.

Previous Health (with special reference to gynæcological conditions, such as attacks of gonorrhœa or of pelvic inflammation, or operations for tumours).

Menstruation (including data concerning the age of the first menstruation; rhythm; duration; quantity; pelvic pain or general disturbance; recent variations in regularity, quantity, or pain; date of the last menstruation; age of the menopause).

Confinements, Miscarriages, etc. (including data concerning dyspareunia; sterility; character of labours; date of the last confinement or miscarriage; puerperal complications).

History of Present Illness (including its duration, and particulars of present symptoms, such as pain, leucorrhœa, abdominal swelling, disturbances of bladder or bowels, general health).

**II.—PRESENT CONDITION.**

**General Health and appearance.**

**Heart, Lungs, Nervous, Digestive, and Excretory Systems.**

**Abdomen and Breasts.**

**Vulva and Perineum.**

**Vagina.**

**Uterus.**

**Adnexa.**

**Bladder and Urethra, Urine.**

**Other Conditions.**

III.—TREATMENT AND AFTER-HISTORY.

TREATMENT AND AFTER-HISTORY—*continued.*

information may be lacking, a definite, systematic plan should be followed. It is convenient to have printed case-sheets embodying the principal objects of inquiry and examination on the first two pages, with a blank fly-leaf to record treatment and after-history; such a one as is here reproduced will be found useful for gynæcological cases. These sheets can be kept in a file-box in the alphabetical order of the patients' names; and by this means any given case can be referred to within half a minute, whether the patient was last seen a month, a year, or twenty years previously.

We must proceed to discuss in some detail the significance of the data obtained by the anamnesis. The value of these data is that as the investigation proceeds, the questioner makes mental notes of the bearing of each point on the probabilities of the diagnosis; practice will enable him to mentally underline such facts as are relevant to the case in hand; so that by the time he has finished his interrogation, and is ready to examine the patient, he has already some definite idea as to what he must specially look for. The following will serve as an illustration of the basis of the running comments and deductions which form the undercurrent of one's thoughts during the anamnesis.

**Age.**—Primary amenorrhœa in a girl of seventeen or under is of little import; in a young woman of eighteen or over it suggests under-development of the pelvic organs. Under the age of thirty-five a large tumour is likely to be ovarian; above that age it may well be a uterine fibroid. A patient suffering from hæmorrhage is likely to have a polypus if she is under twenty; from twenty to thirty it may be due to a polypus or to some condition resulting from gestation; from thirty to forty, it may be the result of gestation or of fibroids; from forty to fifty we shall

think of fibroids and malignant disease; above fifty, the probability is in favour of carcinoma. The effects of gonorrhœa are most often seen between the ages of twenty and thirty, though no age is exempt.

**Civil State.**—The influence of this factor on diagnosis is seen in two important matters. In the first place, the fact that the patient is single (a virgin) excludes the fairly numerous complications associated with pregnancy; and may assist in the diagnosis between pregnancy and a large ovarian or uterine tumour. In the second place, in such a case we may eliminate the conditions dependent on venereal disease. Therefore, in a single woman, we may exclude from consideration such things as sub-involution, placental polypus, lacerated cervix, extra-uterine gestation, ovarian or fibroid tumours complicated by pregnancy, gonorrhœal vaginitis and salpingitis, chancres, and condylomata. If we find diseased tubes in a virgin, we can be practically certain that they are tuberculous.

**Family History.**—This is not of great importance in gynæcology. A history of tuberculosis affecting the parents or near relations may prepare us for finding tuberculosis, peritonitis, or salpingitis in the patient. In a few instances one finds two or three sisters affected by the same conditions. I have seen sisters suffering from ovarian tumours, and have removed fibroids from three sisters, but probably such coincidences must be considered more curious than significant. Under-development does not run in families, and a patient with an infantile uterus may have well-developed sisters who are mothers. Cancer, or at least a tendency thereto, has long had the reputation of being hereditary, but it is doubtful whether heredity has as much to do with the matter as the residence of members of a family in the same district. From the point of view



of diagnosis, therefore, the family history is of minor importance.

**Previous Health.**—A knowledge of the previous health will often prove of material assistance and throw a definite light on an otherwise obscure case. For example, a history of gonorrhœa contracted early in the married life may account for a long-continued sterility or indicate that pelvic swellings are of inflammatory origin, or lead us to seek in the tubes the explanation of intractable menorrhagia. A history of a difficult labour followed by puerperal fever may lead us to correctly infer that a large swelling in the pelvis is a pelvic abscess rather than a new growth.

If the patient has been subjected to operation, an effort should always be made to ascertain its exact nature by reference to the operator or the previous medical attendant. Many patients have no idea what operation has been done, or, worse, they may have an idea, but a quite incorrect one.

**Menstruation.**—The significance of menstrual characteristics will be discussed in detail in the section on Symptomatology. Here I will only point out that the previous history of menstruation may have important bearings on the case. For instance, a late onset of puberty is often correlated to under-development; a term of two or three months' amenorrhœa, which is usually of great importance, may mean nothing in the case of a patient who habitually menstruates irregularly and at long intervals; profuse menstruation has a profound significance in a patient whose menstrual flow is usually scanty or moderate, whilst it may mean nothing in one who has always menstruated freely. Therefore, when one inquires into the character of menstruation, one should invariably ascertain whether there has been any departure from a

previous type as regards either rhythm, duration, quantity, or pain.

**Confinements, Miscarriages, etc.**—The data on these points have many bearings, of which we may give some examples. If a patient has been married many years and had no children, and if we assume for the moment that the cause of the sterility rests with her and not with her husband, we may expect to find some under-development, or if there is at the same time a history of gonorrhœa, we shall probably find some evidences of chronic endometritis or of disease of the uterine appendages. In a nullipara it is highly improbable that there will be carcinoma of the cervix, but carcinoma of the body of the uterus may occur. Either complete or relative infertility often goes with fibromyoma of the uterus. Dyspareunia dating from the time of marriage generally points to smallness of the vaginal orifice, vaginismus, or local tenderness; but if it is a later development we shall expect to find some more deep-seated condition, such as pelvic inflammation or prolapsed and diseased appendages.

Women who have borne many children are very unlikely to suffer from fibroids, but, on the other hand, they are more prone to carcinoma of the cervix. If repeated miscarriages have occurred, they may indicate syphilis, tuberculosis, endometritis, or a deeply-lacerated cervix. I may here take the opportunity of expressing my entire disbelief in any 'habit of abortion' apart from some definite organic condition. When a labour or miscarriage has occurred recently, the present condition may be related thereto. Thus menorrhagia may be due to subinvolution, or metrorrhagia to retained products of conception, or we may find a ready explanation for a torn cervix or perineum. A difficult instrumental labour followed by child-bed fever may account for pelvic cellu-

litis or a pelvic abscess ; but when seeking the explanation of pelvic inflammation in a recent delivery, we must not overlook the possibility that the disturbance of labour has lighted up a dormant infection in the vagina, uterus, or Fallopian tubes, or has led to suppurative changes in an ovarian cyst, especially a dermoid.

Lastly, a recent delivery may account for various vulvar affections, such as œdema, hæmatoma, and cellulitis.

Having given this rapid review of some of the reasons for a careful and complete anamnesis, I proceed to consider the method of examination.

## CHAPTER III

### METHOD OF EXAMINATION

IT is necessary to be as systematic in making an examination as in elucidating symptoms. It is convenient to follow the order here described.

**General Examination.**—A general survey of the system is often advisable; its minuteness will depend upon the symptoms.

It is seldom necessary in a gynæcological case to make an exhaustive investigation of the nervous system, heart, lungs, and abdominal viscera, but at the same time nothing of importance in these organs should be overlooked. The reason for this is twofold. In the first place, various general disorders may complicate pelvic disease, and may necessitate some modification in the treatment. In the second place, the symptoms may not point unequivocally to pelvic disease, and it may be necessary to be in a position to exclude other conditions.

As illustrations of these general statements, we may recall the possible complication of displacements by gastric and reflex nervous disorders, and we shall want to know how far such disorders are dependent on the displacement or due entirely to gastric disease or nervous conditions. Anæmia and amenorrhœa are often present

together, and sometimes we have to determine whether the latter is due to the former or incidental to pregnancy. Pain in the lower part of the abdomen may be due to diseased appendages, but, on the other hand, right-sided pain may be due to the appendix, the kidney, the gall-bladder, or the ureter; and left-sided pain may result from disease of kidney, ureter, or sigmoid.

Before now patients have been submitted to operation for the removal of both ovaries when a movable kidney, a stone in the ureter, or a damaged appendix, has been the offender. It is therefore of the highest importance that the gynæcologist should not view the whole body through a speculum, nor survey all abdominal troubles from the pelvic standpoint. To correctly diagnose pelvic disease he must be able in addition to diagnose non-pelvic conditions, and must not forget everything except his gynæcology.

We shall commence our examination, then, by noting any special features, such as anæmia, general development, a high temperature, wasting, or obesity. These conditions may throw an important light on gynæcological diagnosis, in the direction either of interpretation or of exclusion; and a few comments will serve as an illustration of their value. Thus, if the patient is anæmic we may have an obvious explanation of amenorrhœa, or of scanty and irregular menstruation; or, on the other hand, we may find that the anæmia is the result of frequent and excessive losses of blood. Patients will be found to differ in their estimates of losses of blood; in some, the loss may be considerable, yet they do not think of it; others may be alarmed by relatively slight losses: but the presence or absence of anæmia will enable us at least to gauge whether the hæmorrhage is greater than the recuperative power of the patient. The general develop-

ment may have an important bearing on questions of sterility, concealed or delayed menstruation, and under-development or malformation of the genital organs.

The state of the temperature often serves to distinguish between conditions in the pelvis of which the physical signs are practically identical; and more particularly between inflammatory disease of the appendages, pyosalpinx, and pelvic abscess on the one hand, and pelvic tumours on the other. As we shall see, there are exceptions in both directions; for inflammatory conditions of the appendages, in the chronic stage, may be unaccompanied by any rise of temperature; whilst a high temperature may be present in the case of an ovarian tumour associated with peritonitis, a fibroid undergoing septic changes, or a breaking-down hæmatocele resulting from a ruptured tubal pregnancy. Wasting is often a sign of late carcinoma or tuberculosis of the genital organs; but it may be the result of simple neurasthenia. Obesity has not necessarily any diagnostic significance; but it is an interesting point that it often accompanies deficient ovarian activity, and so is found in cases of sterility due to under-development, and in patients at the climacteric. Patients with fibroids who are anæmic from losses of blood are often very fat; but those with large ovarian tumours are nearly always thin.

**Abdominal Examination.**—To carry this out satisfactorily the patient should be either in bed, or undressed on a couch. In the latter case, corsets and combinations should be removed, so that the abdomen can be freely examined by sight and touch. The general appearance of the abdomen should be noted, as regards contour, distension, the amount of fat, scars of former operations, and striæ of pregnancy. At the same time the condition of the breasts can be observed when this is necessary.

In palpating the abdomen we want to know whether there is any unusual swelling, and, if so, what it is. In the first place, the two hands should be placed on the lower part of the abdomen, one each side, and gently pressed inwards to discover whether any tumour occupies the pelvic brim; if anything is discovered, it may be possible to determine whether it arises in the pelvis or is of abdominal origin: other points to be noted are its situation (median or lateral), size, consistence, shape, and mobility. If no swelling be found, the abdomen should be palpated all over to discover the situation of any pain or tenderness. It is often advisable to determine whether there is any enlargement of liver or spleen, or undue mobility of the kidneys. The interpretation of signs found in the abdomen will be discussed later on.

**Vaginal Examination.**—Here we are first met with the question, ‘What is the best position in which to make a vaginal examination?’ We have five positions from which to choose: (1) The lateral, with its modification, the semiprone or Sims’s position: (2) the dorsal; (3) the gynæcological; (4) the knee-elbow; (5) the lithotomy position. The last two we can quickly dispose of.

**The Knee-elbow, or Genupectoral Position.**—The patient supports herself on knees and elbows, the chest lightly resting on a pillow; the thighs must be vertical. This position is never used for an ordinary examination; its use is limited to certain cases of backward displacement, where the assistance of gravity is sought for the replacing of the uterus. A gynæcologist who sees a very large number of cases may have occasion to employ this position once in a year or two.

**The Lithotomy Position.**—The patient lies on her back, the buttocks coming up to the end of the couch or table, the thighs flexed on the abdomen, and held in

position either with a Clover's crutch or with bands passed round the knees and attached to upright bars fixed at the sides of the table. This position is absolutely the best for making an examination, and for carrying out treatment, operative or otherwise; but it is only used when the patient is under an anæsthetic. We can, therefore, dismiss it from further consideration.

**The Lateral Position.**—The patient lies on her side, with the knees drawn well up, the buttocks projecting over the edge of the bed, and the head pointing towards the opposite side of the bed. Custom has decreed that the patient lies on her left side; but this is merely because the right hand is the more frequently used for making an examination.

Now, there are four objects to be considered in an examination: inspection of the vulva, digital examination of the vagina, bimanual examination of the uterus and adnexa, and manipulations with instruments, for diagnosis and for minor treatment. The lateral position is suitable for inspection, and quite satisfactory for digital vaginal examination; but it is not very good for bimanual examination, because the organs are not felt in their normal position, and the hands are cramped; and manipulations are difficult and unsatisfactory.

In the *semiprone position* the patient lies on her left side with the knees drawn up, the right knee in front of the left, the upper part of the body turned so that the front of the chest rests on the bed, while the left arm is extended behind her, or hangs over the edge of the bed. Manipulations with instruments are easier than in the lateral position; inspection and digital examination are equally easy in both positions; but bimanual examination is almost impracticable in the semiprone. Indeed, this variation in the lateral position was introduced by Sims



almost solely to facilitate instrumental manipulation with the patient lying on her side.

**The Dorsal Position.**—The patient lies on her back, in bed or on the couch, with knees drawn up and separated. If the medical attendant is going to use his right hand, he sits or kneels on the right side of the patient, who lies as near to the right edge of the bed as possible. The examining hand passes under the patient's right knee; the left hand is free to palpate the abdomen. In this position inspection and instrumental manipulation are impossible, but digital and bimanual examinations can be carried out quite well.

**The Gynæcological Position.**—In this case the patient lies on her back with the buttocks brought to the end of the couch, the feet supported on some kind of foot-rests, and the knees separated. The medical attendant stands opposite the perineum. I have called this the 'gynæcological' position because it is the position *par excellence* for an examination. It is the best for each purpose—inspection, digital and bimanual examination, and instrumental manipulation—and it has the advantage that the whole process can be carried out with the patient in one position. I am convinced that in many cases of incorrect diagnosis an examination in the lateral position has been partly responsible, and that an examination in the gynæcological position would have led to a more correct understanding of the pelvic conditions.

The only possible objection to this position is that it may offend the patient's sense of delicacy; but I am convinced that this objection is unfounded. The truth is that it is the fact of an examination, and not its method, that is repugnant to the patient; and once she has made up her mind as to the necessity for an examination, its method is a matter of relative indifference, as long as

## Gynæcological Diagnosis

it is conducted in a delicate and professional manner. Speaking generally, patients have become more educated in medical matters, and most of them are likely to be much more offended by an incorrect diagnosis than by the position in which they are placed for examination.

I have no hesitation, therefore, in answering the question at the head of this section by saying that the gynæcological position is the best in which to make an examination. It is obvious, of course, that the gynæcological position is not always practicable; it is chiefly suitable for consulting-room work when one can have a couch adapted to the purpose. When a patient is examined at home—that is, generally, in bed—the best plan is to begin with the dorsal position: after the vaginal and bimanual examination has been completed, the patient is turned on her side if there should be any necessity either for inspection or for the use of instruments.

We may now consider the procedure to be adopted in making an examination, and for this purpose I shall suppose that the patient is in the gynæcological position. We begin with inspection, when this is indicated—namely, if the patient complains of any sore place, irritation, or swelling in the vulva; of bearing-down; of abundant discharge; or of painful micturition. We may find in this way that she has venereal sores, a Bartholinian cyst, a tumour of the vulva, a varicocele in the labium majus, a cystocele, rectocele, or prolapse of the uterus associated with a ruptured perineum; a gonorrhœal or simple vulvovaginitis, kraurosis vulvæ, or a urethral caruncle. In the rare condition of double vagina, two vaginal orifices will be seen side by side.

It is obviously important that a digital examination should not be made without preliminary inspection when there is reason to suspect venereal disease, for such a

course has led to inoculation of the fingers from a chancre or from sepsis. If the complaint is of 'falling of the womb,' the patient can be requested to strain, or 'bear down,' when the degree of protrusion of vaginal walls or uterus can be noted.

The digital examination is now proceeded with. Beginning with the vulva, an enlargement of the gland of Bartholin, or dilatation of its duct (Bartholinian cyst) can be readily felt between the finger and thumb, even when the enlargement is too small to be easily recognised by inspection. For this purpose the finger is introduced just within the vagina, and the thumb is placed on the outer side of the labium majus. When there is a history of recent gonorrhœa, the urethra should be pressed with the finger from within outwards, when the expression of a droplet of pus will indicate a concurrent urethritis. In these cases the Bartholinian ducts are frequently infected, and with pressure one may squeeze out a drop of pus from them also; the orifice of the duct will be found reddened and unusually conspicuous: the place to look for it is the inner border of the labium minus, just external to the ring of attachment of the hymen.

The finger, well lubricated, is then passed into the vagina, and information is gleaned in an orderly and systematic manner, beginning with the vaginal orifice and finishing with the os uteri. We shall, accordingly, note first the size of the vaginal orifice, the occurrence of spasm of the sphincter formed by the levator ani (vaginismus), the smoothness, laxity, degree of moisture and heat of the vaginal walls. We may discover a growth in the vagina, or find a foreign body there, perhaps a pessary introduced years before, and since forgotten; there may be cysts in the vaginal wall, or a cicatricial contraction causing stenosis. Such a con-

traction is sometimes met with just below the level of the os externum, the vagina being thus of 'hour-glass' form ; the two parts of the vagina communicate by a circular orifice which may be so small that the finger can hardly be passed through it, and it may give the impression of being the external os ; but if the finger can be passed through, the cervix will be found lying in the upper cavity. Sometimes curious bands are found in the vagina : in some cases they are of traumatic origin ; in others they are the remnants of a developmental septum ; occasionally their presence cannot be accounted for in either way, and is very difficult to explain. A remnant of a septum is sometimes found in the form of a longitudinal ridge on either the anterior or posterior wall, or perhaps on both. We shall note whether the vaginal fornices are obliterated or made to bulge downwards by swellings outside the vagina ; and occasionally we may feel a fistulous opening, communicating with the bladder or rectum.

The cervix may now engage our attention, and its size, direction, shape, and consistency should be noted. Its surface may be smooth, or dotted with retention cysts, or velvety and irregular on account of cervix adenoma ('erosion'); we may find the os externum small and nulliparous or large, or there may be more or less laceration of the cervix, so extensive in some cases that the two lips are separate as far as the vaginal vault. In this case it is sometimes possible to feel a cicatricial band passing outwards from the base of the laceration across the vaginal vault, showing that the original tear involved the vaginal wall as well as the cervix. The cervical canal may be sufficiently patulous to admit the finger ; the dilatation is usually limited to the cervix, but occasionally the internal os also is dilated, and we may feel something in the uterus, such as part of a foetus, a placenta, or

a polypus. Some growth of the cervix may be present, such as a carcinoma, producing the typical 'cauliflower excrescence'; or a fibroid bulging the cervical wall; or a polypus projecting from the os externum. Occasionally the cervix is very difficult to find; but is discovered eventually drawn high up behind the pubes: this is usually the result of a tumour behind the uterus; or of the uterus itself being enlarged, from pregnancy or fibroids, and retroverted. Lastly, the tumour may be so large that the vagina is pressed upon, and there is hardly room for the examining finger to pass between the tumour and the pubes.

We now come to what is really the most important thing—namely, the *bimanual examination*. This is carried out by the co-operation of the two hands working intelligently together with palmar surfaces facing one another. The vaginal hand is represented by one or two fingers, and its rôle is chiefly to serve as a fixed point against which the other hand can successively press the various pelvic structures while it feels them over. At the same time the vaginal hand has a discriminating as well as a supporting function. Both functions are best served by using two fingers in the vagina; so this should be done wherever it is possible. One secret of success is to get the fingers as high up in the vagina as possible when exploring the deeper structures; so the ring and little fingers should be flexed out of the way, and the perineum pressed back in the cleft between the middle and ring fingers. As the vaginal direction is upwards as well as backwards, it is clear that the deeper the examination is carried with the vaginal hand, the higher on the abdominal wall should pressure be made with the outer hand; swellings in the pelvis are sometimes missed because the outer hand is kept too close to the pubes.

A bimanual examination should be systematic, and the

important landmark is the uterus. The position and size of the body of the uterus must be determined first ; and the four segments of the pelvis that surround the uterus are examined in their order, namely, the anterior segment, for swellings or effusion in the utero-vesical space, tumours connected with the front of the uterus, or bladder condi-

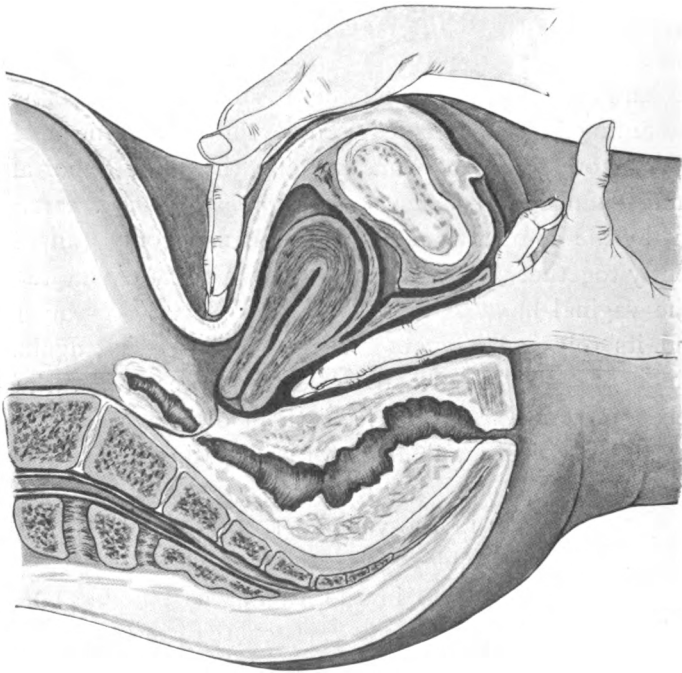


FIG. I.—BIMANUAL PALPATION OF THE NORMAL UTERUS.

tions ; the posterior segment, for swellings or effusion in the pouch of Douglas ; and the two lateral segments, for conditions involving the Fallopian tubes and ovaries, and cysts, tumours, or inflammatory swellings in the broad ligaments. It is evident that in order to understand the significance of pathological conditions in the pelvis, a

knowledge of the normal conditions is essential; so I shall briefly describe the method of examining the normal uterus and appendages, the patient being in the gynæcological position, as before.

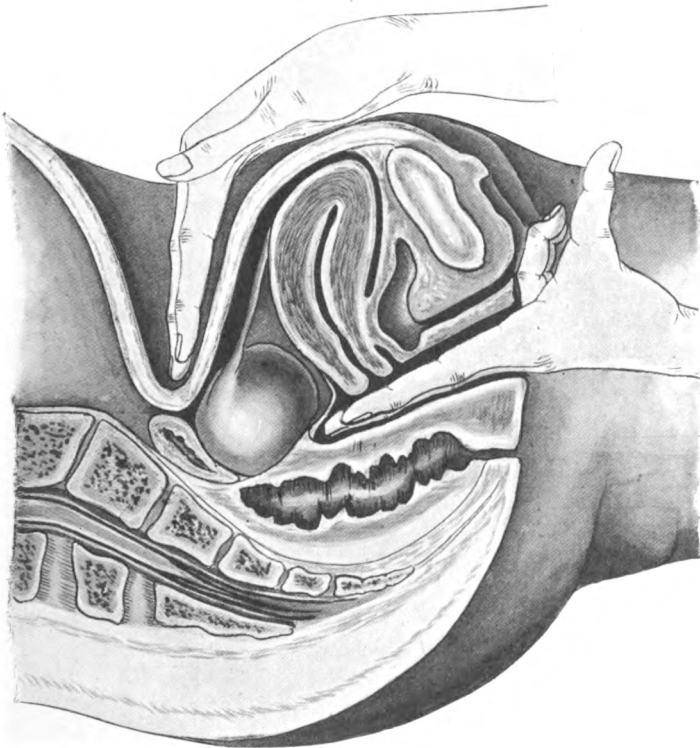


FIG. 2.—BIMANUAL PALPATION BEHIND THE UTERUS.

Two fingers of the examining hand are introduced into the vagina, pressing firmly against the perineum and posterior vaginal wall. The hand should be in a position midway between pronation and supination, until the fingers are well in the vagina, and then supinated, so that the palmar surfaces of both fingers are lying against the



anterior surface of the cervix. The outer hand now presses the fundus forwards and downwards, so that the the uterus is lying with its long axis between, and parallel to, the two hands, the cervix corresponding with the finger-tips, and the fundus pointing towards the wrists

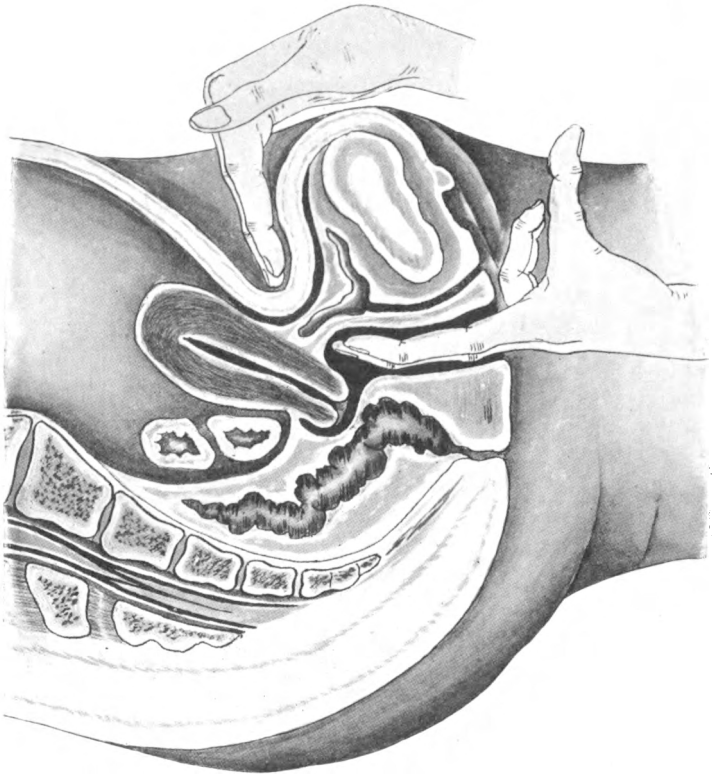


FIG. 3.—BIMANUAL PALPATION IN FRONT OF THE UTERUS.

(Fig. 1). In this position the size of the uterus is readily gauged, and any inequalities of its surface due to tumours are easily felt. By pressing both hands a little deeper the fingers of the two hands can be made to meet behind the cervix (Fig. 2); and by this manœuvre any swelling behind



the uterus is at once detected. If, on the contrary, the inner hand is withdrawn a little, and the outer one is brought near to the pubes, the fingers will pass over the fundus and meet in front of it (Fig. 3), when any swelling in front of the uterus is easily felt. There remain the two

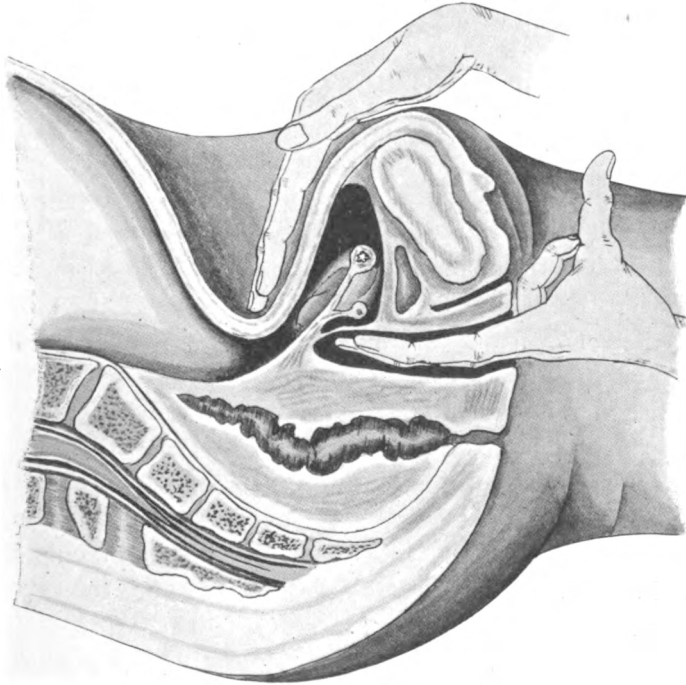


FIG. 4.—BIMANUAL PALPATION OF THE BROAD LIGAMENT AND FALLOPIAN TUBE.

lateral quadrants of the pelvis to be explored. The uterus is held between the two hands, as I have just described, and both hands are then moved to the left of the uterus, till the fingers meet on the broad ligament (Fig. 4): it is evident that the Fallopian tube is now lying transversely between the two hands, so that by moving both

hands towards himself, the examiner must strike the tube with his finger-tips. Once the tube is felt, as a rounded cord, it can be traced outwards towards the pelvic wall until the ovary is reached. This procedure will necessarily show whether there is any structure lying to the side of the uterus other than the normal broad ligament, tube, and ovary. In front of the tube, and a little below it, is the round ligament of the uterus, passing outwards to the inguinal ring; and this also can be readily felt in a thin patient. The right side of the uterus is examined in just the same way.

There is no doubt that in the majority of patients, especially married ones, the tubes and ovaries can be palpated in the manner just described; but sometimes the ovary is lying close up against the pelvic wall in its proper shallow fossa, and, indeed, this is its usual position in virgins; and then it may not be possible to feel it because it lies in a triangle formed by the pelvic wall on the outer side, the abdominal wall, depressed by the outer fingers, above and internally, and the vaginal wall, depressed by the inner finger, below and internally. Sometimes, in a thin patient with relaxed abdominal walls, not only the Fallopian tubes and round ligaments, but even the ureters can be palpated bimanually.

The student should lose no opportunity of practising the mapping out of the normal uterus, tubes, and ovaries, because a knowledge of the condition of the pelvic organs can only be obtained by this bimanual palpation; and, consequently, successful gynaecological diagnosis is dependent essentially on the trained touch, and not on any heaven-sent intuition.

## CHAPTER IV

### THE USE OF INSTRUMENTS FOR DIAGNOSIS

THE instruments used in gynæcological diagnosis are singularly few ; they consist of specula of various shapes and sizes for inspecting the vagina and cervix, and the uterine sound, for ascertaining especially the size and exact position of the uterus. We may mention as accessories vaseline or some such lubricant, swabs or absorbent wool, and swabholders.

**Specula.**—Of these there are several useful forms.

(a) *Ferguson's Speculum.*—This is a tube obliquely truncated at one end and broadened out into a kind of flange at the other. It is made of mirrored glass, celluloid, or silver-plated metal. The last is the best, because it gives a good illumination and is unbreakable ; but it is not adapted for treatment, because iodine in any form destroys the plating. The mirrored glass speculum gives a good light, and is not affected by caustics, but it is easily broken. The celluloid speculum is unbreakable, and, though discoloured, it is not otherwise affected by caustics, but it does not give such a good light. Ferguson's specula are usually made in three or four sizes, and it is convenient to have a set of metal ones for diagnostic purposes and a celluloid set for treatment. Ferguson's speculum is easily introduced, easily kept clean, and remains in position

without being held ; it gives a fairly good view of the vaginal walls while it is being introduced, and shows the cervix well. It is not, however, well adapted for cases in which there is much laceration of the cervix, because it presses the lips together, and thus conceals the amount of tear and the condition of the apposed surfaces. To introduce this speculum the left hand should be used from above to gently separate the labia ; the speculum is held firmly in the right hand, with the longest part of the bevelled end forming its lower border, and with this part the perineum is pressed backwards till the speculum slips easily into the vagina. It is pushed home in a line pointing to the sacral promontory.

(b) *Sims's Speculum*, or the Duckbill, usually consists of two blades of different sizes connected by an intervening handle, which is set at right angles to the blades. It is chiefly used with the patient in the semiprone position, but can also be used in the gynæcological position. A good view of the anterior vaginal wall and cervix can be obtained, but it requires to be held all the time, and this may necessitate the help of an assistant.

(c) *Barnes's, or the Crescent Speculum*, consists of two separate blades, each shaped like a crescent, of which the edges are turned up, so as to make it semicircular in section. One blade is slightly larger than the other, so that the two can be fitted together, when they form a tube at their point of contact. The larger blade is introduced with its turned-up edges pointing forward, and when it is in position the other blade is made to slide along it, with its turned-up edges pointing backwards. Then, by pressing the ends of the crescent that are outside the vagina towards one another, the inner ends are separated, and so give a good view of the cervix and deeper parts of the vagina.

## The Use of Instruments for Diagnosis 33

(d) *Neugebauer's Speculum* is a modification of the preceding, each blade consisting of only half a crescent, the other half being replaced by a straight portion, which is used as a handle. Neugebauer's speculum is easier to manipulate than Barnes's, but it is used in a similar way, and has the same advantages. For example, in a case of lacerated cervix the separation of the inner ends of the blades holds the lips of the cervix apart; the full extent of the laceration is appreciated, and the apposed surfaces are brought into view.

(e) *Cusco's, or the Bivalve Speculum*, has two blades, like those of Sims's speculum, fixed together at one end with a hinge. The closed ends of the blades are introduced, and then separated by manipulation of a screw acting on the hinge. This speculum is very easy to introduce, but is not very easily kept clean. It serves the same purposes as the two previous ones, and in addition it gives a very good view of the lateral walls of the vagina. While closing it prior to withdrawal, one has to be careful not to pinch the vaginal walls between the blades.

For most purposes it is sufficient to be provided with Ferguson's specula and a Neugebauer speculum.

**The Uterine Sound.**—This is a very useful and much-abused instrument. It is a rod of flexible copper, silver-plated, set in a handle, and with the last  $2\frac{1}{2}$  inches of its free end bent so as to form an angle of about 130 degrees with the rest. It is graduated in inches. It has a twofold purpose in diagnosis—namely, to measure the length of the uterine cavity when it is necessary that this should be exactly known, and to determine the position and direction of the uterus when this cannot be made out by bimanual examination. Thus it is specially useful when the pelvis is occupied by two or more swellings and the fingers are not able to determine which of these is the body of the uterus.

The sound has a third purpose—namely, for treatment, when we desire to place in its proper position a backwardly displaced uterus, and this reposition cannot be effected with the fingers alone.

The sound is said to be a very dangerous instrument, and so it is when it is used in an improper way and at improper times. The most important contra-indication to its use is when there is the slightest suspicion of the possibility of pregnancy. The most important point to remember as to the way of using it is that the passage of the sound is purely a matter of direction, and that any resistance is to be the signal, not for using more force, but for altering the direction. When the point of the sound is passing in the proper direction it enters the uterine cavity almost by itself.

**How to use the Sound.**—The first thing is to determine the position of the uterus by bimanual examination, if this is practicable. Then, with a picture of that position in one's mind, and the guiding finger in the vagina giving indications, the point of the sound is directed towards the fundus. Supposing, in the first place, that the body of the uterus is lying forwards. The patient being in the gynæcological position, the finger is passed into the vagina until its tip rests just below the os externum. The sound is held in the right hand, with its concavity forwards, and the point is passed along the palm of the finger until it enters the os (Fig. 5, 1). The manipulation is easier when two fingers can be introduced into the vagina; they are placed so that the os externum forms a continuation of the groove between the fingers. As soon as the point of the sound is within the os, the handle is carried backwards in the middle line till the terminal piece of the sound is in a straight line with the cervical canal, when it will slip in as far as the os internum (Fig. 5, 2). The

handle must now be carried further back towards the perineum, till the terminal piece of the sound is in a straight line with the cavity of the body of the uterus; and the cervix will be carried back with it (Fig. 5, 3), and the

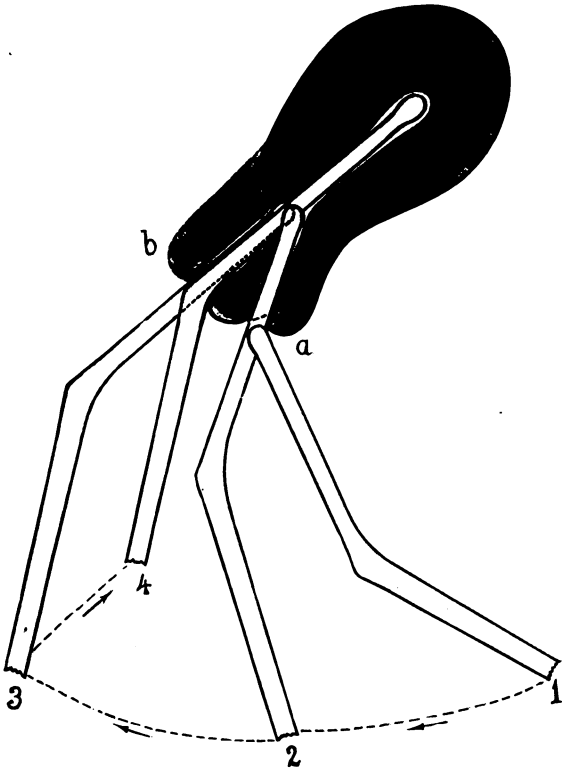


FIG. 5.—DIAGRAM TO ILLUSTRATE THE METHOD OF PASSING THE SOUND INTO A NORMAL UTERUS.

The successive positions are shown as 1-4. *a*, The cervix in its normal position; *b*, the position of the cervix when it is drawn back into line with the body of the uterus.

sound will then slip in without difficulty as far as the fundus (Fig. 5, 4). *It is purely a matter of direction.*

We may now suppose that the fundus is lying retro-

verted. The first step in the passing of the sound is as before, and as the axis of the cervix is probably parallel with that of the vagina, the point of the sound will probably pass in at once to the os internum (Fig. 6, 1).

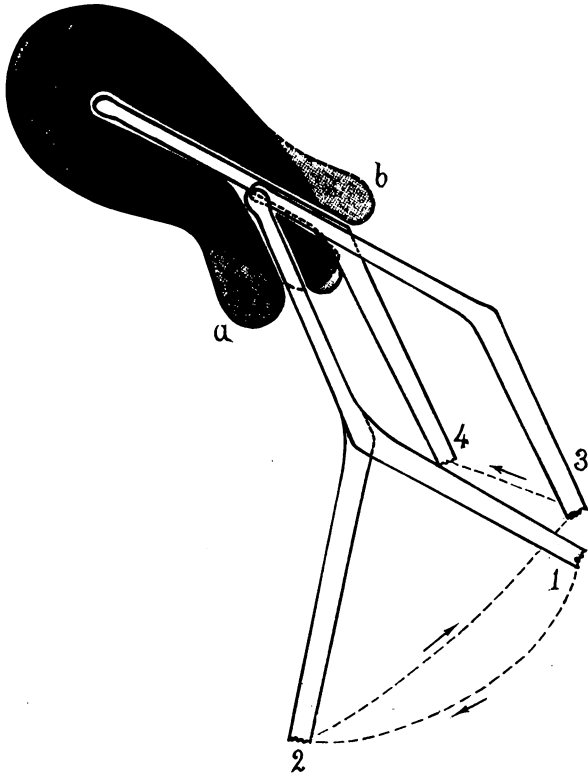


FIG. 6.—DIAGRAM OF THE SUCCESSIVE STAGES (1-4) IN PASSING THE SOUND INTO A RETROVERTED UTERUS.

*a*, Position of the cervix in the first and second stages; *b*, position of the cervix in the third and fourth stages.

The handle of the sound is now made to describe a semi-circle, the distal piece of the sound simply turning on its own axis, and thus the concavity of the sound comes to lie backwards (Fig. 6, 2). The handle of the sound is



now carried forward in the middle line, until the distal piece of the sound is in a straight line with the cavity of the body of the uterus (Fig. 6, 3); by this manœuvre the cervix and vaginal walls will be carried forward, and the sound will be felt to slip in easily to the fundus (Fig. 6, 4). Again we must insist that *it is purely a matter of direction*.

It is sometimes taught that when there is much flexion, the cervix may be seized with a volsella and drawn down, to facilitate the passage of the sound. This is bad practice, as it injures the cervix, and is never necessary if one has even the most rudimentary skill in the handling of the sound.

The passing of a sound is a difficult matter only in those cases in which one does not know where the fundus is—for instance, when there is a tumour in addition to the uterus, and one cannot tell which is which. In this case the sound should be passed as far as the os internum, and then various directions should be gently tried until the right one is hit upon. The position of the sound will then indicate the position of the uterus, and differentiate this from the other swelling.

**Swabs and Swab-holders.**—It is obvious that if the vagina contains unhealthy secretions, harm may be done if the sound is passed through these and carried up into the uterine cavity. Clearly, the sound should not be used at all in such a case. Even when the secretions appear to be normal, it is advisable to swab out the vagina before introducing the sound. For this purpose small swabs or pledgets of absorbent wool may be used, held in a uterine dressing forceps or in a swab-holder. These accessories are also used when a speculum has been introduced, in order to remove mucus or other discharge, and so obtain a clear view of the cervix.

## CHAPTER V

### THE SIGNIFICANCE OF SYMPTOMS

I PROPOSE in this chapter to make a general and rather rapid survey of symptoms, in order to point out what their significance may be. And, first, let me utter this note of warning, that many symptoms of which women complain, and especially vague pains in the region of the abdomen and pelvis, are not due to pathological conditions of the genital organs, but are the result of functional disorders quite independent of the uterus or ovaries. Many such pains are due to flatulence and constipation; others may originate in the kidneys; others, again, are the result of neuritis or rheumatism. The realization of this fact will clear away a good deal of the doubt and uncertainty that are generally supposed to be inherent in gynæcological diagnosis. One often hears the criticism that gynæcological symptoms are commonly so vague, and the reply to this is that vague symptoms are commonly not gynæcological. We shall find gynæcological diagnosis much simplified if we realize that we can often entirely exonerate the pelvic organs when they are thought to be responsible for vague symptoms.

The individual symptoms in gynæcological cases are few, but they present different groupings in different cases. At the same time it must be remembered that a particular

group of symptoms may be equally characteristic of several widely different conditions, and then we are more particularly dependent on what is, after all, our final and only reliable guide to a diagnosis—namely, the physical examination of the patient.

It is evident, therefore, that a discussion of symptoms is by no means a complete exposition of diagnosis. It is only a lesson in the first steps of diagnosis, a kind of preparatory stage, which is, however, not without its value if its true purport be realized, and this we may sum up briefly thus: *The purport of the investigation of symptoms is the intelligent anticipation and the subsequent interpretation of physical signs.*

And so we must never be deluded into imagining that the investigation and weighing of symptoms, however carefully done, will ever relieve us of the necessity of completing the diagnosis by examination. It is true that we may examine and yet be mistaken in our diagnosis: this happens to all, from the most experienced to the novice, and is excusable; but to fail to make a correct diagnosis merely from neglect to examine is a mistake for which little excuse can be found, and no allowance on the patient's part is likely to be made.

The principal symptoms met with in gynæcological cases are the following:

1. Amenorrhœa.
2. Pain.
3. Hæmorrhage—
  - (a) Related to menstruation;
  - (b) Independent of menstruation.
4. Discharge.
5. Bladder and bowel disturbances.
6. Pruritus.
7. Dyspareunia.
8. Sterility.

I. **Amenorrhœa.**—The significance of this symptom varies according to whether it is primary or secondary.

(a) *Primary amenorrhœa* means, of course, that the patient has never menstruated, although she has reached an age at which menstruation has generally become established. It may happen that a patient who comes to us with primary amenorrhœa is actually pregnant, but the occurrence of pregnancy before the patient has ever menstruated is such a rare phenomenon that the possibility can be practically dismissed. We must, then, consider whether the patient is suffering from one of the constitutional conditions which tend to retard puberty, and among such conditions we may specially enumerate anæmia, tuberculosis, and myxœdema. If we can exclude these, the case is one either of merely late development—that is, retarded puberty—or of under-development of the internal organs; which it is can readily be ascertained by examination, for in late development the organs will be normal, whilst in under-development they will be under-sized. It is seldom, however, that there is any urgency in settling the point, unless a patient who has not menstruated is going to be married; therefore the case can generally be left to declare itself in the course of time.

There is one fallacy to be guarded against, and that is that we do not mistake for amenorrhœa a case which is really one of retained menses, or cryptomenorrhœa, associated with an imperforate vagina.

Irregular and scanty menstruation may be merely an intermediate stage in the direction of complete amenorrhœa in the case of anæmic or tuberculous patients.

(b) *Secondary amenorrhœa*, like primary, may be due to constitutional conditions — anæmia, myxœdema, morphinism, and sometimes phthisis or some recent acute illness. It obviously cannot be due to late development, but it may be the result of under-development, for there

are rare cases where the reproductive organs are so poorly developed that a woman menstruates a few times, or perhaps for a few years, and then reaches an abnormally early menopause. So also a premature climacteric may come on between the ages of thirty and forty-five as the result of a physical or mental shock or from too rapid child-bearing.

The clinical picture of primary amenorrhœa associated with retention of menstrual products has its parallel in the case of secondary amenorrhœa, for, as the result of pathological conditions, the os uteri may become obliterated, so that, though the menstrual function is going on, its products cannot escape, and a secondary hæmatometra results.

Last, but by no means least, amenorrhœa is an indication of pregnancy, and with reference to this possibility we must never be off our guard. From the age of puberty to that of the climacteric, and even later, whether the patient be single, betrothed, married, widowed, separated from her husband or divorced, rich or poor, and whatever her political opinions or religious persuasions, pregnancy must always be thought of as a possibility, especially when the amenorrhœa has suddenly followed a period of normal and undiminished menstruation. It may be noted, in contrast, that when amenorrhœa is the result of constitutional conditions, the periods have commonly become irregular and have progressively diminished in quantity before ceasing altogether.

2. **Pain.**—I may say at once that the diagnostic value of pain as a symptom may be very little or very great. Some serious conditions are practically painless, and, on the other hand, there may be 'much cry and little wool.' Then, again, the personal factor enters very largely into the question: one patient makes very light of pain which another patient who suffers from it in the same degree may find unbearable; and, as the late Matthews Duncan

remarked, we have no odynometer, no independent criterion, beyond the patient's own statement, as to how bad the pain is. While, therefore, we accept pain as a guide in our diagnosis, we must recognise that it may be a very fallible one. It will, perhaps, help us most if we consider it as it falls under four categories :

- (a) Periodic.
- (b) Intermittent and irregular.
- (c) Frequent or constant.
- (d) Acute.

(a) *Periodic Pain*.—This may be menstrual, intermenstrual, or associated with coitus. Menstrual pain is often present when no abnormal physical condition can be detected, but there are, nevertheless, several pathological conditions that should be looked out for in cases of dysmenorrhœa. When the pain is referred especially to the back or to the suprapubic region, we shall often find that something is wrong with the uterus, such as a retroversion, endometritis, or stenosis of the cervical canal; if the pain be referred more especially to the iliac region, we may find a prolapsed and tender ovary or some inflammatory condition of the appendages. But we can only speak in the most general terms of the diagnostic significance of dysmenorrhœa.

Intermenstrual pain is as yet not well understood, but it has been found associated in a number of cases with tubal disease, and therefore its occurrence should lead to a careful examination of the appendages.

Pain associated with coitus will be considered later, under the heading of 'Dyspareunia.'

(b) *Intermittent and Irregular Pain*.—Many women are subject to vague abdominal pains, irregular both in time and in distribution, and these are nearly always due to flatulence. Sometimes a definite pathological condition

is also present, such as prolapsed ovaries or inflamed tubes, but the pain may be really due to flatulent distension of the bowel pressing on the sensitive structures in the pelvis.

(c) *Frequent or constant pain* in the pelvis and abdomen, radiating to the back and thighs, is generally due to pelvic inflammation or to displacements. Of the latter, the two conditions most likely to be met with in such a case are a heavy retroverted uterus, with perhaps an erosion of the cervix, and prolapse of the uterus and pelvic floor. The pain complained of is then essentially of the 'bearing-down' type, the patient feeling 'as if her inside were falling out.' Constant pelvic pain may also be due to a tumour blocking up the pelvis. The tumour may be a retroverted gravid uterus, a fibromyoma, or an impacted ovarian tumour.

There is a form of constant pain referred especially to the back, and accompanied by a good deal of leucorrhœa and general lassitude, which is due to uterine and ovarian congestion brought about by sexual excess either in the married or in single women who are the subjects of nymphomania; and this must be borne in mind, because, unless it is possible to bring the matter home to the patient and induce a change of habits, one may be sorely baffled both in accounting for the pain and in curing it.

(d) *Acute Pain*.—We may distinguish two types of acute pain according as the mode of onset is sudden or gradual.

I. Acute pain with a sudden onset is met with notably in four conditions. We have first the sudden pain referred chiefly to the back, and reflected forwards over the abdomen, which sometimes accompanies and marks the occurrence of a backward displacement of the uterus when this is the result of a fall or a sudden strain. Next there is the sudden and often diffused abdominal pain

which sometimes occurs with the rupture of an ovarian cyst. It must be remembered, however, that such rupture may be painless. Thirdly, there is the well-marked and localized acute pain which is due to the twisting of the pedicle of an ovarian cyst. This pain is not usually associated with much collapse, but may be accompanied by vomiting. Lastly, there is the localized acute pain which accompanies the rupture of a tubal gestation sac, and is associated with profound shock and collapse.

II. On the other hand, acute pain may have a gradual onset, and it generally signifies the presence of peritonitis or a pelvic abscess. It will then be necessary to distinguish the origin and nature of the peritonitis, which may be due to pus-tubes, to tubal pregnancy, or to inflammatory changes supervening in an ovarian cyst or a uterine fibroid.

3. **Hæmorrhage.**—Passing on in our somewhat rapid review, we come to hæmorrhage as a diagnostic symptom. It will be of assistance to our diagnosis if we consider hæmorrhage under three obvious headings, according as it is—

- (a) Associated with menstruation ;
- (b) Independent of menstruation ;
- (c) During pregnancy.

(a) *Hæmorrhage associated with Menstruation, or Menorrhagia.*—In early puberty menstruation is sometimes rather profuse on several occasions before the process settles down to its normal course. This is merely functional, and need cause no anxiety. It is comparable to the corresponding disturbance which sometimes characterizes the cessation of menstruation with the menopause.

Later on moderate menorrhagia is found associated with a number of widely different conditions, of which the simplest is uterine congestion. As a rule, the only other



symptom will be a certain amount of leucorrhœa, and sometimes backache. With more pronounced symptoms we may find that the congestion is complicated by a backward displacement of the uterus, or by chronic endometritis.

When in addition to menorrhagia there is a history of gonorrhœal infection, we must be on the look-out for salpingitis or pyosalpinx. Unfortunately, it is not a very rare thing to find a young married woman presenting within a few months of her marriage this combination of symptoms, the shadow of which is destined to be projected over all her married life. In other cases the history is that menorrhagia has followed a miscarriage or a labour at full time, and we may then expect to find subinvolution or a portion of retained placenta. The latter is especially prone to follow a miscarriage occurring between the third and the sixth month.

Profuse menorrhagia nearly always points to one of two things—namely, a polypus (whether mucous, fibroid, or placental) or uterine fibromyoma. In the case of a single woman or a nullipara, the probability is in favour of a mucous polypus or fibroids; in a parous woman, a placental polypus is the most likely thing.

(b) *Hæmorrhage Independent of Menstruation.*—This kind of hæmorrhage is always due to some new growth. It is difficult to generalize accurately, but we may take it as a working principle that profuse hæmorrhage is generally due to a simple tumour—namely, polypus or fibroids—and that moderate and irregular hæmorrhage is more often associated with malignant disease. In the latter case we usually find that, in addition to the bleeding, there is a more or less offensive discharge. There are four types of malignant disease to be borne in mind—namely, sarcoma, carcinoma of the body of the uterus, carcinoma of the cervix, and deciduoma malignum. The two former are

generally found in single women and nulliparæ; carcinoma of the cervix is usually, and deciduoma is necessarily, found in parous women.

I should like to take this opportunity of exposing in the plainest possible terms the fallacy that irregular hæmorrhages occurring at the time of the menopause are usually or frequently functional. It is not so. In the great majority of cases—probably 95 per cent.—they are due to some definite pathological organic condition, and we shall be led into fatal mistakes if we ever give them the benefit of the doubt. Every such case must be examined at the earliest possible opportunity, and the hæmorrhage must be assumed to be due to something serious until the reverse has been definitely proved.

(c) *Hæmorrhages during Pregnancy.*—It is often supposed that women can menstruate during pregnancy. I have always doubted whether true menstruation could occur at such a time; and as I have never met with an authenticated case, I am still sceptical. But irregular hæmorrhages can and do occur; and in the presence of such a case we shall have to seek its diagnostic explanation. The bleeding may be due to a laceration, to congestion of the cervix, to varicose veins in the vagina and vulva, to complications by fibroids or carcinoma of the cervix, to a threatened miscarriage, hydatid mole, placenta prævia, or accidental separation of the placenta. The detailed discussion of these conditions would carry me too far into the realm of obstetrics.

There is, however, one kind of hæmorrhage during pregnancy which is more especially gynaecological. When, after missing only one or two periods, or perhaps none, a woman begins to suffer from a slight brownish discharge; when there is perhaps a history of a possible abortion, and this same discharge continues, we must always investigate the case closely, bearing in mind the

possibility that we have to do with an extra-uterine gestation. It will be remembered that the characteristic associated symptom is definite one-sided pain, often following a sudden attack of syncope; and that whereas hæmorrhage due to a miscarriage is nearly always free and often bright red, that due to ectopic pregnancy is essentially scanty and dark or brownish in colour.

4. **Discharge.**—The significance of vaginal discharge depends upon its character and amount. The varieties met with are as follows:

(a) A thick white, creamy or curdy discharge is the normal vaginal secretion, and is of very little importance. When abundant it signifies functional congestion.

(b) A clear viscid discharge is the normal cervical secretion, and is seldom seen except through the speculum. When abundant it becomes mixed with the vaginal secretion, so that the discharge is partly clear and viscid and partly white and opaque. To this discharge the term leucorrhœa, or 'the whites,' is properly applied. It indicates uterine congestion, and is found normally just before and after menstruation.

(c) A muco-purulent or purulent discharge, yellowish or greenish according to the proportion of pus, is due to one of three conditions—namely, vaginitis, endometritis, or cervix - adenoma (erosion). When due to vaginitis, especially the gonorrhœal variety, it is thick and abundant; when due to one of the other conditions it is mixed with mucus. It is sometimes included in the popular term 'the whites'; the correct name for it is 'xanthorrhœa.'

(d) A fœtid watery discharge signifies the presence of ulceration, which may be due to a retained pessary, a sloughing fibroid or polypus, decomposing placental fragments, or, most frequently, uterine cancer.

(e) A blood-stained discharge may be produced by any of the causes of ulceration just mentioned, or by an

endometritis, a laceration, a readily-bleeding erosion, or an ulceration of the vagina in a case of procidentia. The colour may vary from a light rose tint to the red of almost pure blood. When a patient complains of bleeding after intercourse, we should look out for erosion, cancer of the cervix, or cervical polypus.

(f) A brownish discharge is found most characteristically in the case of extra-uterine pregnancy, but may also be produced by any condition leading to slight bleeding, clotting in the vagina, and slow decomposition of the clot.

5. **Disturbances of the Bowel and Bladder.**—One of the principal bowel disturbances is, of course, constipation; but inasmuch as a large proportion of women with healthy pelvic organs suffer from constipation, we can clearly attach no great diagnostic importance to it. We find, however, that constipation is sometimes accounted for by pressure on the rectum due to retroflexion, tumours, or pelvic inflammation. Of somewhat more value as a symptom is pain during defæcation, which may be due to one of the causes just mentioned, or to prolapsed and tender ovaries.

Bladder disturbances are often of great significance.

(a) *Painful micturition* is frequently associated with gonorrhœal vaginitis; in other cases it may be due to urethral caruncle, or, rarely, to foreign bodies in the bladder.

(b) *Frequent micturition* may result merely from pelvic congestion, or it may indicate some displacement of the normal position of organs, as in cases of cystocele and prolapse of the uterus; or some irritation due to pressure on the base of the bladder, such as may arise from retroversion, when the uterus is large or pregnant; or from a pelvic tumour or inflammatory mass pressing the cervix against the bladder. Thus it is found in the case of fibroids, especially cervical ones, and subperitoneal myomata lying in the pouch of Douglas; it is sometimes due to an

impacted ovarian tumour, or to an extra-uterine pregnancy occupying the pouch of Douglas.

(c) *Retention of urine* is produced by any of the previous conditions, when the growth or swelling is large enough, not only to irritate the base of the bladder, but also to compress the bladder or urethra against the pubes. Retroversion of the gravid uterus is probably the most common cause of retention of urine.

The occurrence of retention during or just before the menstrual periods, with freedom, or, at most, frequency of micturition, in the intervals, is almost diagnostic of uterine fibroids, the swelling of the uterus and tumour incidental to the menstrual congestion being sometimes just sufficient to lead to retention, whilst after menstruation the subsidence of congestion leaves the bladder free.

6. **Pruritus.**—This symptom is naturally not one of great importance from the point of view of diagnosis, although it may do more to make a woman's life miserable than all other symptoms put together. We shall have to be on the look-out for vulvitis and kraurosis vulvæ as the principal direct causes of pruritus, whilst the occurrence of leucorrhœa at the same time will lead us to suspect that the pruritus is due to irritating discharges in cases of erosion and endometritis. There is sometimes considerable pruritus merely as the result of congestion—for example, during pregnancy, or when the vulva and vagina are affected with varicose veins. There is also a somewhat constant relation between pruritus and masturbation, but whether the habit is induced by the pruritus or is the cause of it I cannot say.

7. **Dyspareunia.**—This may be an indication of two quite different sets of conditions, according as the pain on intercourse is referred (a) to the vaginal orifice, or (b) to the deeper parts of the pelvis.


(a) *Pain referred to the vaginal orifice* may be due to

stenosis of the orifice, a rigid hymen, some abrasion, ulceration, or trauma of the vulva, urethral caruncle, urethritis, painful hymeneal caruncles, vulvitis, or vaginitis. The history will give us some further indication as to what we are likely to find. Thus, if the patient has not been married long, or if dyspareunia has existed from the first, she probably has stenosis or a rigid hymen; if the patient has been married some years, and the dyspareunia is a recent development, it is likely to be due to painful urethral or hymeneal caruncles; if there is a history of discharge or injury we shall look for some inflammatory condition or trauma.

(b) *Pain referred to the deeper parts of the pelvis* is most often due to inflammatory disease of the appendages, to endometritis, retroversion, or prolapsed and tender ovaries. The combination of retroversion and prolapsed ovaries is frequently met with; any pressure on the cervix, whether during intercourse or during examination, causes pain from pressure on the ovaries.

8. **Sterility.**—This symptom is often of value in telling us what we may expect to find. The sterility may be primary or secondary.

(a) *Primary Sterility.*—When a woman has had no children after several years of married life, the first point to consider is whether the sterility is due to underdevelopment or malformation, or whether it results from inflammatory disease of the Fallopian tubes; so we shall start by inquiring whether there is any history of gonorrhœa. If we elicit such a history, we shall at once examine carefully into the condition of the uterine appendages. If there has been no gonorrhœa, we shall inquire into the characters of menstruation. When this has come on late, and is scanty and irregular, some degree of underdevelopment of the uterus or ovaries may be expected. When menstruation has the normal characters, except that



it is very painful, we must look for anteflexion of the uterus with stenosis of its canal, or the faulty condition may be retroflexion.

Endometritis is a frequent cause of sterility, but not generally in the first instance. A history of dyspareunia in the case will suggest the possibility of some mechanical obstacle to complete intercourse.

In a case where the principal symptom besides sterility is menorrhagia or metrorrhagia, we may suspect the presence of fibroids, for there is a rather close relation between these tumours and sterility.

(b) *Secondary Sterility*.—By this is meant that a woman has borne one or two children and has then become sterile, although still at a child-bearing age.

A frequent cause of secondary sterility is endometritis, with or without some displacement, or a woman may have contracted gonorrhœa after a confinement, with the result that her tubes have become disorganized. Lastly, secondary sterility, like the primary variety, may be associated with fibroids.

We have now traced in rapid outline the symptoms most commonly found in gynæcological cases, and indicated the conditions which such symptoms should lead us to look out for. When we have got so far, diagnosis is not completed; on the contrary, we have only embarked on its initial stage. The second and more important stage is before us—namely, the investigation of the physical signs present in the case. This I shall consider in the following chapter, and, just as deductions from symptoms have to be confirmed and corrected by physical signs, I shall endeavour to show that signs have to be interpreted in the light of symptoms.

For convenience of reference I have appended a synopsis of the observations contained in this chapter.

SYNOPSIS OF THE DIAGNOSTIC SIGNIFICANCE OF GYNÆCOLOGICAL SYMPTOMS.

Predominant Symptom.	Associated Symptoms.	Provisional Diagnosis.
<b>1. AMENORRHŒA.</b>		
(a) Primary ... ..	Symptoms of anæmia, tuberculosis, etc.	Constitutional amenorrhœa
" ... ..	None	Delayed puberty or under-development
" ... ..	Periodic abdominal pain and swelling	Cryptomenorrhœa
(b) Secondary ... ..	Symptoms of anæmia, myxœdema, morphinism, recent exanthemata	Constitutional amenorrhœa
" ... ..	Sickness, abdominal swelling, etc.	Pregnancy <sup>1</sup>
" ... ..	Periodic abdominal pain	Hæmatometra (cryptomenorrhœa)
" ... ..	None	Superinvolution
" ... ..	Flushes, heats, etc.	Menopause
<b>2. PAIN.</b>		
(a) Periodic : (i.) Menstrual ... ..	Pain is hypogastric or sacral	Stenosis ; anteflexion
" ... ..	Pain is hypogastric or sacral ; leucorrhœa ; menorrhagia	Endometritis ; erosion ; displacements
" ... ..	Pain is markedly lateral	Prolapsed ovaries ; diseased tubes
(ii.) Intermenstrual ... ..	Hydrorrhœa	Tubal disease
(b) Intermittent and irregular ... ..	Constipation ; nausea, etc.	Flatulent dyspepsia
(c) Frequent or constant ... ..	Leucorrhœa ; bearing down ; lassitude	Endometritis ; congestion ; sexual excess ; retroversion ; prolapse
" ... ..	Leucorrhœa ; weight ; disturbances of bowels and bladder	Impacted pelvic tumour
" ... ..	Leucorrhœa ; weight ; disturbances of bowels and bladder ; amenorrhœa	Retraction of the gravid uterus ; extra-uterine gestation



(d) Acute : (i.) Sudden onset ...	Pain referred to back ; bearing down	Retroversion
"	Pain referred to abdomen ; sinking feeling	Rupture of ovarian cyst
"	Pain referred to side ; sickness ; temperature	Twisting of the pedicle of a tumour
"	Pain referred to side ; shock ; collapse ; previous amenorrhœa	Ruptured extra-uterine gestation
(ii.) Gradual onset . . .	High temperature ; rigors	Peritonitis ; pelvic abscess
3. HÆMORRHAGE.		
(a) Menstrual (menorrhagia) ...	Early puberty	Functional congestion
"	Moderate menorrhagia ; leucorrhœa	Congestion ; endometritis ; retroversion ; early fibroids
"	Xanthorrhœa ; painful micturition	Salpingitis ; pyosalpinx
"	Recent labour or miscarriage	Subinvolution ; retained products
"	Profuse menorrhagia ; blanching	Polypus ; fibroids
(b) Intermenstrual (metrorrhagia) ...	Recent labour or miscarriage	Placental polypus
"	Pain ; sterility	Fibroids
"	Pain ; offensive discharge	Malignant disease
"	Hæmorrhage after coitus	Urethral caruncle ; erosion ; cervical polypus ; carcinoma of cervix
(c) During pregnancy ...	None	Laceration of cervix ; varicose veins (menstruation during pregnancy)
"	Bearing-down pains	Threatened miscarriage ; placenta prævia ; accidental hæmorrhage
"	Discharge of grape-like follicles	Hydatidiform mole
"	Offensive discharge	Pregnancy with carcinoma of cervix
"	Lateral pain ; brownish discharge	Extra-uterine gestation
4. DISCHARGE.		
(a) White creamy ...	None ; or backache, etc.	Functional congestion
(b) Clear viscid ...	None ; or backache, etc.	Uterine congestion
(c) Muco-purulent ...	Sacral or pelvic pain	Endometritis ; erosion ; vaginitis

SYNOPSIS OF THE DIAGNOSTIC SIGNIFICANCE OF GYNÆCOLOGICAL SYMPTOMS (*continued*).

Predominant Symptom.	Associated Symptoms.	Provisional Diagnosis.
4. DISCHARGE ( <i>continued</i> )		
(d) Purulent ...	Painful micturition	Vaginitis, especially gonorrhœa
" ...	None	Retained pessary
(e) Fœtid watery ...	None	Retained pessary; sloughing polypus
" ...	Menorrhagia	Sloughing fibroid or placental remains
" ...	Irregular hæmorrhage; pelvic pain.	Carcinoma
(f) Blood-stained ...	Sacral or pelvic pain	Erosion; ulceration from foreign bodies; carcinoma
" ...	Bearing down; external swelling	Ulceration of cervix or vagina in procidentia
" ...	None	Mucous polypus
(g) Brownish ...	Lateral pain; recent amenorrhœa	Extra-uterine pregnancy
5. BOWEL AND BLADDER DISTURBANCE.		
(a) Painful defæcation ...	Pelvic pain	Retroflexed fundus; prolapsed ovary; pelvic tumour
(b) Painful micturition ...	None, or blood-stained discharge	Urethral caruncle; foreign body in the bladder
" ...	Xanthorrhœa	Gonorrhœal vaginitis
(c) Frequent micturition ...	Backache; leucorrhœa	Functional congestion
" ...	Sacral, supra-pubic, and bearing-down pain	Cystocele; prolapse of uterus; retroversion, when enlarged
" ...	Three months' amenorrhœa	Retroversion of gravid uterus
" ...	Pelvic pain	Pelvic inflammation; impacted ovarian or fibroid tumour; carcinoma of cervix
" ...	Pelvic pain; menorrhagia	Impacted fibroid tumour

(d) Retention of urine	...	Three to four months' amenorrhœa	Retroverted gravid uterus ; extra-uterine gestation
"	...	Pelvic pain; normal or profuse menstruation	Large impacted pelvic tumour
6. PRURITUS.	...	Various	Congestion of pelvic organs, from pregnancy ; displacements, inflammation, or tumours
"	...	Pain in vulva	Vulvitis pruriginosa ; kraurosis
"	...	Leucorrhœa	Erosion ; endometritis
7. DYSpareunia.	...	None	Stenosis of vaginal orifice ; painful caruncles ; abrasion of vulvar orifice
(a) Pain referred to vulva	...	Leucorrhœa ; pain in vulva	Vulvitis ; vaginitis
(b) Pain referred deeply	...	Pelvic pain ; leucorrhœa	Retroversion ; prolapsed ovaries ; pelvic inflammation
8. STERILITY.	...	Dyspareunia, or incomplete coitus	Mechanical obstacles to intercourse ; imperforate vagina ; rigid hymen
(a) Primary	...	Scanty menstruation or primary amenorrhœa	Under-development
"	...	Dysmenorrhœa	Stenosis ; antelexion
"	...	Leucorrhœa ; pelvic pain	Retroversion
"	...	History of gonorrhœa	Inflammatory disease of the appendages
"	...	Long-standing sterility ; menorrhagia	Uterine fibroids
"	...	Menorrhagia	Fibroids
(b) Secondary	...	History of puerperal fever	Pelvic inflammation
"	...	Gonorrhœa following child-birth	Diseased appendages
"	...	Leucorrhœa ; pelvic pain.	Endometritis ; displacements
"	...		

## CHAPTER VI

### THE INTERPRETATION OF PHYSICAL SIGNS

I SHALL here make a survey of the different conditions that may be met with when making an examination, and consider their interpretation or significance. Many of them require no interpreting; they are self-evident, and to see them is to make a diagnosis, and yet they may permit of certain deductions. I shall proceed in the order which it is convenient to adopt in practice—namely:

1. Abdominal examination.
2. Inspection of the vulva.
3. Vaginal examination.
4. Bimanual examination.
5. Speculum examination.

1. **Abdominal Examination.**—On inspection, we may see the well-known striæ which indicate some previous distension of the abdomen, almost certainly pregnancy. It is a remarkable fact that the abdominal wall recovers its normal appearance much more readily after the removal of tumours or the subsidence of ascites than after pregnancy, so that striæ, although they are so frequent after pregnancy, are seldom seen after other forms of abdominal distension. Dilated veins or lymphatics indicate the probability of intra-abdominal pressure.

Swelling of the abdomen results from many conditions, and to facilitate our investigation we shall first note whether the swelling is general or localized.

*General swelling* may be due to fat, flatus, ascites, pregnancy, or a large tumour. Distension caused by obesity or flatulence is easily recognised by palpation and percussion, aided, if necessary, by examination under an anæsthetic. The so-called 'phantom tumour' is due to a combination of obesity, flatulence, and muscular rigidity, and the last condition masks the other two; an anæsthetic clears up the diagnosis by abolishing the rigidity. Ascites is indicated by the absence of definite borders to the swelling, dulness in the hypogastrium and flanks, with resonance in the epigastrium, the area of dulness having a margin concave towards the umbilicus, and by variations in the area of dulness on altering the position of the patient.

A fat patient may also have a tumour, and it is sometimes difficult to decide whether the distension is entirely due to fat and flatus, or partly due to pregnancy or a tumour. We may, then, derive some assistance from a sign pointed out by Varnier, which is this: On looking at the abdomen in profile, the movement of the abdominal wall caused by respiration is readily seen; if the abdomen is large on account of fat, flatus, or ascites, the contour of the abdomen will alter during respiration from the ensiform to the pubes (Fig. 7); whilst in the case of pregnancy or a tumour, the lower part of the abdominal wall, where it is in contact with the tumour, will remain 'splinted up,' or fixed, and the movement of the abdomen will occur only above the level of the tumour (Fig. 8).

In some cases a tumour may be complicated by the presence of free fluid in the abdomen; and we shall then have the definite outline of the tumour, and, in addition, we shall find dulness in the flanks, and variations in the

area of dulness on changing the patient's position. When hydroperitoneum (fluid in the belly) is due to tuberculous peritonitis, it is apt to become encysted by adhesions, and localized; so that it is sometimes impossible by physical signs alone to distinguish between this and an ovarian tumour.

If we can exclude the conditions enumerated so far, general enlargement of the abdomen is due to late




FIG. 7. RESPIRATORY MOVEMENT OF THE ABDOMEN IN THE ABSENCE OF A TUMOUR.




FIG. 8.—RESPIRATORY MOVEMENT OF THE ABDOMEN IN THE PRESENCE OF A TUMOUR EXTENDING UP AS HIGH AS THE UMBILICUS.

pregnancy, a large fibroid tumour or ovarian cyst, or a very large hydronephrosis. At such a stage of pregnancy, its diagnosis ought to be a simple matter, especially with the assistance of the history and symptoms, so we need not go into the question. If the tumour is hard and feels solid, and especially if the patient gives a history of menorrhagia, it is probably a fibroid. If it feels elastic and fluid, it is probably ovarian. It may be quite

impossible to distinguish between an ovarian cyst and a large hydronephrosis, unless we have the history to guide us, and to tell us whether the swelling originated in one or other flank—as would be the case with hydro-nephrosis,

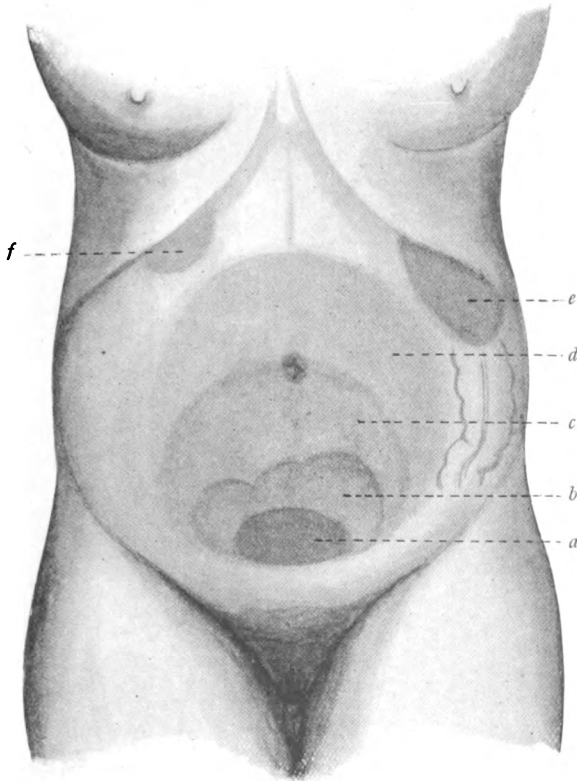


FIG. 9.—DIAGRAM TO ILLUSTRATE THE POSITION OF ABDOMINAL SWELLINGS.

- a*, Pregnancy at three months, or uniform uterine myoma; *b*, multiple uterine myomata; *c*, pregnancy at six months, ovarian or myomatous tumour; *d*, pregnancy at eight months, or large ovarian tumour; *e*, splenic tumour; *f*, enlarged gall-bladder or hepatic tumour.

or developed from the pelvis, as an ovarian would do.

A *localized swelling* in the abdomen may be due to the following conditions: Pregnancy, third to sixth month;

extra-uterine pregnancy; myomata; tumours of the ovary, round ligament or broad ligament; omental and retroperitoneal tumours; enlargement of the kidney from

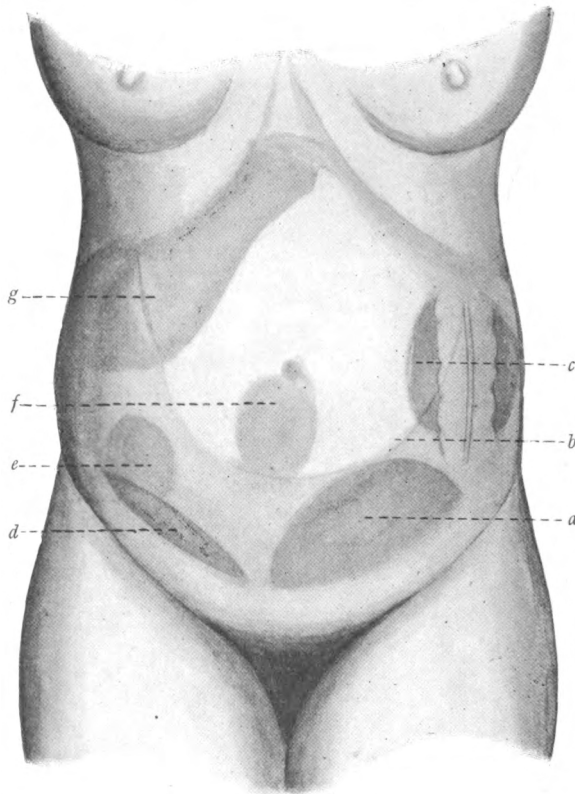


FIG. 10.—DIAGRAM TO ILLUSTRATE THE POSITION OF ABDOMINAL SWELLINGS.

- a*, Moderate-sized ovarian tumour, large pelvic abscess, or extra-uterine pregnancy; *b*, concave line of dulness with ascites; *c*, renal tumour; *d*, pelvic cellulitis, pelvic abscess, or appendix abscess; *e*, small appendix abscess; *f*, tumour of omentum or mesentery; *g*, enlarged liver.

hydronephrosis or new growth; movable kidney; enlarged spleen or liver; distended gall-bladder; malignant disease of the intestines; encysted peritoneal effusions; appendix



abscess, pelvic abscess, or pelvic cellulitis. The positions of these swellings are indicated in the diagrams (Figs. 9 and 10). Many of the conditions enumerated have nothing to do with the pelvic organs; nevertheless their differential diagnosis is sometimes a matter of difficulty. It has happened repeatedly that a tumour diagnosed as a fibroid has been found, on opening the abdomen, to be a large wandering spleen, and that an expected ovarian has proved to be a hydronephrosis or an encysted peritoneal effusion; disease of the tubes has been diagnosed and an appendix abscess found, and *vice versâ*. Hence the would-be gynæcologist should train himself particularly in the diagnosis of all abdominal conditions.

With such a diversity of conditions causing localized swellings in the abdomen, we need to have some method in our mode of investigation. The best plan is to first settle the question whether the tumour goes down into the pelvis or not. It is a warrantable assumption that a tumour which goes down into the pelvis originates there, although there are exceptions. We have then a starting-point for our analysis:

*Swellings that go down into the Pelvis.*

- Pregnancy.
- Uterine fibroids.
- Tumours of the round ligament.
- Tumours of the broad ligament.
- Ovarian tumours.
- Extra-uterine pregnancy.
- Diseased tubes.
- Pelvic cellulitis or abscess.
- Encysted pelvic peritoneal effusions.
- (Wandering spleen).
- (Appendix abscess).

*Swellings limited to the Abdomen.*

- Hepatic enlargement.
- Distended gall-bladder.
- Renal enlargement.
- Floating kidney.
- Enlarged spleen.
- Carcinoma of intestine.
- Omental and retroperitoneal tumours.
- Appendix abscess.
- Encysted abdominal peritoneal effusions.
- (Pedunculated fibroids).
- (Ovarian tumours with long pedicle).

*Swellings that go down into the Pelvis.*—When the swelling is median in position and uniform in outline, it is probably a gravid uterus, a uterine myoma, or a large ovarian tumour; it may also be an encysted tuberculous peritoneal effusion. A tumour of irregular outline is likely to be due to multiple fibroids; but an ovarian tumour sometimes takes on irregular shapes. When the swelling occupies a distinctly lateral position, it is probably a small ovarian tumour, a tubal pregnancy, diseased appendages, a pelvic abscess, or a fibromyoma of the round or broad ligament. It sometimes happens that a wandering spleen takes up a position in the pelvis, and simulates a fibroid or ovarian tumour; and an appendix abscess may spread downwards so as to resemble a pelvic abscess or pus-tube.

*Swellings limited to the Abdomen.*—I need not enlarge on these conditions, since the diagnosis of abdominal conditions in general does not come within my present scope; and it will be sufficient that I refer the reader to the list given above, and to the illustrative diagrams (Figs. 9 and 10).

**2. Inspection of the Vulva.**—The signs that may be observed on inspection of the vulva are:

- Malformations.
- Signs of inflammation or infection.
- Signs of traumata.
- Swellings of the vulva.
- Cutaneous conditions.

*Malformations.*—Marked scantiness of the pubic hair and an infantile condition of the vulva point to under-development. Elongation of the clitoris may mean that the organ is in reality an under-developed penis, in a subject known as a pseudo-hermaphrodite; in such a case the labia may be very full and rounded, and represent, in

fact, an unfused scrotum containing testicles. Lastly, we may find that there is no vaginal orifice, and in the place thereof there may be a bulging membrane, showing that the case is one of vaginal atresia with retained menses.

*Signs of Inflammation or Infection.*—Redness of the vulvo-vaginal orifice with exudation of muco-pus from the vagina points to vaginitis, probably gonorrhœal. The presence of pus in the urethra and in the orifices of the Bartholinian ducts is almost pathognomonic of gonorrhœa; so is a crop of condylomata. An indurated sore points to syphilis; and multiple sores indicate a mixed infection. In all these conditions we shall find enlarged inguinal glands, and in the case of chancroids there will probably be a suppurating bubo. Intense, sharply-defined redness about the vulva and adjacent areas may be due to erysipelas. It is important to remember that tuberculosis of the vulva may closely simulate venereal disease.

*Signs of Traumata.*—We may find a ruptured perineum, the tear, perhaps, extending into the rectum; in such a case there will almost certainly be some prolapse of the vaginal walls. Other traumata of accidental origin may be present.

*Swellings of the Vulva.*—In the first place, the swelling may be a protrusion through the vaginal orifice, consisting of cystocele or rectocele, a procident uterus, an inverted fundus uteri, or an extruded fibroid. These conditions are all tolerably self-evident, and no mistake is likely to arise in distinguishing between them. Or the swelling may affect the vulva proper. A swelling in the region of the clitoris is most likely to be a carcinoma. A red swelling in the urethral orifice is a caruncle of the urethra, springing from the posterior wall near the meatus. The only swelling at all commonly met with on the labia minora is a fibromyxoma. If the swelling affects the

labium majus, we must consider its position ; in the upper part of the labium we may meet with an inguinal hernia or a hydrocele of the canal of Nuck ; a swelling in the lower part of the labium will almost certainly be a Bartholinian cyst or abscess. A swelling affecting the whole of one labium may be a hæmatoma or a varicocele ; the former will be a firm or boggy swelling, the skin over which is discoloured ; the latter presents groups of enlarged veins, and is quite unmistakable. The labia are also subject to œdema, which may affect one or both sides, and involve the prepuce of the clitoris and the labia minora. Then we may get a carcinoma of the labium, or a pedunculated tumour, which will prove to be a fibromyxoma. Lipomata, fibromata, and papillomata are occasionally met with.

*Cutaneous Conditions.*—The vulva is liable to be affected by various skin diseases, such as erythema, eczema, herpes, and psoriasis. They present the same characters as in other parts of the body. A smooth, 'ironed-out' appearance of the vulva, associated with atrophy of the labia and contraction of the vaginal orifice is characteristic of kraurosis vulvæ.

3. **Vaginal Examination.**—In reviewing the physical signs observed on making a vaginal examination we may consider :

(a) The Condition of the vagina.

Malformations.

Traumata.

Displacements.

New growths.

(b) The cervix.

(c) Abnormal vaginal contents.

(d) The surroundings of the vagina.

(a) THE CONDITION OF THE VAGINA.—*Malformations.*—There may be two vaginal orifices instead of one, showing that the uterus is double ; or there may be only

one orifice leading into two separate vaginæ, divided by a longitudinal septum. Sometimes a well-marked ridge is found running down both the anterior and the posterior vaginal wall. This may mean that the vagina was a double one, and that the septum has become split, as, for instance, during labour. The presence of any of these conditions would lead one to look for two cervical openings. Instead of a longitudinal septum we may find a transverse one, the external part of the vagina being very short, and in this case, if the patient has passed the age of puberty, we shall expect to find either an under-developed uterus or retention of menstrual products above the occlusion. Or under-development may take the form of undue narrowing of the vagina.

*Traumata.*—Fistulous openings may be present in the vagina, communicating with the rectum, urethra, or bladder. They usually indicate some injury sustained during parturition, but may also be the result of ulceration, such as might be caused by carcinoma or by the retention for many years of an ill-fitting pessary. An ulcerated groove, with upturned edges, nearly always means that a pessary has been kept in over-long. Evidences of former tears in the vagina are sometimes found in the form of cicatricial bands. A common position for these to be found is in one or other lateral fornix, when a tear of the cervix during labour has spread beyond the cervix into the vagina.

*Displacements.*—Either the anterior or posterior wall of the vagina may be unduly lax and long, producing respectively a cystocele or rectocele. These have been mentioned in speaking of inspection of the vulva, for it is then that they are usually detected.

*New Growths.*—Smooth cystic swellings in the vaginal wall are usually due to distension of unobliterated remnants of Gartner's duct. This is the lower end of the

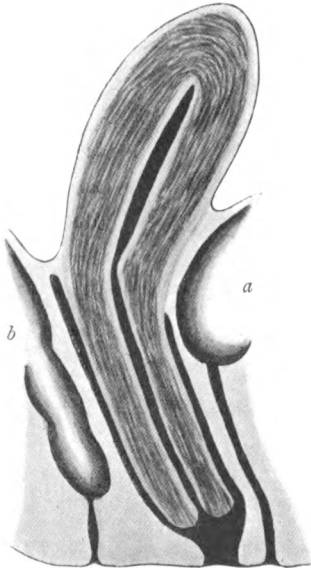


FIG. 11.—HYPERPLASIA OF THE VAGINAL PORTION OF THE CERVIX.

*a*, Bladder ; *b*, rectum.

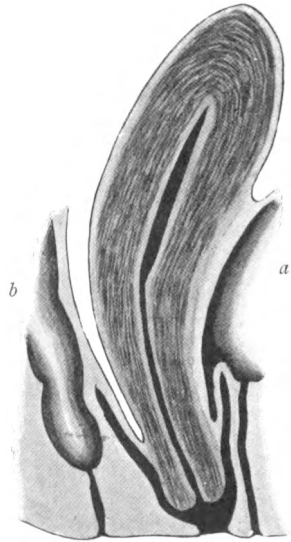


FIG. 12.—HYPERPLASIA OF THE SUPRAVAGINAL PORTION OF THE CERVIX.

*a*, Bladder ; *b*, rectum.

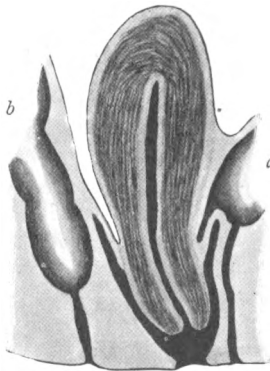


FIG. 13.—PROLAPSE OF THE UTERUS.

*a*, Bladder ; *b*, rectum.

fœtal mesonephric or Wolffian duct, and is the homologue of the vas deferens in the male. These cysts are sometimes multiple, and may even be traced into the broad ligaments. Solid growths in the vagina are nearly always of the nature of sarcoma or carcinoma.

(b) THE CERVIX.—The position of the cervix is the first thing that calls for attention. If it lies low in the vagina, we have to do either with prolapse of the uterus or with hyperplasia of the cervix. The latter is of two forms, according as the vaginal or the supravaginal portion of the cervix is the part involved. When it is the vaginal portion, the length of the vagina is not affected (Fig. 11). When the supravaginal portion is the seat of the hyperplasia, the vaginal vault is carried down with the cervix, so that the vagina is shortened (Fig. 12). Exactly the same thing happens with prolapse (Fig. 13), so that it is not possible to determine by vaginal examination alone whether the case is one of prolapse or of supravaginal hyperplasia.

Supposing the cervix is in its normal position, we shall note its direction. Normally this is downwards and backwards, and such a position will be presumptive evidence that the body of the uterus lies in the normal direction (Fig. 14, *a*), but it must be remembered that in a case of acute retroflexion the fundus may be bent back, while the direction of the cervix remains normal (Fig. 14, *b*). The converse is equally true, for when the cervix points downwards and forwards it is probable that the uterus is retroverted (Fig. 15, *a*) ; but the case may be one of ante flexion of the cervix, the body of the uterus lying forwards in the normal position (Fig. 15, *b*).

We now turn our attention to the size of the cervix. It may be small and conical in shape, when the os externum will be small, and we shall expect to find the uterus underdeveloped, or it may be the normal size, or it may be

## Gynaecological Diagnosis

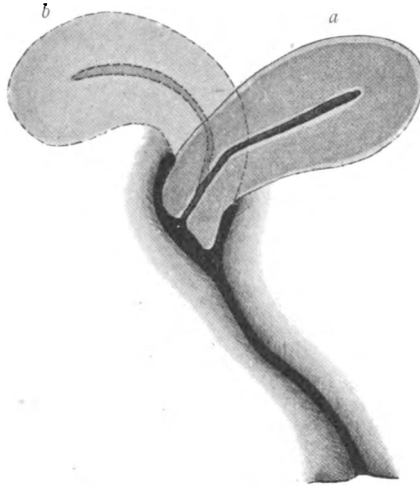


FIG. 14.—TWO POSITIONS OF THE FUNDUS WHEN THE CERVIX POINTS BACKWARDS.

When the cervix points backwards the fundus is usually lying forwards (*a*), but may be retroflexed (*b*).

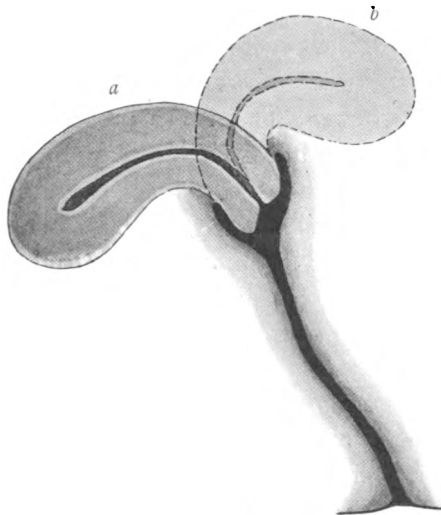


FIG. 15.—TWO POSITIONS OF THE FUNDUS WHEN THE CERVIX POINTS FORWARDS.

When the cervix points forwards the fundus is usually lying backwards (*a*), but may be anteflexed (*b*).



bulky, perhaps irregularly enlarged and the seat of a growth—namely, carcinoma. The os externum may be the normal, rounded, nulliparous one, or transversely elongated in a parous patient. It may be patulous, so as to admit the tip of the finger, the internal os being closed, or it may be widely open, so that the finger can be passed into the uterine cavity, when we shall find either a polypus or products of conception inside it. Lastly, we shall note whether there has been any undue laceration of the cervix, and whether there is evidence of adenoma of the cervix in the form either of soft velvety proliferation or of small shotty nodules, which are the retention cysts, called Nabothian follicles (see also section on the Speculum Examination).

(c) **ABNORMAL VAGINAL CONTENTS.**—These will include foreign bodies, such as pessaries, a forgotten tampon, or other objects mischievously introduced, products of conception extruded from the uterus, the fundus of an inverted uterus, or a fibroid tumour arising from or passing out of the cervix. A large fibroid may occupy the vagina, and so fill it up that it is impossible without, or even with, an anæsthetic to reach its deep attachment. All these things tell their own tale, the only difficulty likely to arise in the matter of diagnosis being to distinguish between an inverted fundus and a large polypus. The smooth, glistening surface of the latter will generally serve to distinguish it from the red, shaggy appearance of the former.

(d) **THE SURROUNDINGS OF THE VAGINA.**—The vagina may be encroached upon in front, behind, or on either side, but the interpretation of swellings found in these positions can seldom be arrived at by vaginal examination alone; it depends essentially on bimanual palpation. I shall therefore consider the surroundings of the vagina in connection with the bimanual examination in the next chapter.

## CHAPTER VII

### THE INTERPRETATION OF PHYSICAL SIGNS (*continued*)

4. **The Bimanual Examination.**—As I said in the chapter on Methods of Examination, the bimanual is the most important part of the examination; it should be systematic, and the outstanding landmark is the uterus. Having taken hold of the uterus between the two hands, its size and shape are estimated. It is only by practice in examining normal cases that we can readily appreciate a moderate enlargement of the uterus, and it is to be remembered that in a very fat patient we may get an exaggerated impression of enlargement, because the hands are separated, not only by the uterus, but also by the thickness of the abdominal wall. A slight enlargement may be due to simple hyperplasia or congestion, to early pregnancy, to tubal pregnancy, to subinvolution, to abnormal contents, such as a polypus, a small fibroid, a collection of pus (pyometra), or retained products of conception or menstruation (cryptomenorrhœa), or to malignant disease of the body of the uterus. In determining which of these conditions is present, we rely on the history of the case. Thus, if the patient has never menstruated, and there is vaginal or cervical atresia, the case is probably one of hæmatometra; if she is a virgin, we can exclude pregnancy and subinvolution; if she is under thirty, the probabilities are against malignant disease; if

there has been a period of amenorrhœa, we may expect to find pregnancy ; if a period of hæmorrhage has succeeded one of amenorrhœa, it may be a tubal pregnancy or a threatened abortion. If there has been a recent confinement or abortion, it is probably subinvolution or retention of conception-products. If there has been no suggestion of pregnancy, and the patient has suffered from hæmorrhage, it is probably a case of new growth of one of the forms enumerated.

These remarks apply to an enlargement up to the size of a large pear ; beyond that the diagnosis is rapidly narrowed down, because only three conditions can give rise to considerable enlargement of the uterus—namely, hæmatometra, pregnancy, and fibroids. It is an important diagnostic fact that carcinoma never produces any considerable enlargement of the uterus by itself, although it may occur in a uterus enlarged from other causes. It may also lead to pyometra.

The differentiation of the conditions producing considerable enlargement of the uterus is as follows :

When associated with primary amenorrhœa and atresia of the genital passages	} Hæmatometra.
With amenorrhœa and symptoms of pregnancy, softness of cervix, and uniform enlargement	} Pregnancy.
With regular or increased menstruation, hardness and perhaps irregularity of outline	} Fibroids.

Concerning the shape of the uterus, we have to consider, first, irregularities of outline due to tumours ; and, secondly, abnormalities due to malformations. The first point has been sufficiently dwelt upon in discussing the size of the uterus, and we must now say a few words about malformations.

An abnormally small size indicates under-development and this varies in degree, from a slight undersize, with normal shape, to the extreme condition of 'rudimentary' uterus, where, bimanually, a small knob surmounting the vagina is all that can be detected (Fig. 16). The intermediate stage is the 'infantile' uterus, where the fundus is small and the cervix relatively long (Fig. 17). A uterus with only one horn developed (uterus unicornis) is very difficult to detect bimanually, because the developed half has a compensatory breadth (Fig. 18); but if the fundus can be made out to be rounded off on one side, with an abnormal length of what appears to be Fallopian tube on that side, the diagnosis of one-horned uterus may be made. An unusually broad uterus, with unindented fundus, may be a uterus septus (Fig. 19); and if two cervixes are present (Fig. 20), the diagnosis is certain. When a definite indentation is felt in the middle of the fundus, a uterus bicornis is indicated (Fig. 21); but in practice it is likely that the two halves will be found unequally developed, and that the larger will be diagnosed as uterus and the smaller as an ovarian tumour or pedunculated fibroid. Here, again, the presence of two cervixes (Fig. 22) would make the diagnosis easy. The third type of double uterus, the Didelphys, is so far easy of recognition, in that the cervixes are always distinct; and the two halves of the uterus can usually be demonstrated as independently mobile (Fig. 23). The recognition of these malformations will be facilitated by remembering their leading features as shown in the accompanying diagrams.

Having settled the question of the size and shape of the uterus, we turn to its position. If the fundus can be felt in front of the cervix, the position is normal; if the fundus is felt behind the cervix, it is a case of retroversion. The fundus may, of course, be both retroverted and enlarged,

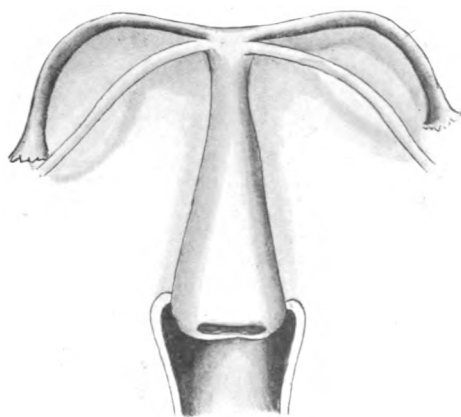


FIG. 16.—RUDIMENTARY UTERUS.

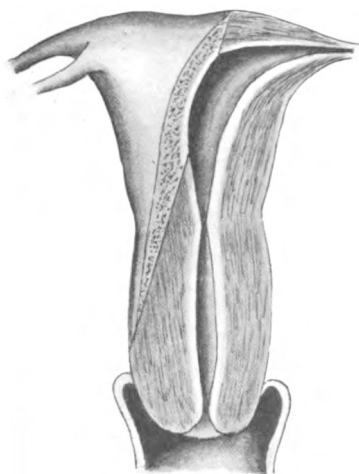


FIG. 17.—INFANTILE UTERUS.

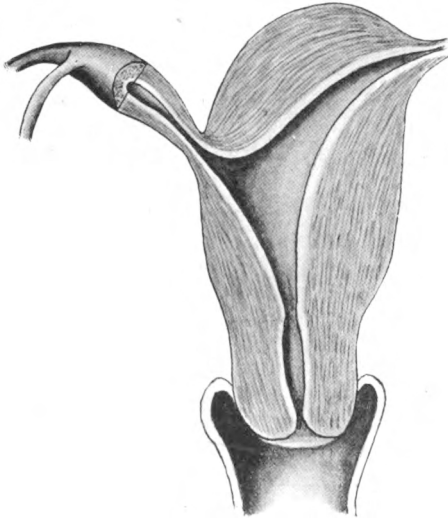


FIG. 18.—UTERUS UNICORNIS.

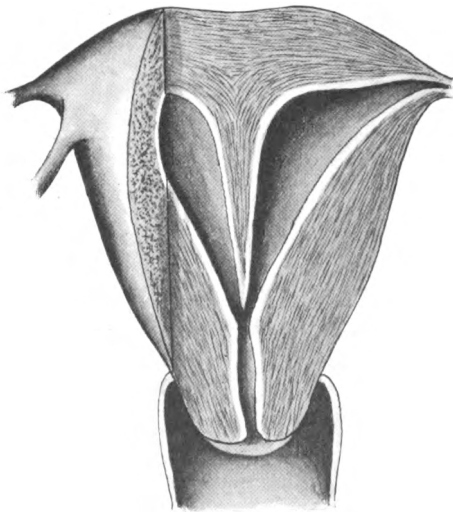


FIG. 19.—UTERUS SEPTUS UNICOLLIS.

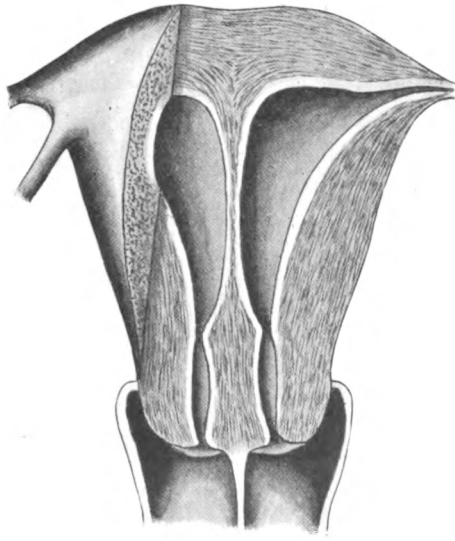


FIG. 20.—UTERUS SEPTUS.

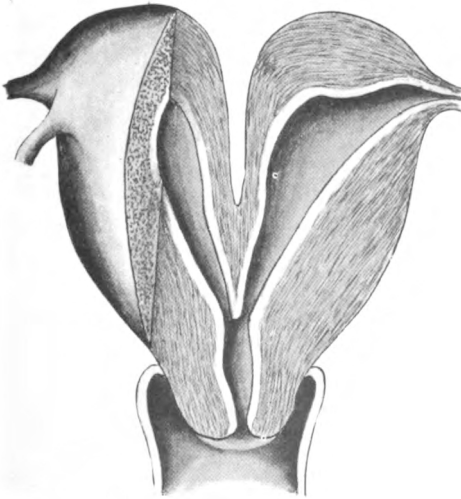

FIG. 21.—UTERUS BICORNIS UNICOLLIS.

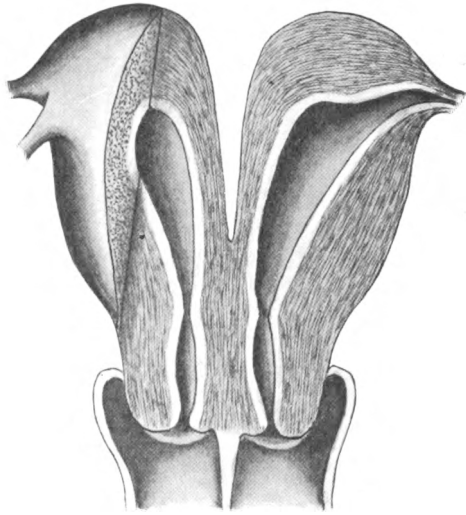


FIG. 22.—UTERUS BICORNIS.

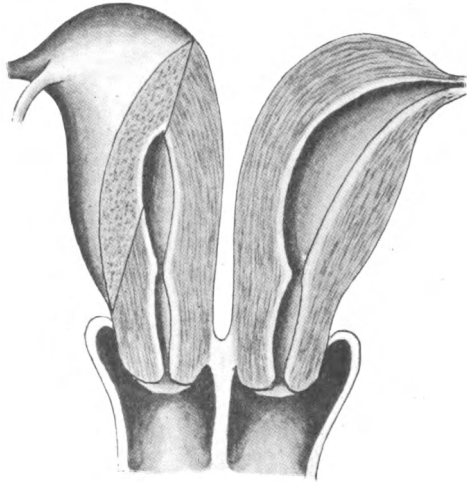


FIG. 23.—UTERUS DIDELPHYS.



## The Interpretation of Physical Signs 77

in which case we have to do with fibroids, or retroversion of the gravid uterus. These conditions will require to be differentiated from other swellings found in the pouch of Douglas; and this leads us to the consideration of swellings felt around the cervix and vagina.

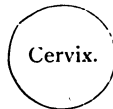For our present purpose we may regard the cervix as the central point in the pelvis, and the swellings that may be found around it may be represented as follows :

*In front (in the Uterovesical Pouch).*

Fundus of the uterus.  
Fibroids of the uterus  
or round ligament.  
Small ovarian tumour.  
Hydro- or pyosalpinx.  
Tubal pregnancy.  
Fœtal head *in utero*.  
Pelvic abscess.  
Stone or foreign body  
in the bladder.

*On the Right Side.*

Ovarian tumour.  
Broad ligament cyst.  
Diseased tube.  
Tubal pregnancy.  
Uterine fibroid in  
broad ligament.  
Broad ligament  
fibroid.  
Pelvic cellulitis.  
Pelvic abscess.  
Appendix abscess.



*On the Left Side.*

Ovarian tumour.  
Broad ligament cyst.  
Diseased tube.  
Tubal pregnancy.  
Uterine fibroid.  
Broad ligament  
fibroid.  
Pelvic cellulitis.  
Pelvic abscess.  
Carcinoma of sig-  
moid.

*Behind (in the Pouch  
of Douglas).*

Normal uterine fun-  
dus.  
Gravid uterine fundus.  
Fibroid tumour.  
Ovarian tumour.  
Diseased tubes.  
Tubal gestation sac.  
Pelvic hæmatocele.  
Pelvic abscess.  
Fæcal accumulation  
in rectum.  
Distended intestines.

The interpretation of a swelling found in the pelvis is simplified if we remember that all swellings fall into one or other of four distinct groups :

1. Intra-uterine pregnancy.
2. Extra-uterine pregnancy.
3. Inflammatory swellings.
4. Tumours.

The first thing, therefore, is to determine whether or not the patient is pregnant ; and in most cases this is easily settled by a careful consideration of the history and the physical signs. When the symptoms point to pregnancy, and there is a single swelling in the pelvis (namely, the uterus), the pregnancy is intra-uterine. With symptoms of pregnancy, relatively little enlargement of the uterus, and a swelling apart from the uterus, the probability is that it is a case of tubal pregnancy.

If pregnancy can be excluded, the sound will assist, if necessary, in determining where the uterus is, and whether any given swelling in the pelvis is uterine or not ; and the next question to settle is whether the swelling is inflammatory or a new growth. If the patient shows a rise of temperature, the swelling is due to pelvic cellulitis, pelvic abscess, pus-tubes, appendix abscess, or to inflammatory changes supervening in a fibroid or ovarian tumour, or in a tubal gestation sac.

The characteristic of pelvic cellulitis, or pelvic abscess, is a hard bulging mass in the lateral vaginal fornix ; and if the abscess be a large one, the swelling will extend up above Poupart's ligament. An appendix abscess is generally rather more remote from the uterus, but it may extend well down into the pouch of Douglas. Pus-tubes usually present an irregular outline, and are situated chiefly behind and to the sides of the uterus. The fact that the

tumour is uterine will lead to a diagnosis of inflamed fibroids. An inflamed ovarian tumour may be difficult to diagnose unless the existence of the tumour was known before the onset of the inflammatory changes; but a defined outline is in favour of an ovarian tumour rather than an abscess in the cellular tissue. An inflamed gestation sac will present the characters of pelvic inflammation super-added to the symptoms and signs of tubal pregnancy.

Lastly, in the absence of pregnancy and of inflammatory conditions, a pelvic swelling is probably a tumour, either uterine or ovarian, or arising in the uterine ligaments. It is to be remembered, however, that chronically diseased tubes may be present without rise of temperature, not only in cases of hydrosalpinx, but also in cases of pyosalpinx.

In distinguishing between uterine (fibroid) and ovarian tumours, certain generalizations are useful, although they are not invariably reliable, thus :

If the tumour is connected with the uterus, it is a fibroid; but an ovarian may be so intimately adherent to the uterus as to give the impression of being part of it.

A hard tumour is generally a fibroid of the uterus; but it may be a solid tumour, and even a fibroid, of the ovary, or a fibroid of the round or broad ligament.

A tumour separate from the uterus is generally ovarian; but it may be a pedunculated fibroid.

A soft cystic tumour is generally ovarian; but it may be a soft or even a cystic fibromyoma.

The last generalization we may make is this :

A tumour associated with amenorrhœa is pregnancy.

A tumour associated with uterine hæmorrhage is a fibromyoma.

A tumour with unaltered menstruation is an ovarian tumour or an outlying uterine fibroid.

To this generalization there are several exceptions. Thus, pregnancy may be combined with an ovarian or a fibroid tumour in such a way that menstruation may be suppressed, or unaltered, or replaced by irregular hæmorrhage; and uterine hæmorrhage is sometimes present in the case of an ovarian tumour, especially if it is malignant.

The lesson to be learned from the diagnosis of pelvic swellings is that in many cases the diagnosis cannot be made with any certainty; no pathognomonic signs are of avail in the diagnosis of particular conditions; and the only course open is to make a careful study of all the symptoms and signs present and deduce therefrom the diagnosis which is most in harmony with the complete picture of the case.

**5. The Speculum Examination.**—The speculum gives information concerning the vagina and cervix. In a great measure this information is merely a corroboration of what has already been discovered by the digital examination.

The inspection of the vaginal walls is best carried out by means of a Sims's or Neugebauer's speculum introduced first posteriorly to show the anterior vaginal wall, and then anteriorly to show the posterior. An unusual redness is an indication of vaginitis. The redness may be diffused, like an erythema of the skin, or it may be markedly punctiform. The latter form is generally associated with a copious purulent discharge, and is characteristic of an acute vaginitis, such as results from gonorrhœa.

A small, irregular, scarred depression in the vaginal wall often means that there is a fistula, communicating with bladder, urethra, or rectum; a small probe will generally serve to clear up the matter. In doubtful cases a cotton-wool swab should be left in the vagina for a time;

if a fistula be present, a fæcal or urinous odour will be detected on it, or it may become distinctly moistened with urine. Or, in a case of suspected bladder fistula, sterilized milk may be injected into the bladder and the fistulous opening watched through a speculum.

The presence of a tumour or cyst, or remnants of vaginal septa, will be noted.

The various pathological conditions of the cervix, as seen through the speculum, will be best understood by a reference to the accompanying figures (24 to 35).

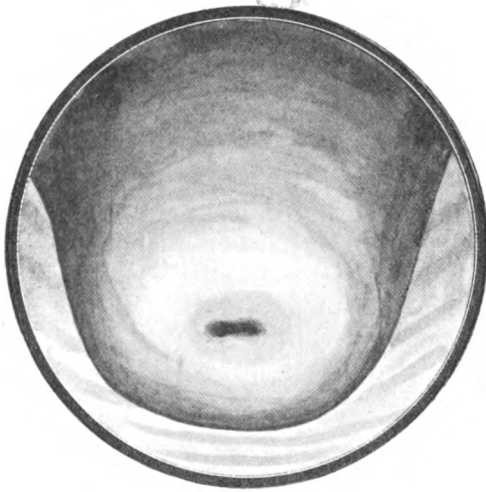


FIG. 24.—THE NORMAL NULLIPAROUS CERVIX.

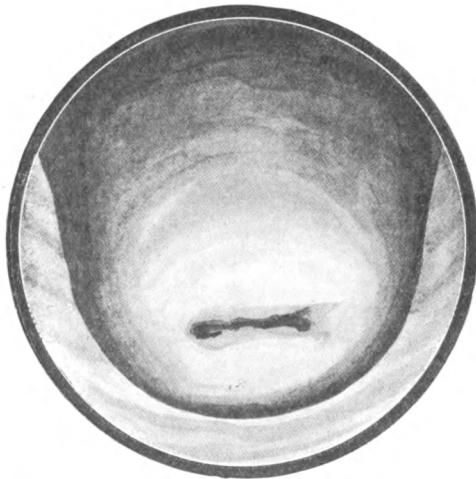


FIG. 25.—THE NORMAL PAROUS CERVIX.

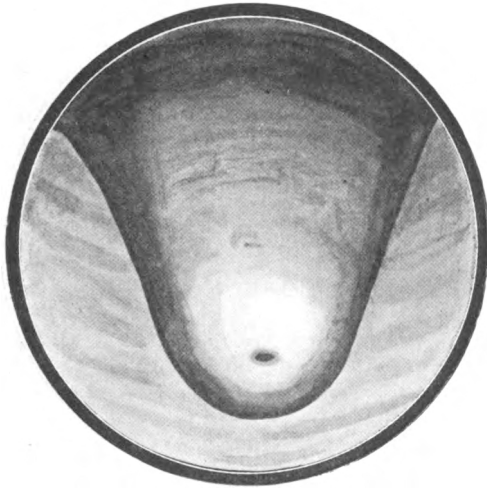


FIG. 26.—CONICAL CERVIX WITH PINHOLE OS.

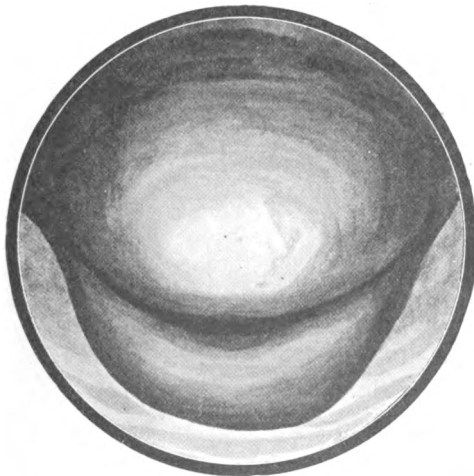

FIG. 27.—BILATERAL LACERATION OF THE CERVIX.

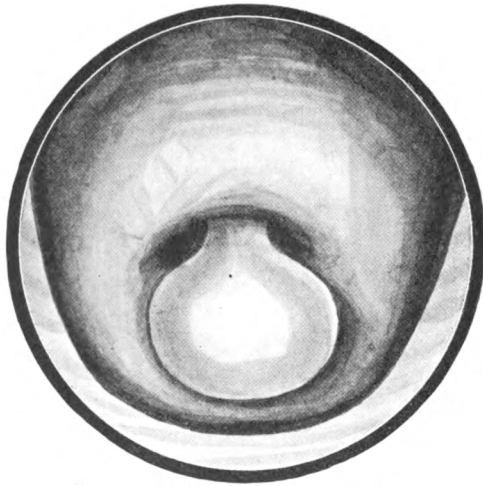


FIG. 32.—MUCOUS POLYPUS OF THE CERVIX.

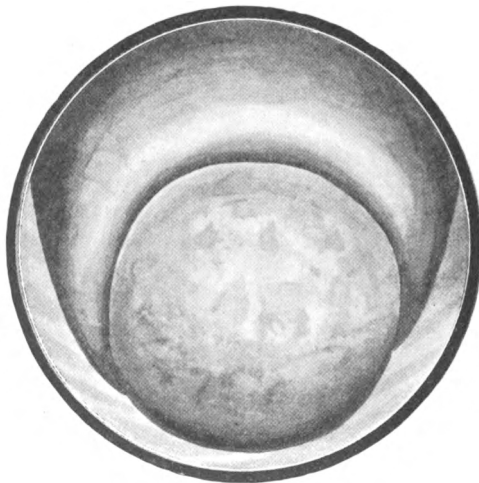


FIG. 33.—FIBROID POLYPUS OF THE CERVIX.



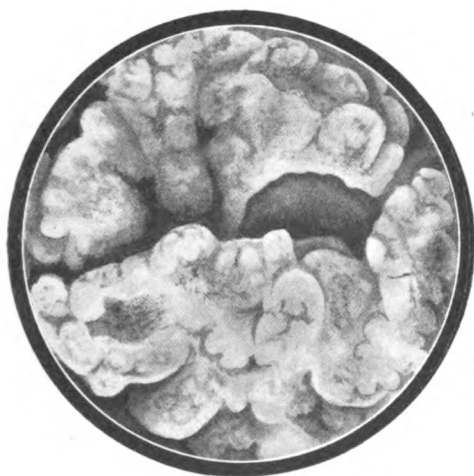

FIG. 34.—CARCINOMA OF THE CERVIX.

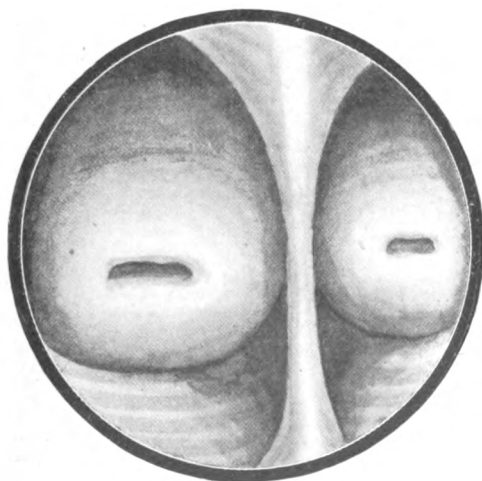


FIG. 35.—DOUBLE CERVIX.



PART II  
THE DIAGNOSIS OF INDIVIDUAL CASES



## CHAPTER VIII

### LEADING SYMPTOM: AMENORRHŒA

THE plan of the present work, as previously stated, is to start from symptoms, as they may be detailed by the patient, and to pass on from symptoms through signs to diagnosis. To facilitate description on my part and reference on the reader's, I shall take in succession the leading and prominent symptoms complained of in gynæcological cases. I shall then consider the various associated symptoms met with in each group, trace their significance, and review the corresponding physical signs met with on examination. In this way the diagnosis will be reached, sometimes directly and sometimes by a process of elimination. I shall not conceal or veil the fact that in many cases finality in diagnosis is not possible, for experience teaches that only the young and inexperienced can invariably make a positive and dogmatic diagnosis. After making some thousands of pelvic examinations one arrives at the conclusion that in some cases the most careful elucidation of symptoms and the most patient examination will fail to distinguish between two or three possible conditions present; this is especially the case when dealing with pelvic and abdominal tumours and swellings. The number of uncertain cases will be reduced by resorting to examination under an anæsthetic; but at times the actual con-

dition is not evident, even when the abdomen is opened, and therefore one must not be surprised or discouraged if the case cannot always be cleared up before we have this aid to diagnosis.

Patients complaining of amenorrhœa fall naturally into two groups—those who have not started menstruation and those who have stopped. The amenorrhœa is, accordingly, primary or secondary.

**GROUP I—Primary Amenorrhœa.**—These patients are nearly always young girls under twenty years; occasionally we meet with one of twenty to twenty-five; whilst there are rare cases in which the patient has attained middle life or passed the climacteric age without menstruating. With a patient over twenty, and especially over twenty-five, we can be virtually sure, even without examination, that she is the subject of under-development or malformation.

(a) Take it that our patient is under twenty. Has she any associated symptoms? It may be that she complains of shortness of breath when walking or going upstairs; of nausea or sickness after food; of constipation; and examination of the conjunctiva and of the blood shows that she is the subject of anæmia. Or she presents the symptoms and physical signs of tuberculosis or of myxœdema. We know that anæmia, tuberculosis, and myxœdema lead to amenorrhœa, and sometimes, by delaying puberty, to primary amenorrhœa. We are justified, in the case of an unmarried girl, in making a diagnosis without examination; if the latter should be deemed necessary, from the point of view of prognosis, it can be carried out under anæsthesia, when, in all probability, the pelvic organs will be found to be normal. The diagnosis is *amenorrhœa of constitutional origin*.

(b) Next, we have cases in which there are no associated

symptoms. The girl both feels and looks quite well, but the mother is anxious, because she thinks that at her daughter's age menstruation should have started. Again, we are justified in making a provisional diagnosis without examination. But it may be that marriage is contemplated, and an examination is requested in order to know whether there is any obstacle to marriage. Examination shows that the pelvic organs are normal. The diagnosis is, *delayed puberty*.

On the other hand, examination may show that the uterus is decidedly smaller than it should be; or that it is so small as to be merely rudimentary; or that there is some gross malformation, such as absence of the uterus, or pseudo-hermaphroditism. In the latter case the patient may have a feminine appearance, and be the possessor of a vagina, and perhaps a small uterus; she may have a swelling in one or both groins, which operation and microscopic examination demonstrate to be a testicle. Such a patient is in reality a male, and the absence of menstruation is amply accounted for. The diagnosis is, *under-development or malformation*.

(c) Another type of patient is free from any constitutional disease, but presents associated symptoms in the form of menstrual molimina, or periodic pain, or both.

By 'molimen' we understand the collective group of subjective feelings that usually accompany menstruation occurring in the absence of menstrual flow. These feelings include lassitude, heaviness, fulness or tenderness in the breasts, aching in the lower abdomen and thighs, and perhaps headache and nausea. The aching may be of such a character as to deserve the name of pain, and in marked cases the pain is severe. If these symptoms have been going on for many months, the pain may become

constant, instead of being merely periodic. The general health is probably quite good, until the pain becomes severe or chronic.

On examination, we shall find that there is atresia of some part of the genital canal. It may be the so-called, but misnamed, atresia of the hymen, which is properly described as atresia of the vagina. The obstruction may be quite at the outlet, in which case the space between the urethra and perineum will be found bulging downwards; or appearances may suggest that the lower part of the vagina is patent, and that its middle or upper part is impervious.

Abdominal examination shows nothing in early cases; but when symptoms have been going on long, a tumour is likely to be felt rising out of the pelvis. It is due to distension of the vagina (*hæmatocolpos*) pushing up the uterus, or to participation of the uterus in the distension (*hæmatometra*). Exact palpation in a thin subject, when the case is of long standing, may allow the practitioner to ascertain that the tubes present irregular sausage-shaped swellings at the sides of the fundus (*hæmato-salpinx*).

On rectal examination, a fulness is felt in front of the rectum; it extends low down when the atresia is at the vaginal orifice; but when the obstruction is higher up, the lower part of the pelvis feels clear, and, on bimanual examination, a swelling is felt higher up, the size of which will depend on the duration of the case. The diagnosis is *retained menstrual products (cryptomenorrhœa)*.

GROUP II — **Secondary Amenorrhœa.** — Patients in this group are necessarily within the age-limits of the period of reproductive maturity—that is, from fifteen to fifty. The age in these cases, however, has no important bearing on diagnosis. Our inquiries, in the first instance,



will be guided by the consideration whether the patient is single or married.

Supposing the patient is single; what associated symptoms are there to help us?

(a) It may be that she presents symptoms of anæmia, tuberculosis, or myxœdema, like the patient with primary amenorrhœa (Group I., a). We shall find, on inquiry, that menstruation has always been rather scanty, and that it became gradually less, until it ceased altogether. Or there is a history of some recent acute illness, such as typhoid, scarlatina, pneumonia, or acute tuberculosis; we know that such an illness is liable to be followed by anæmia of several months' duration. There is no need for a pelvic examination; we may assume that the organs are normal.

Or the patient may be the subject of chronic morphinism, with pin-point pupils, shifty, disingenuous gaze, restlessness, mental and moral instability; perhaps she admits that she is addicted to the drug, and she may state that when she menstruated she had severe pain, and began to take morphia on that account. In all these cases the diagnosis is *amenorrhœa of constitutional origin*.

(b) The patient presents no general symptoms; menstruation has always been scanty, and irregular, with longer intervals than is usual; and now it has been absent for three or six months, or perhaps longer. If there is any indication for an examination, we may find the uterus apparently normal; more probably it is rather small. If the ovaries can be palpated, we find that they are small. The vulva is probably rather small, and the pubic hair scanty. The diagnosis is, *defective ovulation, or underdevelopment*.

(c) Here is a definite and, unfortunately, not infrequent type. An attractive-looking young woman of twenty to

twenty-five complains of cessation of menstruation. She states that her periods previously were regular and normal in quantity, and that they were unaltered until they ceased abruptly; also, she gives the date of the last menstruation without uncertainty. (Both these features are very characteristic.) She finds that she has been getting larger in the abdomen; and it may be that she has been sick, especially in the mornings, and complains of tenderness in the breasts. Examination of the latter reveals a dark pigmented areola, and if the amenorrhœa is of more than four months' duration, some fluid can be expressed from the nipples by gentle pressure. On examination of the abdomen, a swelling is felt in its lower portion. Vaginal examination shows that the hymen is not intact; and that the uterus, bimanually, is enlarged, and feels like a pregnant uterus corresponding in size to the duration of the amenorrhœa.

The patient may, of course, be under twenty or twenty-five; she may be plain, instead of attractive; she may be poor, or in a good position; a street-walker, or a Sunday-school teacher; for this type embraces all sorts and conditions of women. The diagnosis is *pregnancy*.

(d) A patient aged forty-five to fifty has had amenorrhœa for some months. She states that the periods have been irregular ('dodging' is the expression in the vulgar tongue) for one or two years. She has definite associated symptoms, viz., flushes of heat followed by subjective feelings of cold, and attacks of giddiness or faintness. She may tell us that she has been getting stouter. An examination is usually unnecessary, but if one is made, the uterus is found of normal size or rather small; the cervix is small; the vagina has become markedly narrowed and conical at its uterine end. The diagnosis is *the menopause*.

(e) A woman of thirty to forty, or perhaps younger,

comes with a history exactly similar to the preceding ; perhaps she adds that she has had some very severe illness or mental shock. Or the patient that we met with earlier, when we diagnosed secondary amenorrhœa from under-development, or defective ovulation, may return a year later, saying that she has still not menstruated. In either case the diagnosis is *premature menopause*.

(f) A rare kind of case is the following : A patient, probably over thirty, comes with a history of amenorrhœa of some six, nine, or twelve months' duration. Her general health is good, and she has none of the symptoms of pregnancy ; but her complaint is of pain in the abdomen, recurring or becoming worse at intervals which, she thinks, correspond with menstrual periods. She states that she underwent the operation of 'scraping' (curetting) some time before the periods ceased, or perhaps she had had a torn cervix repaired. As she has already been operated upon, there can be no objection to making an examination, and we then find that the vagina is patulous, and the uterus is definitely, it may be considerably, enlarged. If the degree of enlargement be that of a pregnant uterus after the corresponding period of amenorrhœa, the possibility of pregnancy in the case must suggest itself. Careful examination of the cervix, however, shows that the os externum has been practically effaced. This, together with the absence of symptoms of pregnancy, makes the diagnosis of pregnancy doubtful ; but nothing is lost by waiting, for two or three months if necessary, before coming to a conclusion. After the lapse of some time, or, it may be, even when the patient is first examined, it is found that the size of the uterus does not correspond with pregnancy as reckoned by the term of amenorrhœa. An attempt is therefore made to pass a sound ; after some difficulty, perhaps after evoking the aid of an anæsthetic,

we succeed, and at once there is a discharge of dark, treacly blood from the uterus. The diagnosis is *secondary hæmatometra*.

We have been considering amenorrhœa as it occurs among single women. Among married women exactly the same causes of amenorrhœa are operative, but there is a little difference in the frequency with which those causes are met with. Thus, amenorrhœa due to constitutional conditions or to defective ovulation occurs much more often among single women; in married women, on the other hand, amenorrhœa is very much more likely to be due to pregnancy; secondary hæmatometra is also more common in the married, because they are more liable to suffer from endometritis. To all women, married and single alike, there comes, of course, a time when the menopause puts an end to menstruation. There is one condition, however, which is practically restricted to married women, and the type of case is as follows:

(g) A patient comes to us stating that she has not menstruated since the last confinement, which took place twelve or eighteen months ago, or perhaps longer. She feels quite well, and has had no symptoms of recent pregnancy. She nursed her last baby longer than usual—it may be for a year and a half or even two years. She will almost certainly tell us that she has had a large family, although she is still only thirty-five to forty years of age. On examination, the vagina is normal, and does not present the conical narrowing of its deeper part that is so characteristic of the menopause. But the striking feature of the case is that the uterus is definitely under the normal size. The diagnosis is *premature menopause due to superinvolution*, probably contributed to by over-lactation.

SYNOPSIS OF CASES OF AMENORRHŒA.

Leading Symptom.	Associated Symptoms.	Physical Signs.	Diagnosis.
1. PRIMARY AMENORRHŒA	(a) Symptoms of anæmia, tuberculosis, or myxœdema (b) None (c) Menstrual molimina ; periodic or constant abdominal pain	Signs of anæmia, etc. ; pelvic organs normal (i.) Pelvic organs normal (ii.) Uterus small or rudimentary, ovaries small; or gross malformation Abdominal swelling ; vaginal atresia ; swelling in front of the rectum	Constitutional amenorrhœa Delayed puberty Under-development or malformation Cryptomenorrhœa (retained menses)
2. SECONDARY AMENORRHŒA	(a) Symptoms of anæmia, etc.; morphinism ; recent acute illness ; gradual cessation of menstruation (b) No general symptoms ; menstruation previously scanty and irregular (c) Abrupt cessation of menstruation ; sickness ; abdominal swelling (d) Recent irregularity of menstruation in a patient of forty-five to fifty ; flushes, faintings, etc. (e) The same symptoms in a woman under forty (f) Periodic abdominal pain ; history of recent endometritis ; curetting or trachelorrhaphy (g) None ; history of multiple pregnancies ; prolonged lactation	Signs of anæmia, etc., or weakness and emaciation from recent illness ; pelvic organs normal Under-development of vulva, uterus, and ovaries Physical signs of pregnancy Narrowing of vagina ; uterus normal or small Vagina narrowed ; uterus small Enlargement of the uterus ; atresia of external os Vagina normal ; uterus small	Constitutional amenorrhœa Defective ovulation or under-development Pregnancy Menopause Premature menopause Secondary hæmatometra (cryptomenorrhœa) Superinvolution (premature menopause)

## CHAPTER IX

### LEADING SYMPTOM : PAIN

I HAVE already, in Chapter V., given reasons for regarding pain as a symptom whose value varies greatly, and I may further remark here that the severity of pain is no criterion of the pathological gravity of a case. Nevertheless, we must remember that the patient is only faintly interested in the position assigned to her malady in the pathological scale of diseases ; but she is very acutely concerned in being relieved from her pain or other symptoms. It is therefore necessary to make a careful study of cases of pain, and for this purpose I shall adopt as a clinical basis the classification outlined in Chapter V. We start, then, with the assumption that a patient comes complaining of pain.

**I. The Pain is Periodic.** We note that periodic pain is of three types, according as it is (*a*) menstrual, (*b*) intermenstrual, (*c*) characterized by a monthly rhythm in the absence of menstruation.

**A. MENSTRUAL PAIN, OR DYSMENORRHŒA.**—When we say that a patient is suffering from dysmenorrhœa, we have not made a diagnosis, because dysmenorrhœa is but a symptom. In the case of young girls, it is permissible to go no further, and simply treat the dysmenorrhœa symptomatically. For our present purpose, however, it

is necessary to try to elucidate the cause of the dysmenorrhœa. So we shall inquire whether the pain is general—that is, affecting the back, hypogastrium, and thighs—or whether it is distinctly lateral.

(a) *The Pain is General.* Are there any associated symptoms?

(i.) In one type there are no associated symptoms. The patient is perfectly well except for the monthly pain, and on examination the pelvic organs appear to be quite normal. Therefore, by exclusion, and for want of more exact knowledge of the nervous or trophic conditions which may induce painful uterine contractions, our diagnosis must be *dysmenorrhœa of constitutional origin*.

(ii.) In the next type the patient, if married, is sterile, and her dysmenorrhœa is severe. She may or may not present the characteristics of neurosis. On examination, the cervix is rather long and conical, with a 'pinhole' os, and there is marked ante flexion. The diagnosis is *under-development of the type associated with stenosis and ante flexion*.

(iii.) Another patient states that she suffers habitually from leucorrhœa, and the period is attended by profuse loss as well as pain. On examination, we find either (a) that the uterus is bulky and heavy, with a congested appearance of the cervix and vagina, when the diagnosis will be *uterine congestion*; or (β) that the uterus lies low down in the pelvis, the cervix presenting near the vagina, or that it lies with the fundus retroverted. The diagnosis is *uterine displacement*.

(iv.) The patient complains of menorrhagia as well as dysmenorrhœa. The discharge is not white (leucorrhœa), but yellow (xanthorrhœa). She suffers habitually from lassitude and backache. On examination, the cervix is adenomatous and bulky, muco-pus exudes from the

external os, and the uterus is enlarged. The diagnosis is *endometritis*.

(v.) In yet another type in this series menstruation is profuse and prolonged. The patient complains of frequency of micturition, which is worse during menstruation, or is then replaced by retention of urine. She constantly suffers from a feeling of weight in the pelvis. On examination, the uterus is very hard, and so large that it fills up the pelvis. The diagnosis is *impacted uterine fibromyoma*.

(b) In the second main variety of dysmenorrhœa *the pain is distinctly lateral*, and is referred to one or other iliac region, or it may be *bilateral*. Inquiry into associated symptoms will reveal two types.

(i.) The patient has more or less habitual pain in the side. There may be pain on defæcation, and if the patient is married she suffers from dyspareunia. On examination, the uterus is normal, but on one or both sides the ovary is large, prolapsed, and very tender to manipulation. The diagnosis is *cystic and prolapsed ovary*.

(ii.) In the second type the patient gives a history of xanthorrhœa (perhaps definitely gonorrhœal). She suffers from menorrhagia, and is either sterile or has had no children for some years. On examination, the uterus is more or less fixed on each side, and extending behind the uterus is a tender swelling. We may be able to make out definite thickening of the tubes. The diagnosis is *salpingitis* or *pyosalpinx*.

B. INTERMENSTRUAL PAIN.—This is the second variety of periodic pain. It is sometimes (unnecessarily) called by its German equivalent, 'mittelschmerz.' The pain may be median or lateral. It recurs with a rather striking regularity ten to fourteen days after the cessation of a monthly period, and is apt to get gradually worse till the



next period comes on, and then relief comes with the menstrual flow. Our knowledge of this condition is incomplete. Some patients state that they have a definite watery discharge soon after the period comes on. On examination, the tubes have been found dilated in a certain number of cases. If such a condition is found, the diagnosis will be *tubal disease, with intermittent hydrosalpinx*. In some cases, however, physical examination reveals little or nothing, and we must remain content without a proper diagnosis, merely describing the case as one of intermenstrual pain.

(c) MONTHLY PAIN WITHOUT MENSTRUATION.—The patient in such a case is usually a girl or young woman. The pain is abdominal. If the symptoms have gone on for some time, an abdominal swelling is complained of. On examination, a fulness is felt in the lower part of the abdomen, persisting after the bladder has been emptied by catheter. The vulva presents a bulging membrane in the situation of the vaginal orifice, or the lower part of the vagina is patent, but there is atresia in some portion of the canal. The diagnosis is *cryptomenorrhœa due to atresia of the genital canal*.

Leaving now the consideration of periodic pain, we come to the second class.

2. **The Pain is Intermittent and Irregular.** This is a kind of pain frequently met with. It is situated in various parts of the abdomen, especially in the right and left hypochondriac and the right and left iliac regions, but it is never constantly in one place. The patient admits, if questioned, that she suffers greatly from flatulence and constipation; and states that she often experiences inframammary pain. Patients of all ages come with this history; but the majority are over forty, and many are approaching the menopause.

Now, the important point to remember is that these pains do not originate in the pelvis, and are independent of any condition of the uterus and its appendages. These are the cases to which I alluded at the beginning of Chapter V. They are not vague gynæcological cases; they may be vague, but they are not gynæcological. *A priori* they are not gynæcological, because the area of referred pain due to pelvic conditions is below the level of the umbilicus; and as a matter of practice, we find on examination that the pelvic organs are normal in the great majority of cases. The diagnosis, therefore, is *flatulent dyspepsia and constipation*.

3. **The Pain is Chronic**—that is, frequent or constant—and it affects the lower abdomen. The first step in diagnosis is to ascertain whether the pain is sacral; hypogastric; general, affecting the hypogastrium, sacrum, pelvis, and thighs; or distinctly lateral.

(a) *The Pain is Sacral, Hypogastric, or General.* Backache is, of course, a very common symptom in women; and, taken by itself, it is in no sense pathognomonic. Speaking broadly, it is indicative either of general lack of tone, with lassitude and want of energy, or of pelvic congestion, pelvic inflammation, prolapse of the pelvic organs, or backward displacements of the uterus. It may be present alone, or combined with hypogastric and general pelvic pain and bearing down; or, again, the hypogastric pain and weight may be the principal feature. We must now try to analyze the cases a little further.

(i.) Pain is chiefly sacral, and occasionally hypogastric; menstruation is normal, and there is no leucorrhœa. The patient complains that she is lacking in energy, gets easily tired, and cannot walk far; her occupation may involve a good deal of standing. (a) On examination, the

pelvic organs are normal. The diagnosis is *general debility*. (β) With precisely similar symptoms, we may find on examination that the uterus is lying backwards, with the fundus in the hollow of the sacrum. This may quite well account for the symptoms, and the diagnosis is *retroversion of the uterus*.

(ii.) The pain affects the lower abdomen and back ; the lassitude and tiredness are as before. Menstruation is normal, but the patient complains of leucorrhœa in greater or lesser degree. It may be that she has been married a year or less. On examination, the vagina feels hot, the uterus is heavy, and the cervix, as seen through the speculum, looks congested. The diagnosis is *uterine congestion*, and inquiry may allow us to draw the further conclusion that the cause is want of moderation in marital relations.

(iii.) In addition to the above symptoms, there is a feeling of weight and bearing down in the pelvis ; menstruation may be normal, or excessive in quantity ; the discharge is white or yellowish. On examination, we may find the uterus bulky, but in normal position, the cervix in a condition of 'erosion,' with perhaps an old laceration, and muco-pus exuding from the external os ; or the uterus is markedly retroverted ; or it is lying low in the pelvis in a position of prolapse and even of procidentia, with perhaps some bulging of the vaginal walls. In rare cases, with an almost exactly similar history, we may find the uterus completely inverted. The diagnosis will be, according to the condition found, *endometritis*, *retroversion*, *prolapse*, or *chronic inversion of the uterus* ; or there may be a combination of two or more of these conditions.

(iv.) The patient complains of general pain and aching in the lower abdomen and a sense of fulness in the pelvis ;

the tiredness and lassitude presented in the other cases are not conspicuous features here ; menstruation is unaltered, or it may be excessive, and there may be intermenstrual hæmorrhage as well ; leucorrhœa may or may not be present. There is frequent desire for micturition ; at times, especially at the onset of menstruation, there may be retention of urine, and in that case we may find that all the symptoms are accentuated at the monthly periods. There may be constipation or pain during defæcation. On examination, the pelvis is found to be occupied by a swelling, which appears to completely fill it. The diagnosis is *impacted pelvic tumour*. It may be possible to push the diagnosis a step further : thus, if the tumour is very hard and obviously uterine, we may safely say it is a *fibroid*, and this diagnosis is confirmed if the patient complains of loss of blood with the periods or in the intervals. If the tumour is situated actually in the vagina, it is almost certainly an *intra-uterine fibroid* that has been partially or wholly extruded through the external os. If the uterus can be felt apart from the tumour, and the latter is tense and cystic, it will probably prove to be an *ovarian tumour* ; but it may also be a *pedunculated fibrocystic tumour*. If the tumour is hard, smooth, and rounded, it is probably a *pedunculated fibroid* ; and if hard and irregular, it may be either a fibroid or a *solid ovarian tumour*, perhaps carcinomatous.

(v.) There may be only moderate pain complained of, but the most distressing thing is inability to pass water for the last day or two ; this was preceded for some days by frequency of micturition. There has been amenorrhœa of three to four months' duration, the periods being previously regular and of normal character. The patient may or may not have been sick, especially in the mornings, for two months. On examination of the abdomen, a

cystic ovoid swelling can be felt extending from the pubes to the umbilicus: we may conclude that this is the distended bladder, and the diagnosis is confirmed by passing a catheter. By the vagina, the cervix is found high up and behind the pubes, being evidently pushed forward by a mass behind it, filling up the pelvis. The breasts contain a milky secretion. The diagnosis is *retroversion of the gravid uterus*, and it is confirmed by the fact that, after drawing off the urine with a catheter, the uterus can be pushed up into the abdomen by gentle, steady pressure applied through the vagina. If it be found impossible to push up the mass behind the cervix, the possibility of its being a case of *extra-uterine pregnancy* should be borne in mind, because in some cases the symptoms and signs of this condition have almost exactly simulated those of retroversion of the gravid uterus. Careful bimanual examination should then be undertaken, under an anæsthetic if necessary, to determine whether the body of the uterus can be felt, only slightly enlarged, above the pubes and independent of the mass in the pelvis. This would settle the diagnosis in favour of extra-uterine pregnancy.

(vi.) In this type of case there is general pain in the pelvis, radiating from it and going down the thighs. The patient complains of irregular hæmorrhages, which may be almost constant, and also of a watery, sanious, and bad-smelling discharge. She has lost flesh. She may be any age from thirty to sixty, but is probably about forty to fifty. On examination, the patient looks pale and cachectic, and is perhaps emaciated. By the vagina, the cervix is found to be the seat of a ragged, excavating ulcer, or of a proliferating irregular mass, infiltrating the vaginal walls. The diagnosis is *advanced carcinoma of the cervix*.

(b) *The Pain is Lateral*, situated in one or both sides of the pelvis.

(i.) In the simplest type the pain is commonly on the left side; it is usually mild, but is aggravated by intercourse and during defæcation; the patient is the subject of constipation or flatulence, but is otherwise in good health. On examination, the uterus is normal; the right side is clear, and free from tenderness; on the left side the ovary can be readily defined, slightly enlarged and prolapsed and exceedingly sensitive to pressure. The diagnosis is *oöphoritis*, aggravated by pressure of the loaded sigmoid, due to constipation.

(ii.) There is a type in which the pain is more severe, and may be on the right or left side, or both. Dyspareunia is so great that intercourse has been abandoned. Constipation may or may not be a feature of the case. On examination, the ovary on one or both sides is markedly prolapsed, enlarged to the size of an egg or larger, and very tender. The uterus may be retroverted. The diagnosis is *prolapsed, cystic, and inflamed ovary*.

(iii.) Here the pain is definitely on one side. The last normal menstruation was three or four months ago; for the last six or eight weeks there has been a scanty, discoloured (brownish) discharge. The pain dates from the time when the discharge began and set in with an attack of faintness. The patient thought that she was pregnant. On examination of the breasts, there is a little secretion; vaginal examination shows that the uterus is a little enlarged, and is pushed over to one side; on the other side (the side to which the pain is referred) there is a swelling, fairly defined, somewhat ovoid, the size of a lemon, or a little larger, and perhaps extending behind the uterus. The diagnosis is *extra-uterine pregnancy*.

(iv.) The pain is bilateral, though more marked on one side. It dates from shortly after an attack of vaginitis, probably gonorrhœal: a yellowish discharge has continued. Menstruation has been increased in quantity for some months. On examination, the uterus is fixed and tender; on each side the vaginal fornix is depressed, and an irregular or elongated tender swelling is felt. The diagnosis is *double tubal disease*, including in this term salpingitis, hydrosalpinx, pyosalpinx, tubo-ovarian cyst, and tubo-ovarian abscess.

4. **The Pain is Acute.** We may divide cases of acute pain into two categories, according as the onset is sudden or gradual.

A. THE ONSET IS SUDDEN. A further subdivision is supplied by the situation of the pain.

(a) *Pain in the Back.*—The pain is severe and accompanied by a feeling of bearing down; it has probably come on as the result of a fall or a sudden strain. The patient has previously had no pelvic trouble; menstruation is normal, and she has no leucorrhœa. On examination, the uterus is found markedly retroverted, and the rest of the pelvic organs are normal. The diagnosis is *acute retroversion of the uterus*.

(b) *Pain in the Abdomen.*—(i.) The pain is hypogastric and rhythmic; it passes off for some minutes, or perhaps an hour, and then comes on again, and is described as being 'like labour pains.' There is a history of several months' amenorrhœa; but the onset of the pain has probably been accompanied by more or less loss of blood, perhaps by a flooding. On examination, the uterus is enlarged to the size of a pregnant uterus, corresponding with the term of amenorrhœa; the os is partially dilated; the appendages are normal. The diagnosis is *threatened abortion*.

(ii.) The pain is diffused over the abdomen, and its onset was marked by a certain amount of shock. There is no history of menstrual irregularity, but the patient states that she has suffered from swelling of the abdomen. On examination, the abdomen is found to contain free fluid, and is generally tender; there are no signs of internal hæmorrhage; a definite swelling may be found low down in the abdomen, arising out of the pelvis. On vaginal examination, the uterus is normal; there is, perhaps, some resistance, or a definite swelling, on one or other side of it. The diagnosis is *ruptured ovarian cyst*.

(iii.) The pain has come on with marked shock, and with uterine hæmorrhage, and a feeling of something passing: the patient has been confined only a day or two, or perhaps only a few hours. On examination of the abdomen, the proverbial 'cricket ball' feeling of the uterus is absent, and, in fact, the uterus cannot be felt at all. On vaginal examination, a ragged, vascular, bleeding tumour is found presenting at the vulva, or lying outside it, with a narrowest portion passing up into the vagina; the uterine ostia of the Fallopian tubes can be made out on the most prominent part of the tumour. The diagnosis is *acute inversion of the uterus*.

(c) *Lateral Abdominal Pain*.—(i.) The onset of the pain has been associated, or very soon followed, by vomiting, and some collapse. Even if the case has gone on for several days, the vomiting does not become fæcal, and there is no intestinal obstruction. There is no history of menstrual irregularity. The temperature is normal, or slightly raised. On examination of the abdomen, which is tender, a tense rounded tumour can be felt, situated laterally. Bimanual examination shows that the uterus is normal in size, and independent of the tumour. There



are no signs of hernia. The diagnosis is *ovarian tumour with a twisted pedicle*.

(ii.) The pain has come on with shock and collapse, but without vomiting. The patient has missed one or two monthly periods; but there has been a slight loss of blood from the vagina since the pain started. On examination, the patient presents the appearance of having internal hæmorrhage; she is blanched, restless, and breathing in deep sighing fashion; the pulse is very quick, thready, and running. On examination of the abdomen, there is some resistance in one iliac fossa; the flanks may be dull. Vaginal examination shows a swelling on one side of the uterus; the pouch of Douglas offers a soft, vague resistance. The diagnosis is *ruptured tubal pregnancy*.

B. THE ONSET HAS BEEN GRADUAL. Broadly speaking, acute pain that has come on gradually points to inflammatory conditions. The following types are met with:

(a) The pain is referred to the vagina and vulva. It was preceded by a yellow thick discharge, and accompanied by burning pain during and following the passing of water. On examination, the vulva is reddened; a purulent or muco-purulent discharge escapes from the vaginal orifice. On pressing along the course of the urethra from within outwards, a drop of pus appears at the urethral meatus. Examination with a speculum shows that the vaginal walls are deeply injected with a punctiform reddening, and bathed in pus. The diagnosis is *gonorrhœa*.

(b) The pain is situated on one side of the vulva, and is so bad that the patient cannot sit down. There may be a yellow discharge, and the patient has noticed an external swelling. On examination, one labium majus is

occupied and distended by a pyriform swelling, the broader end of which is at the lower part of the labium. The diagnosis is *Bartholinian cyst*, or *abscess*. If there has been no xanthorrhœa, and if the skin covering it is pale, it is probably a cyst. With a history of yellow discharge, and redness of the skin over the swelling, it is probably an abscess.

(c) The pain is abdominal, and has been accompanied or followed by high temperature, and perhaps one or more rigors. There may be a history of a recent confinement. On examination, the temperature ranges from 101° to 103° F. The pulse is full and rapid; the tongue coated, furred, or brown and dry. The abdomen is distended, either generally, or at its lower part, and is very sensitive to touch. One of several conditions may be found on vaginal and bimanual examination.

(i.) The uterus is moderately fixed; the pouch of Douglas feels rather full and boggy, but there is no well-defined swelling. The diagnosis is *pelvic peritonitis*.

(ii.) The uterus is pushed up and forwards behind the pubes; a tense fluctuating swelling is felt behind it, bulging down into the posterior vaginal fornix. The diagnosis is *suppurative peritonitis* or *intraperitoneal abscess*.

(iii.) The uterus is pushed over to one side by a swelling which bulges down into the opposite lateral vaginal fornix, and which can be felt extending up towards the abdomen, and forming a swelling above Poupart's ligament, or right up into the iliac fossa. The diagnosis is *pelvic abscess*.

(iv.) The uterus is of normal size, and is displaced, either forwards, downwards, or to one side, by a well-defined rounded swelling, occupying the pelvis, or rising

up into the abdomen. The diagnosis is *suppurating ovarian cyst* or *circumscribed intraperitoneal abscess*.

(v.) On each side of the uterus the Fallopian tube can be felt thickened and elongated; the tube may be prolapsed behind the uterus, and lying in the pouch of Douglas. The diagnosis is *acute suppurative salpingitis with peritonitis*.

## SYNOPSIS OF CASES OF PAIN.

Leading Symptom.	Associated Symptoms.	Physical Signs.	Diagnosis.
<b>I. PERIODIC PAIN</b>			
<b>A. Menstrual</b> (a) General (hypo gastrium, sacrum, thighs, etc.)	(i.) None (ii.) Sterility; (neuroses) (iii.) Menorrhagia; leucorrhœa (iv.) Menorrhagia; xanthorrhœa; lassitude, backache (v.) Menorrhagia; weight in pelvis; frequency of micturition or retention of urine (i.) Habitual iliac pain; dyspareunia; pain on defæcation (ii.) Xanthorrhœa; menorrhagia; (sterility)	Pelvic organs normal Stenosis; ante flexion; conical cervix (a) Bulky and congested uterus (b) Uterus prolapsed or retroverted Uterus large; cervix adenomatous; muco-pus in vagina Uterus hard large, filling the pelvis Uterus normal; one or both ovaries cystic, tender, and prolapsed Uterus fixed; tubes thickened; or large tender swellings comprising ovaries and tubes (Tubes thickened or dilated) or negative	Constitutional dysmenorrhœa Stenosis and ante flexion Uterine congestion Uterine displacement Endometritis Impacted uterine fibroma Prolapsed, cystic, and inflamed ovaries Salpingitis or pyosalpinx (Intermittent hydrosalpinx); 'intermenstrual pain'; Cryptomenorrhœa from atresia of the genital canal
<b>B. Intermenstrual:</b> median or lateral	(Hydorrhœa) or none		
<b>C. Monthly pain, without menstruation; abdominal</b>	Subjective symptoms of menstruation; (abdominal swelling)	Vaginal atresia; (pelvic or abdominal tumour)	

## Leading Symptom : Pain

<p>2. INTERMITTENT AND IRREGULAR PAIN IN VARIOUS PARTS OF THE ABDOMEN</p>	<p>Flatulence ; constipation ; infammatory pain</p>	<p>Pelvic organs normal</p>	<p>Flatulent dyspepsia and constipation</p>
<p>3. CHRONIC PAIN (a) Sacral, hypogastric, or 'general</p>	<p>(i.) The pain is 'backache'; lassitude ; tiredness (ii.) Lassitude ; leucorrhœa (iii.) Lassitude ; leucorrhœa ; bearing down ; menstruation normal or excessive</p> <p>(iv.) Weight in the pelvis ; perhaps menorrhagia and leucorrhœa ; disturbances of bladder and bowels</p> <p>(v.) Retention of urine, preceded by frequent micturition ; amenorrhœa of three or four months ; sickness</p>	<p>Pelvic organs normal</p> <p>Uterus heavy ; cervix congested (a) Uterus large ; cervix adenomatous, perhaps lacerated ; muco-pus in vagina (β) Fundus of uterus lying backwards (γ) Uterus lying low in vagina or protruding through the vulva (δ) Uterine fundus lying inverted in the vagina</p> <p>(α) Large hard uterine tumour, filling the pelvis (β) Uterus normal ; hard, solid tumour displacing the uterus and filling the pelvis (γ) Uterus normal ; cystic, soft, or tense elastic tumour filling the pelvis (α) Uterus as large as three to four months' pregnant uterus ; fundus retroverted ; secretion in breasts ; ovoid tumour in lower abdomen (β) Mammary secretion ; tumour in lower abdomen ; uterus only slightly enlarged ; irregular doughy tumour filling the pelvis</p>	<p>General debility</p> <p>Uterine congestion Endometritis</p> <p>Retroversion of the uterus Prolapse or procidentia of the uterus Chronic inversion of the uterus</p> <p>Impacted uterine fibromyoma Impacted pedunculated fibroid or solid ovarian tumour Ovarian cyst or fibrocystic tumour</p> <p>Retroversion of the gravid uterus, with overdistended bladder</p> <p>Extra-uterine pregnancy</p>

SYNOPSIS OF CASES OF PAIN—*continued.*

Leading Symptom.	Associated Symptoms.	Physical Signs.	Diagnosis.
(b) Lateral	(vi.) Irregular hæmorrhage; watery, bad smelling discharge; emaciation (i.) Slight dyspareunia; pain on defæcation; flatulence (ii.) Severe dyspareunia (iii.) Brownish discharge; three or four months' amenorrhœa; faintings; pain is limited to one side (iv.) Menorrhagia and xanthorrhœa dating from an attack of vaginitis; dyspareunia; pain is bilateral.	Ragged ulceration of cervix; or proliferating bleeding cervical tumour Uterus normal; ovary slightly enlarged and very tender Uterus normal; one or both ovaries prolapsed, large, and tender Mammary secretion; uterus slightly enlarged; well defined swelling on the same side as the pain Uterus fixed; on each side is a tender swelling in the region of ovary and tube	Advanced carcinoma of the cervix Oöphoritis Prolapsed, cystic, and inflamed ovaries Extra-uterine pregnancy Chronic salpingitis, or pyosalpinx, or tubovarian cyst or abscess
4. ACUTE PAIN A. Sudden onset (a) Pain in the back (b) Pain in the abdomen	Bearing down; history of fall or strain (i.) Pain is hypogastric, rhythmic, like labour pains; amenorrhœa; (loss of blood) (ii.) Pain is general; slight shock at the onset; history of abdominal swelling.	Uterus markedly retroverted Uterus enlarged; cervix soft and dilated; appendages normal Free fluid in abdomen; no signs of internal hæmorrhage; uterus normal; some resistance or swelling on one side	Acute retroversion of the uterus Threatened abortion Ruptured ovarian cyst

<p>(iii.) Marked shock at the onset; recent confinement; hæmorrhage and a feeling of something passing</p>	<p>Fundus of uterus inverted in the vagina or outside the vulva</p>	<p>Acute inversion of the uterus.</p>
<p>(c) Pain on one side</p> <p>(i.) Onset associated with slight shock; vomiting; temperature normal or slightly raised; no intestinal obstruction</p>	<p>Abdomen tender; a tense, rounded tumour is felt bimanually on one side; uterus normal</p>	<p>Ovarian tumour with twisted pedicle</p>
<p>(ii.) Onset associated with marked shock and collapse; history of one or two months' amenorrhœa</p>	<p>Signs of internal hæmorrhage; free fluid in the abdomen; bimanually a laterally situated swelling; uterus slightly enlarged</p>	<p>Ruptured tubal pregnancy</p>
<p>B. Gradual onset</p> <p>(a) Pain in vulva and vagina</p> <p>(b) Pain one side of vulva</p> <p>(c) Pain in the abdomen</p>	<p>Purulent inflammation of vagina, cervix, and urethra</p> <p>Pyriform swelling in labium (skin over it reddened)</p> <p>(i.) No well-defined swelling</p> <p>(ii.) Tense fluctuating swelling behind uterus, bulging into vagina</p> <p>(iii.) Uterus displaced laterally; swelling on opposite side, bulging into vagina and extending up into the abdomen</p> <p>(iv.) Uterus displaced by well-defined suppurating swelling in the pelvis and abdomen</p> <p>(v.) Enlargement of the tubes</p>	<p>Gonorrhœa</p> <p>Bartholinian cyst (or abscess)</p> <p>Pelvic peritonitis</p> <p>Suppurative peritonitis</p> <p>Pelvic abscess</p> <p>Suppurating ovarian cyst</p> <p>Acute pyosalpinx</p>

## CHAPTER X

### LEADING SYMPTOM: HÆMORRHAGE

HÆMORRHAGE is one of the most important and significant of symptoms in gynæcology. In tracing out the many diverse conditions with which it is associated, it will be convenient to divide the cases into three principal groups, which can be readily differentiated—namely: (1) Hæmorrhage associated with menstruation; (2) hæmorrhage independent of menstruation; (3) hæmorrhage occurring during pregnancy.

#### 1. Hæmorrhage with Menstruation, or Menorrhagia.

—We must remember that many women habitually and normally have a considerable flow of blood during menstruation, and we should not, on that account, say that they suffer from menorrhagia. When we use this term, we imply that the patient has suffered, for a longer or shorter time, from an amount of loss which is greater than what is habitual with her. We may now proceed to consider the various types met with.

(a) The patient is a young girl who is still at the stage of early puberty. She presents no associated symptoms, and her general health is good. She has perhaps had only two or three periods, but they have been so profuse as to cause the mother some anxiety. Knowing that puberty is sometimes ushered in with several free periods,



we may legitimately refrain, in the first instance, from any examination, which would probably merely show that there was an intact hymen and normal pelvic organs. The diagnosis is *functional congestion of puberty*.

(b) The second type, which is rare, is a rather older girl—perhaps the same one whose case we have been considering, but seen at a later date. The periods have continued to be excessive, in spite of medicinal treatment, and the girl shows symptoms and signs of anæmia. The examination which is now called for is made under an anæsthetic, and we may find :

(i.) A small mucous polypus, projecting from the os externum, or a uterus rather larger than is normal at this age. On dilating the cervical canal, a small polypus is found in the uterine cavity. The diagnosis is *mucous polypus*.

(ii.) The uterus is normal in size or only slightly enlarged, but is found lying quite retroverted. The diagnosis is *congenital retroversion of the uterus*.

(c) The patient is a young woman, married or single. Menstruation has been increased in quantity for some months, perhaps for a year. The chief associated symptoms are backache and leucorrhœa. On examination, we find one of several conditions.

(i.) The uterus is bulky, and the vagina congested. No other physical signs are present. The diagnosis is *uterine congestion*.

(ii.) The uterus is bulky and heavy; the cervix is adenomatous; muco-pus exudes from the external os. The diagnosis is *endometritis*.

(iii.) The uterus is bulky, and the fundus lies back in the hollow of the sacrum; we may also find the signs of endometritis. The diagnosis is accordingly *retroversion*, or *retroversion with endometritis*.

(iv.) The uterus is distinctly enlarged, and is hard and irregular in outline ; the sound passes in for a distance of 3 or 4 inches. The diagnosis is *early fibroids of the uterus*.

(d) The patient suffers from moderate menorrhagia, and from abdominal pain referred to one or both iliac fossæ. She has had a yellowish discharge, which was at first associated with a scalding pain on micturition. She may be a single woman, who admits that her symptoms date from impure intercourse ; or a young married woman who began to suffer shortly after marriage ; or an older woman who has recently been confined, or whose husband has been unfaithful. On examination, a more or less acute vaginitis is present, and there may still be traces of urethritis or of purulent inflammation of the Bartholinian ducts. The cervix is reddened round the external os, the mobility of the uterus is impaired, and on one or both sides the appendages are found thickened and tender, or presenting considerable enlargement. The diagnosis is *acute gonorrhæal salpingitis* or *pyosalpinx*.

(e) The menorrhagia dates from a recent abortion or confinement at term ; the patient feels weak, and perhaps complains of hypogastric pain. There is no xanthorrhœa, and there may be no leucorrhœa. On examination, the uterus is found markedly larger than it should be for the period of involution. The diagnosis is *subinvolution of the uterus*, or *retained products of conception*. The ultimate diagnosis between these two will depend upon the results of treatment, or, failing improvement, upon dilatation of the cervical canal.

(f) Menstruation has been very profuse for months, or perhaps for a year or two, and the patient has symptoms of profound anæmia. There may be no other symptoms at all. On examination, we find :

(i.) The uterus is only slightly enlarged, and on dilata-

tion of its cavity under anæsthesia, it appears empty ; hardly any mucosa comes away with the curette. The diagnosis is *uterine fibrosis*.

(ii.) The uterus is moderately enlarged. A polypus may be projecting from the cervix, or the cervical canal may be dilated, and the finger introduced through it comes upon a polypus just inside, or there is only moderate dilatation of the uterine canal ; but on proceeding under anæsthesia to complete dilatation, a polypus is found in the uterus. In any of these cases the polypus may vary in size from a hazel-nut to a large orange. The diagnosis is *fibroid polypus of the uterus*.

(iii.) The uterus is considerably enlarged and hard ; it is either uniform or irregular in outline. The sound, if it can be introduced, passes 3 to 6 inches. The swelling may be large enough to be distinctly felt in the abdomen, reaching up, it may be, to the umbilicus, or even higher. The diagnosis is *uterine fibromyomata*.

**2. Hæmorrhage independent of Menstruation, or Metrorrhagia.**—Properly, we understand by metrorrhagia hæmorrhage from the uterus, but it will be convenient to include in this section all cases of hæmorrhage from the genital organs, because the source of the bleeding will be evident only on examination. We may begin our analysis by dividing the cases into (*a*) those that are traumatic, and (*b*) those in which there is no history of injury and the bleeding is due to disease.

**A. HÆMORRHAGE DUE TO INJURY.**—We may further distinguish three categories of injury—namely, accident, coitus, and parturition.

(*a*) *Accidental Injury.*—This is brought about in various ways.

(i.) One patient has fallen off steps or a chair astride some hard or sharp object ; another has been brutally ill-

ill-treated by kicking or otherwise; another has had a chamber utensil break while sitting on it. On examination, the nature of the injury is readily detected. It is usually on the vulva, but occasionally it may involve the vaginal walls in the case of a fall on a pointed object. The diagnosis is, accordingly, *vulvar or vaginal injury*.

(ii.) A rather different kind of case is one in which the patient is some months pregnant, and has had some injury to the vulva, perhaps severe, perhaps relatively slight. On examination, the veins of the vulva are enormously dilated and tortuous, presenting the appearance known as varicocele or varix. The injury has led to rupture of a vein, and the hæmorrhage is the result. The diagnosis is *ruptured vulvar varix*.

(b) *Injury during Coitus*.—It occasionally happens in the newly married that the rupture of the hymen is associated with free and even alarming bleeding. In such a case the tear has probably extended on one side beyond the margin of the hymen into the labium, perhaps involving the vestibular bulb, which would naturally be in a turgid condition. The nature of the injury is evident on inspection, and the diagnosis is *excessive tear of the hymen*.

(c) *Injury during Parturition*.—The practitioner is summoned within a few hours of parturition; it may be his own case or someone else's. It has usually, but not necessarily, been an instrumental delivery, and sharp hæmorrhage has followed. On examination of the abdomen, the uterus is felt contracted and hard; it is known or ascertained that the placenta and membranes came away entire. On examination, a tear is found involving the vulva, vagina, or cervix, and perhaps opening up the pouch of Douglas, or extending into one of the broad ligaments. The diagnosis is *laceration of the genital canal during labour*.

B. HÆMORRHAGE DUE TO DISEASE. — Menorrhagia often passes into metrorrhagia, but, nevertheless, the one may quite well be present without the other. We must emphasize one highly-important distinction between the two, and it is this : while menorrhagia may be due merely to functional congestion, *metrorrhagia is invariably due to some form of new growth*, ranging from a simple polypus to an advanced carcinoma. The only exception to this rule, apart from injuries, is where metrorrhagia follows a recent labour or miscarriage. In this case the bleeding may be due to incomplete abortion or to a placental polypus. From this generalization we deduce an equally important rule of practice—namely : *It is permissible under certain conditions to postpone a local examination in a case of menorrhagia ; but in a case of metrorrhagia an examination must invariably be made at the earliest possible moment.* This rule admits of no exceptions, and any failure to carry it out throws a very serious responsibility on the medical attendant, unless the patient takes on the responsibility by refusing permission for an examination.

In analyzing cases of menorrhagia and metrorrhagia, we shall follow our previous plan by beginning with the investigation of associated symptoms and physical signs.

(a) The patient states that she had a miscarriage, or, perhaps, a full-time confinement some weeks or months previously, and that she has had more or less continuous hæmorrhage ever since.

(i.) If only a short time has elapsed since the miscarriage, we shall find on examination that the uterus is larger than it should be, and the cervical canal is more or less patulous. We may be able to introduce a finger within the uterus and feel abnormal contents. The diagnosis is *incomplete abortion*, or, in other words, *retained products of conception*.

(ii.) If the labour or miscarriage dates back several months or a year, we shall find the uterus larger than the normal, the cervical canal not patulous, the appendages normal. The diagnosis is *placental polypus*.

I should like to lay stress on the importance of examining the appendages in all cases in which there is a history of recent miscarriage, because it is not an uncommon error to mistake for incomplete abortion a case that is really one of extra-uterine pregnancy. The mistake usually results from founding the diagnosis on symptoms, and accepting the statement of the patient's friends that 'everything has come away.' Even the symptoms, if carefully elicited, will generally give a clue, thus :

Hæmorrhage relatively free ; pain chiefly hypogastric : expect abortion.

Hæmorrhage scanty and brownish ; pain markedly lateral : expect extra-uterine pregnancy.

But reliance on symptoms for diagnosis is always dangerous, and it is bad practice. If an examination be made, the mistake can hardly occur, for in the case of abortion the ovaries and tubes will be found to be normal, whilst in a case of extra-uterine pregnancy a swelling will be found apart from the uterus.

The opposite error of mistaking for extra-uterine pregnancy a case that was really one of incomplete abortion would be possible if the case were complicated by tubal disease or a small ovarian cyst. Here the mistake would probably be excusable and possibly praiseworthy.

(b) The patient gives a history of confinement or abortion some months previously ; she has suffered from a good deal of hæmorrhage since, and has been losing weight. In the case of abortion it may turn out that the case was one of hydatid mole. There may be symptoms of chest trouble. On examination, the uterus is markedly larger

than the normal ; the appendages are normal. On dilating the cervical canal under an anæsthetic, the uterine cavity contains a growth, softer and more friable than the typical fragment of retained placenta. Its character, together with the fact of wasting, raises a suspicion of malignancy, and the growth is submitted to microscopic examination, when it is found to present the characteristics of chorio-epithelioma. The diagnosis is *chorio-epithelioma (deciduoma malignum)*.

(c) The patient has had excessive and irregular losses of blood for some months or for a year ; before that, she had noticed that the menstrual loss had become increasingly abundant. She has symptoms of anæmia. She is either single, or, if married, she has had no children, or has not been pregnant for many years. She feels weak, but has no particular pain, or she may have bearing-down pains, which are worse at the periods. On examination, one of several conditions may present itself :

(i.) The cervical canal is partially dilated, and a rounded, firm swelling is found just within the os externum, or partly or wholly extruded into the vagina. The diagnosis is *fibroid polypus*.

(ii.) The cervix is enormously enlarged, so that the lower pole of the uterus fills the pelvis ; the usual projection of the cervix is lost in the general rounded mass. Bimanually, the whole swelling feels the size of a foetal head ; at its upper pole is a smaller, rounded portion which feels like the body of the uterus perched on the summit of the ovoid tumour. The diagnosis is *cervix-myoma*.

(iii.) The uterus is considerably, and perhaps irregularly, enlarged ; the cervix may be normal. Bimanually, the uterine mass may be felt to be lobulated, with a number of hard, outlying portions. The sound, if passed, enters

4 or 5 inches or more, and its passage is attended with some bleeding. The diagnosis is *uterine myomata*, and from the history of hæmorrhage we may conclude that some part of the growth is submucous, and projecting into the uterine cavity, perhaps in the form of a definite polypus.

(d) The patient complains of irregular losses of blood, coming on without any previous menorrhagia. She has had several children, perhaps a large family. Lately she has noticed an unpleasantly-smelling discharge. The general health is good. On examination, the cervix is found to be the seat of a small, irregular growth, which is friable and bleeds easily, or of an irregular, ulcerating patch with hard, friable margins. The uterus is freely movable, and no thickening can be detected either at the base of the broad ligaments or in the position of the utero-sacral ligaments. A fragment of the suspicious portion submitted to microscopical examination presents the characters of carcinoma. The diagnosis is *early carcinoma of the cervix*.

(e) The symptoms are very similar to the above, but the patient is unmarried, or, if married, she has had no children. On examination, the uterus is freely movable and moderately enlarged, the cervix feels normal, and its canal is not patulous. The enlargement involves chiefly the fundus, which is unusually globular. So far, we can make only a provisional diagnosis that the case is one either of *intra-uterine polypus* or of *carcinoma or sarcoma of the body of the uterus*. The latter view will be supported if there is a history of wasting, or if the patient is forty to fifty years of age. On dilating the uterine canal under anæsthesia, we find either a small polypus, or a malignant growth in the form of a hard, irregular, ulcerating mass, or of a soft mass with the consistency of adenomata. Microscopic examination will confirm the diagnosis.



(f) The losses of blood are frequent and severe, sometimes in the form of clots. There is a good deal of pain, referred to the vagina and pelvis, and there is an abundant watery discharge with an offensive smell. The patient has lost flesh considerably ; she may be married, with a large family, or she may be single. On examination, we find one of two conditions :

(i.) The vagina is the seat of a more or less considerable growth, which is friable and bleeds easily. The diagnosis is *carcinoma or sarcoma of the vagina*. The exact pathological nature of the growth can only be determined by microscopical examination.

(ii.) The cervix is occupied by a large fungating irregular and friable mass, which bleeds on the slightest touch, or by an excavating ulcer, with irregular, hard, and undermined edges. The growth extends to the vaginal vaults, and the broad ligaments are thickened. The mobility of the uterus is impaired or may be completely lost. The growth may be found infiltrating the base of the bladder or spreading into the rectum. The diagnosis is *advanced carcinoma of the cervix*.

(g) The patient complains of slight hæmorrhage, which always follows coitus. This is a symptom common to several distinct conditions—some trivial and some grave—which will readily be recognised on examination. They are *urethral caruncle, cervical polypus, cervix-adenoma (erosion)*, and *early carcinoma of the vagina or cervix*.

3. **Hæmorrhage during Pregnancy.**—Hæmorrhage may occur at any stage of pregnancy ; its occurrence in the later months concerns a book on obstetrics rather than one on gynæcology ; but it will be convenient to include at least in our enumeration all hæmorrhages before labour. The associated symptoms will readily enable us to classify the cases.

(a) The case is one of early pregnancy, and the patient has no symptoms at all other than the bleeding, which is slight, and occurs at irregular times. Examination will show one of two conditions:

(i.) The cervix, vagina, and vulva, all appear to be perfectly normal, the uterus being enlarged to a size corresponding with the term of amenorrhœa. The explanation of the bleeding in such a case is obscure, but experience has shown that it may cease spontaneously and the pregnancy go to full term. If the hæmorrhage has a periodic rhythm, we may, for want of a better explanation, label the case as one of *menstruation during pregnancy*, remembering, however, that the occurrence of true menstruation (which means a preparation for conception) during pregnancy is, *a priori*, highly improbable, and is so far not proved. In the case of a double uterus, it is theoretically possible for menstruation to continue in one half while pregnancy is proceeding in the other; but it is certain that in most of the recorded cases of pregnancy in a double uterus the non-gravid half has contained a decidua, and has not menstruated.

(ii.) The bleeding is readily and satisfactorily explained by the presence of a small mucous polypus, presenting at the external os. The diagnosis is *pregnancy with cervical polypus*.

(b) The onset of hæmorrhage has followed some months of complete amenorrhœa, and has been accompanied or followed by pains in the abdomen and back, which are described as being 'like labour pains.' The bleeding has been very free, perhaps even alarming, and accompanied by clots. On examination, one of four stages may be present:

(i.) The uterus is enlarged in conformity with the term of amenorrhœa. The cervical canal is not patulous, and

there is only a little blood coming from the os externum. The diagnosis is *threatened abortion*.

(ii.) The uterus is as above, but the cervical canal is dilated, and a portion of the ovum is protruding through the external os, or is readily felt just within it. The diagnosis is *impending or inevitable abortion*.

(iii.) The fœtus or some portion of the ovum has been expelled, or is lying in the vagina. The cervical canal is patulous, and a portion of the ovum, probably the placenta, can be felt within the uterine cavity. The diagnosis is *incomplete abortion*.

(iv.) The uterus is enlarged, but not to a size corresponding with the term of amenorrhœa; the cervical canal is not patulous; there is no history or sign of the expulsion of any portion of the uterine contents. The diagnosis is *missed abortion*.

It is important to carefully distinguish these conditions from that which we are now about to describe.

(c) The bleeding has been scanty, brownish, and ushered in by an attack of sharp pain in one or other iliac region, coming on after six to twelve weeks of amenorrhœa. 'The pain was so severe that the patient fainted,' and she remained collapsed for some time after. After a few days in bed, the pain and bleeding ceased, and the patient got up, but was seized with a second attack of pain and faintness, and the slight bleeding began again. With such symptoms and history, the condition found on examination may vary somewhat.

(i.) The uterus is only slightly enlarged. On the side corresponding with the pain the tube is felt enlarged, as if it contained a walnut or a plum. In the pouch of Douglas is felt a rather soft and boggy fulness. The patient is blanched, with a rapid pulse and normal or subnormal temperature. The diagnosis is *tubal abortion or intra-*

*peritoneal rupture of the gravid tube, with circumscribed intraperitoneal hæmorrhage.*

(ii.) The general condition and the condition of the uterus being as before, the tube is felt thickened and passing into a large soft or cystic swelling, which lies behind and to one side of the uterus. The diagnosis is *intraperitoneal rupture of the tube, without free hæmorrhage.*

(iii.) The patient's general condition is fairly good; the uterus is as before; on the side corresponding with the pain there is a large swelling in the position of the broad ligament. It is immobile, and more or less restricted to the lateral aspect of the pelvis. The diagnosis is *intra-ligamentary or mesometric rupture of the gravid tube.*

(iv.) The patient is alarmingly collapsed and blanched; she is restless, and sweating; the pulse is rapid and thready. On examination, there is dulness in the flanks and in the lower part of the abdomen. By the vagina the uterus is felt only slightly enlarged. To one side of it is a swelling, apparently connected with one Fallopian tube. In the pouch of Douglas is a doughy, soft swelling. The diagnosis is *ruptured tubal pregnancy with free intraperitoneal hæmorrhage.*

In connection with this subject, the reader should refer to what has been said previously (p. 124) with regard to the diagnosis between retained products of conception and extra-uterine pregnancy.

(d) The patient states that the hæmorrhage has been free and accompanied by the passage of small bodies, looking like white grape or currant skins floating in red-currant juice. On examination, the uterus is found to be larger than it should be considering the term of amenorrhœa. If the typical follicles are found during examination, the diagnosis is at once established as *hydatidiform mole*, otherwise it will be necessary to wait until the uterine

canal has been dilated under anæsthesia, when the diagnosis will become clear.

(e) The patient complains of irregular discharges of blood, at first slight in quantity, and latterly more profuse. In the intervals of bleeding there is a watery offensive discharge. There may be no pain. On examination, the uterus is the size of a pregnant uterus corresponding to the term of amenorrhœa; the cervix is found to be the seat of a carcinomatous growth. The diagnosis is *pregnancy, with carcinoma of the cervix*.

It is noteworthy that when carcinoma is discovered during pregnancy, the latter has almost invariably made considerable progress—that is, from the sixth month onwards. The probable explanation is that advanced or moderately advanced carcinoma is a bar to conception, and that when the combination is found pregnancy must have commenced before the appearance of the carcinoma, or, at any rate, while the growth was in a very early stage.

(f) The patient has arrived at the seventh, eighth, or ninth month of gestation, and has lately begun to suffer from losses of blood in greater or less quantity, which may or may not have been accompanied by pain. On examination, the lower pole of the uterus may be found to be unusually wide, and instead of, or in addition to, the hard rounded foetal head, the lower part of the uterus is occupied by a firm but impressionable swelling. The cervical canal is perhaps patulous, and allows the finger to detect the placenta, or a margin thereof, lying low down over the internal os. The diagnosis is *placenta prævia*. Or no evidence may be forthcoming that the situation of the placenta is otherwise than normal, and the case must be described as one of *accidental hæmorrhage*. For fuller particulars of these conditions the reader is referred to a text-book on obstetrics.

## SYNOPSIS OF CASES OF HÆMORRHAGE.

Leading Symptom.	Associated Symptoms.	Physical Signs.	Diagnosis.
I. HÆMORRHAGE DURING MENSTRUATION	<p>(a) None ; early puberty</p> <p>(b) Continued menorrhagia and anæmia in a young girl</p> <p>(c) Backache and leucorrhœa</p>	<p>Pelvic organs normal</p> <p>(i.) Mucous polypus, cervical or uterine</p> <p>(ii.) Uterus displaced backwards</p> <p>(i.) Uterus bulky ; vagina congested</p> <p>(ii.) Uterus bulky and heavy ; erosion</p> <p>(iii.) Uterus bulky, retroverted ; erosion</p> <p>(iv.) Uterus large, irregular, hard</p> <p>Vaginitis ; endometritis ; appendages thickened and tender</p> <p>Uterus enlarged</p>	<p>Functional congestion of puberty</p> <p>Mucous polypus</p> <p>Congenital retroversion</p> <p>Uterine congestion</p> <p>Endometritis</p> <p>Retroversion and endometritis</p> <p>Early uterine myoma</p> <p>Salpingitis or pyosalpinx</p>
	<p>(d) Moderate menorrhagia ; iliac pain ; xanthorrhœa ; painful micturition</p> <p>(e) Recent labour or abortion ; weakness</p>	<p>Uterus enlarged</p>	<p>Subinvolution or retained products of conception</p> <p>Uterine fibrosis</p>
	<p>(f) Profuse menorrhagia for months or years ; anæmia</p>	<p>(i.) Uterus hard and slightly enlarged ; on curetting, mucosa is atrophied</p> <p>(ii.) Fibroid polypus in the uterus or projecting from the cervix</p> <p>(iii.) Uterus hard, large, irregular ; abdominal tumour</p>	<p>Fibroid polypus</p> <p>Uterine myomata</p>

<p>2. HÆMORRHAGE INDEPENDENT OF MENSTRUATION A. Hæmorrhage due to injury</p>	<p>(a) Accidental injury</p> <p>(b) Injury during coitus</p> <p>(c) Injury during labour</p>	<p>(i.) Laceration of vulva or vagina (ii.) Pregnancy; varix of vulva, bleeding</p> <p>Laceration of hymen extending into labium</p> <p>Laceration of, perineum, vulva, vagina, or cervix</p> <p>(i.) Uterus enlarged; cervical canal patulous</p> <p>(ii.) Uterus enlarged; canal closed</p> <p>Uterus enlarged; growth found on exploring cavity</p> <p>(i.) Fibroid polypus in the uterus or projecting from the cervix</p> <p>(ii.) Cervix greatly enlarged by hard growth; body of uterus on summit of tumour</p> <p>(iii.) Uterus uniformly or irregularly enlarged, and hard</p> <p>Small irregular growth or excavation of the cervix, which bleeds easily</p>	<p>Vulvar or vaginal injury Ruptured vulvar varix</p> <p>Excessive tear of hymen</p> <p>Laceration of genital canal during labour Incomplete abortion</p> <p>Placental polypus Chorio-epithelioma (deciduoma malignum) Fibroid polypus</p> <p>Cervix myoma</p> <p>Uterine myoma</p> <p>Early carcinoma of the cervix</p>
<p>B. Hæmorrhage due to disease.</p>	<p>(a) Recent labour or abortion</p> <p>(b) Recent labour or abortion; wasting; (chest trouble)</p> <p>(c) Excessive metrorrhagia following menorrhagia; anæmia; patient is single, or relatively sterile</p> <p>(d) Irregular moderate losses without previous menorrhagia; recent offensive discharge; patient has had children</p> <p>(e) Symptoms as above in an unmarried or childless woman</p>	<p>Cervix normal; uterus moderately enlarged; growth found on exploring uterus</p>	<p>Carcinoma or sarcoma of the body of the uterus</p>

SYNOPSIS OF CASES OF HÆMORRHAGE—continued.

Leading Symptom.	Associated Symptoms.	Physical Signs.	Diagnosis.
<p>3. HÆMORRHAGE DURING PREGNANCY</p>	<p>(f) Losses frequent, severe, with clots; pain may be present in pelvis; watery offensive discharge; wasting</p> <p>(g) Slight hæmorrhage after coitus</p> <p>(a) Early pregnancy; slight bleeding</p> <p>(b) Two to three months' amenorrhea; pain in abdomen and back</p> <p>(c) Hæmorrhage scanty and brownish; sharp lateral pain; faintings</p> <p>(d) Sharp hæmorrhage; passage of follicles</p> <p>(e) Late pregnancy; irregular profuse losses; watery discharge</p> <p>(f) Late pregnancy; no symptoms</p>	<p>(i.) Irregular growth on the vaginal wall</p> <p>(ii.) Large fungating growth or excavating ulcer of the cervix; uterus fixed</p> <p>Urethral caruncle; mucous polypus; erosion; or early carcinoma of vagina or cervix</p> <p>(i.) Mucous polypus of cervix</p> <p>(ii.) Normal pregnancy</p> <p>(i.) Uterus enlarged; os closed</p> <p>(ii.) Uterus enlarged; os patulous</p> <p>(iii.) Ovum partly extruded</p> <p>Uterus slightly enlarged; lateral or posterior swelling; patient blanched, perhaps collapsed</p> <p>Uterus abnormally enlarged; follicles found</p> <p>Growth or ulceration of cervix</p> <p>(i.) Placenta felt implanted low</p> <p>(ii.) No abnormality discovered</p>	<p>Carcinoma or sarcoma of the vagina</p> <p>Advanced carcinoma of the cervix;</p> <p>According to condition found</p> <p>Cervical polypus</p> <p>(? Menstruation during pregnancy)</p> <p>Threatened abortion</p> <p>Inevitable abortion</p> <p>Incomplete abortion</p> <p>Extra-uterine gestation</p> <p>Hydatidiform mole</p> <p>Carcinoma of cervix and pregnancy</p> <p>Placenta prævia</p> <p>Accidental hæmorrhage</p>



## CHAPTER XI

### LEADING SYMPTOM : DISCHARGE

WHEN a patient comes complaining of discharge, we shall begin by inquiring into its character ; its colour and consistency will give us a starting-point for our investigation.

**I. White Discharge, or Leucorrhœa.**—The patient states that she suffers from ‘the whites.’ The discharge stiffens her linen, but does not stain it ; it is most abundant for some days after the cessation of menstruation, but it may be constantly present in greater or lesser quantity between the periods. On inquiry into associated symptoms, we find two principal types.

(a) There are no symptoms at all other than the leucorrhœa ; or the patient complains of lassitude and a little backache ; or, in the case of a young girl, there may be symptoms of anæmia. If an examination is deemed necessary, we find the pelvic organs practically normal, or the vagina may be rather hot and the uterus heavy. The discharge found in the vagina is either dull white, and curdy or flaky, or clear, viscid mucus. The former is the normal vaginal secretion ; the latter is the normal secretion from the cervix. In many cases the discharge consists of both secretions. We have therefore to do with an increase of normal secretions, and the diagnosis is *functional pelvic congestion*.

(b) The patient suffers a good deal from backache, and a feeling of weight and bearing down; she is easily tired and feels wanting in energy; menstruation is increased in quantity. On examination, the uterus is rather bulky, and is perhaps retroverted; the cervix presents an 'erosion'; and the discharge is muco-purulent. The diagnosis is accordingly *endometritis*, *cervix-adenoma*, or *retroversion*.

2. **Yellow Discharge, or Xanthorrhœa.**—This implies definite inflammatory trouble in the pelvis, and various degrees and varieties may be present.

(a) There is burning pain on micturition; the discharge is of recent date. On examination, there is redness of the vulva, vagina, and urethral orifice, and of the orifice of the Bartholinian ducts. On pressing the urethra from within outwards, a drop of pus escapes. On inspection with a speculum, the cervix and vagina are of a bright red colour, and the vagina is bathed in pus. The diagnosis is *gonorrhœa*.

(b) In addition to the above symptoms, the patient complains of sore places on the vulva, so that she has great pain on walking and on sitting down. On examination the vulva is swollen and covered with raised patches with flat tops, which are reddened, dotted over with minute papillæ, and bathed in a watery purulent discharge. The vagina and cervix are as in the previous case. The sores may extend back over the perineum and surround the anal orifice. The diagnosis is *gonorrhœal condylomata*.

(c) The yellow discharge has been going on for some weeks or months; at first there was scalding pain on micturition. There is a good deal of pain in the lower part of the abdomen on both sides, perhaps worse on one side. Menstruation has been increased in quantity. It may be that the patient has been married only a few

months, and the symptoms date from shortly after marriage. The husband admits that before marriage he had gonorrhœa, which he believed to be quite cured. On examination, there is some redness of the vagina and cervix, and the vagina contains muco-pus, which can be seen exuding from the external os. The uterus is partly or wholly fixed; on one or both sides is a tender swelling in the position of the ovary and tube. The diagnosis is *gonorrhœal salpingitis* or *pyosalpinx*.

(d) There are no associated symptoms, or perhaps only some pain referred to the vagina. The patient states that she used to suffer from displacement or falling of the womb, and had a pessary inserted, which has not been seen to for one, two, or more years; or she may be uncertain whether she is wearing a pessary or not. She states that the discharge smells bad. On examination, an old and effete pessary is found in the vagina, lying in a pool of pus. On removing it, the vaginal walls are reddened, and perhaps ulcerated in the form of grooves, where the pessary has been in contact with them. The diagnosis is *acute vaginitis from retained pessary*.

(e) The patient has suffered from a good deal of pain in the pelvis, and feverishness; the discharge began later, and was very profuse at first. When the discharge came on the pain was relieved, and the feverishness became less. On examination, pus is found in the vagina; it can be traced to a fistulous communication in the vaginal wall on one side, or it is evidently coming out through the external os. The uterus is more or less fixed, and to one side of it is a firm fixed swelling in the position of the broad ligament; or the swelling is in the pouch of Douglas, and the fistulous opening is in the posterior vaginal fornix. The diagnosis is *pelvic abscess discharging through the vagina*.

(f) The patient is a middle-aged or elderly woman ; the discharge of pus is irregular, and she also suffers from losses of blood, and pain in the pelvis. She has lost flesh considerably. On examination, the cervix is the seat of carcinoma of the proliferating type ; on passing a sound into the uterus, there is a discharge of pure pus. The diagnosis is *carcinoma of the cervix, associated with pyometra*.

3. **Fœtid Watery Discharge.**—This occurs in two types of case.

(a) The patient suffers from menorrhagia, and perhaps, metrorrhagia, and has done so for some time ; the bleeding is usually considerable in quantity. She may also present symptoms of pressure in the pelvis. On examination, the uterus is enlarged and either hard or boggy in consistence. The degree of enlargement varies between wide limits in different cases. The cervix is normal, but the cervical canal is patulous, and possibly a smooth, rather soft tumour is felt inside ; or there may be a tumour projecting from the cervix, and lying more or less extruded into the vagina. On inspection of such a tumour through a speculum, it appears of a dull grey or almost black colour, with perhaps reddish patches. The diagnosis is *sloughing myoma or polypus*.

(b) The patient suffers from metrorrhagia ; the bleeding is not usually excessive, but it is almost constant. She has lost flesh, and perhaps complains of pain in the pelvis. On examination, the cervix is the seat of an excavating carcinomatous ulcer, or of a fungating proliferating mass, which breaks down readily under the touch. The diagnosis is *carcinoma of the cervix*.

4. **Blood-stained Discharge.**—This is present in a variety of conditions, to which we shall be guided, in the usual way, by the associated symptoms and the physical signs.

(a) The patient presents either no other symptoms, or she has a little backache. On examination, we find either an *adenomatous condition of the cervix* (erosion), which bleeds readily when touched; or a small *mucous polypus* projecting from the cervix; or an *early carcinoma of the cervix or vagina*. The diagnosis is made accordingly.

(b) The patient states that she has suffered from displacement, or from falling of the womb, for which she has been treated by a pessary; she has not had the pessary attended to for a year or longer. On examination, a pessary is found in the vagina; it is a hard type of pessary, and has been pressing on the vaginal walls in such a way as to cause ulceration in the form of grooves, in which the pessary has been resting. The diagnosis is *vaginal ulceration from a retained pessary*.

(c) There is a history of bearing-down pain and falling of the womb, for which the patient has had no treatment; she states that the parts come down outside. On examination, a complete procidentia is found, the cervix forming the apex of a mass, of which the sides are formed by the vaginal walls, completely inverted. On this exposed surface we observe one or more ulcerated patches, looking as if the vaginal wall had been smoothly punched out. These ulcers bleed readily. The diagnosis is *ulceration from the friction of clothes against a procident uterus and vagina*.

5. **Brownish Discharge.**—This is mentioned here merely to remind the reader that this may be the principal symptom complained of in a case of *extra-uterine pregnancy*; and that the mention of a brownish discharge ought always to suggest to the mind the possibility of the existence of that condition.

6. **A Urinous Discharge.**—The patient complains that she is always moist with a discharge that has the odour of

urine. She may tell us that this has been going on ever since her last confinement, which was a very difficult one, requiring instruments; or that it has followed some operation; or that she has been wearing a pessary for some years. On examination, we find in the latter case a pessary in the vagina, obviously pressing injuriously against the anterior vaginal wall. A careful examination of the vagina with the finger, or inspection through a duck-bill speculum, shows a depression, or perhaps an obvious hole in some part of the surface; and a probe can be passed through this into the urethra or bladder; a sound passed simultaneously into the bladder can be felt to touch the probe. Or no definite orifice can be made out; but a pledget of cotton-wool inserted into the vagina, and removed after some minutes, comes out moist, with a urinous odour. Or some sterilized milk is injected into the bladder after drawing off the urine; and on inspection through a speculum, minute droplets of milk can be seen coming through the vaginal wall, or perhaps through the os externum. The diagnosis is *vesico-vaginal*, *urethro-vaginal*, or *vesico-uterine fistula*.

Or we may find that the milk test is negative, but urine clearly finds its way into the vagina; on measuring the quantity so passed in a given time, it is found to equal the quantity passed through the bladder in the same time. The diagnosis is *uretero-vaginal* or *uretero-uterine fistula*. A *uretero-vaginal fistula* is most likely to have followed an operation such as a vaginal hysterectomy.

## SYNOPSIS OF CASES OF DISCHARGE.

Character of Discharge.	Associated Symptoms.	Physical Signs.	Diagnosis.
1. WHITE	(a) None ; or lassitude and backache ; anæmia (b) Backache ; lassitude ; menorrhagia (a) Painful micturition ; recent history (b) Painful micturition ; sores on the privates (c) History of weeks or months ; pain in lower abdomen ; menorrhagia (d) None ; or pain in the vagina ; his- tory of wearing a pessary (e) Pain in pelvis ; fever, relieved at onset of the discharge (f) Irregular discharge of pus and blood ; pelvic pain ; emaciation	Normal ; or congestion ; discharge flaky white or clear mucous Uterus bulky ; or retroversion or erosion Redness of genital canal ; urethritis ; pus in Bartholinian ducts Vulvo-vaginitis, with condylomata on vulva Vulvo-vaginitis ; tender swellings at sides of the uterus, with fixation Old effete pessary in the vagina ; excoria- tion or ulceration of vaginal walls Fistula in vagina opening into abscess cavity Carcinoma of cervix ; pus exudes on passing a sound	Pelvic congestion Endometritis ; retroversion Gonorrhœa Gonorrhœal condylomata Gonorrhœal salpingitis or pyo- salpinx Vaginitis from retained pessary Pelvic abscess discharging through the vagina Pyometra, with carcinoma of the cervix Sloughing myoma or polypus Carcinoma of cervix
3. FÆTID WATERY	(a) Menorrhagia ; (pressure symp- toms) (b) Metrorrhagia ; pelvic pain ; ema- ciation	Uterus large ; cervix normal ; polypus felt in uterus or vagina Carcinomatous ulcer or growth of the cervix	Erosion ; mucous polypus ; or early carcinoma Vaginal ulceration from retained pessary Carcinoma of cervix
4. BLOOD- STAINED	(a) None ; or backache (b) History of wearing a pessary some time	Erosion ; mucous polypus ; or early malignant disease Hard pessary ulcerating vaginal wall	Erosion ; mucous polypus ; or early carcinoma Vaginal ulceration from retained pessary Extra-uterine pregnancy
5. BROWNISH	Symptoms of extra-uterine pregnancy	Signs of extra-uterine pregnancy	Extra-uterine pregnancy
6. URINOUS	History of difficult labour ; pessary long worn ; or operation	Fistulous communication into vagina ; or urine passing through os externum	Urethro-vaginal, vesico-vagi- nal, or uretero-uterine fistula

## CHAPTER XII

### LEADING SYMPTOM: PRURITUS

PRURITUS VULVÆ, or irritation of the vulva, is seldom associated with grave pelvic disease; but it is the source of a great deal of misery to its victim, and is apt to lead to serious ill-health, by reason of loss of sleep and constant discomfort. It therefore behoves us in every case to endeavour to trace out its cause. The first two types described here are not gynæcological, but they are included in order to remind the student that he must be on the look-out for them.

(a) The patient states that the irritation is associated with frequent micturition, and that she passes a very large quantity of water. She is very thirsty, and has to drink a great deal of water, and she is generally hungry. On examination of the pelvic organs, they are found to be normal, or there may be a little redness round the urethral orifice. Examination of the urine reveals the presence of sugar. The diagnosis is *diabetes*.

(b) The patient complains of painful and frequent micturition, and states that the water has a strong or bad odour. She may be a little feverish. On examination, there is considerable tenderness on bimanual pressure over the bladder and urethra, and redness of the urethral meatus; the pelvic organs are normal, or there may be a



vesico-vaginal fistula. On analysis of the urine, it is found to be strongly alkaline ; it has an ammoniacal odour ; it is turbid from the presence of phosphates or pus, or both. The diagnosis is *cystitis*.

(c) The only associated symptom is leucorrhœa, or this combined with backache ; or in addition there may be slight menorrhagia. On examination, the uterus is heavy and bulky ; the cervix is adenomatous ; muco-pus exudes from the os externum. The diagnosis is *endometritis*.

(d) In this group there may be one or several of a variety of associated symptoms. Thus, in one case there is amenorrhœa, with other symptoms of pregnancy, and leucorrhœa. In another there are symptoms pointing to pressure in the pelvis, or there may be menorrhagia. In a third the chief complaint is of backache and bearing-down pains. A fourth may complain of swelling of the privates. On examination, a corresponding diversity of physical signs is present. The first patient is pregnant ; the second has a tumour occupying the pelvis ; the third a retroversion ; in the fourth case there is a varix of the vulva. The common feature of all these cases, and that which gives rise to their common symptom, is *congestion of the vulva*.

(e) In this type the irritation is very severe, so that the patient scratches and tears herself, and is driven almost distracted by the annoyance of it and by the resulting loss of sleep. The privates feel hot and swollen. On examination, the vulva is deeply injected and congested. The swelling may be sufficient to give a dusky œdematous appearance. Marks of scratching are plainly seen. The parts chiefly affected are the prepuce of the clitoris and the labia minora, and, to a lesser extent, the labia majora. The diagnosis is *vulvitis pruriginosa*.

(f) We now come to another distinct type, in which

there may be no symptoms at all beyond the pruritus, or, if the patient is married, there is dyspareunia, 'because the passage feels too small.' As in the last case, the irritation is very severe and destructive of sleep, and undermines health. On examination, the vulva has a dull, white aspect, as if the skin had been sodden by soaking in water. It is also curiously smooth, as if the natural creases had been ironed out, and the prepuce clitoridis and labia minora are strikingly atrophied, so that in extreme cases they have disappeared altogether. The vaginal orifice is greatly contracted, and dotted about round the orifice are a number of petechiæ. The pubic hair has a wiry, stunted aspect. The diagnosis is *kraurosis vulvæ*.

(g) Our last type is one that is met with occasionally. The patient is a girl or unmarried woman; she is nervous, and complains of frequent desire for micturition. On examination, the vulva looks congested; the labia minora and prepuce clitoridis are large and swollen; between the labia minora and the labia majora are folds of skin which are thrown into prominence by traction on the labia minora. The probable diagnosis is *masturbation*.

SYNOPSIS OF CASES OF PRURITUS.

Leading Symptom.	Associated Symptoms.	Physical Signs.	Diagnosis.
PRURITUS VULVÆ	(a) Polyuria; thirst; large appetite	Pelvic organs normal; sugar in the urine	Diabetes
	(b) Frequent and painful micturition: water smells strong	Redness of meatus urinarius; tenderness of bladder and urethra; alkaline urine, with pus or phosphates	Cystitis
	(c) Leucorrhœa; perhaps backache and menorrhagia	Uterus heavy and bulky; cervix adenomatous	Endometritis
	(d) Various symptoms of pregnancy, pressure or vulvar swelling, etc.	Pregnancy; pelvic tumour, retroversion, varix of vulva, etc.	Congestion of the vulva incidental to the causal condition
	(e) Very severe irritation; pain in vulva; loss of sleep; heat and swelling of privates	Vulva deeply injected and swollen, with marks of scratching	Vulvitis pruriginosa
	(f) Very severe irritation; loss of sleep; dyspareunia	Atrophy of labia minora and prepuce; vulva smooth; pubic hair stubbly	Kraurosis vulvæ
	(g) Patient is single; nervousness; frequency of micturition	Hypertrophy of labia minora and prepuce, with traction bands	Masturbation

## CHAPTER XIII

### LEADING SYMPTOM : DYSPAREUNIA

PAIN during sexual intercourse is met with among the newly-married, and also after years of married life, and, possibly, child-bearing. In the former case, it is often due to anatomical conditions, whilst in the latter it is generally the result of disease. It will be convenient to begin our investigation of a case of dyspareunia by inquiring whether intercourse has been painful from the very first (primary dyspareunia), or whether the pain is a later feature (secondary dyspareunia).

1. **Primary Dyspareunia.**—Here we meet with two types, in which dyspareunia proves to be due respectively to physiological and anatomical conditions.

(a) The patient is probably a young married woman, of a shy and nervous temperament. As the result of fear and nervousness, she has not permitted complete intercourse, and the attempts have given her great pain; or intercourse has been effected, but has been so painful that it has been but rarely repeated. On examination, we may find that the hymen is actually intact, or the vagina contracts strongly on the examining finger, the patient complaining of great pain (vaginismus), or the very thought of examination so terrifies and disturbs the patient that it is found

impossible to pursue the investigation without having recourse to an anæsthetic. Anatomically, all the pelvic organs are quite normal. The diagnosis is *neurosis*.

(b) There is an absence of the nervous element found in the previous type. The patient is a young married woman, of apparently healthy appearance, or she may appear to be 'girlish' rather than womanly. She will probably state that the pain is of such a character as to make her feel that the parts are too small, or intercourse may not have been effected. On examination, one of several conditions may be present.

(i.) The pelvic organs are quite normal, except that the hymen is dense, rigid, or unyielding. The diagnosis is *rigidity of the hymen*.

(ii.) The vulva is rather small and the vagina is narrow, either at its entrance or all the way up. The uterus is either normal or undersized. The diagnosis is *vaginal stenosis*.

(iii.) There is a double vagina, each orifice being smaller than the normal single vagina. In such a case the uterus also is double. The diagnosis is *double vagina*.

(iv.) There is no vaginal orifice, a transverse septum closing the lower end of the vagina. In some cases of this type intercourse has unwittingly taken place in the urethra or the rectum, and the former may be remarkably stretched. The diagnosis is *vaginal atresia*.

(v.) The vagina is rudimentary, being both short and narrow, or it is absent altogether. In either case the patient may be the subject of that remarkable malformation known as pseudo-hermaphroditism—possessing testes instead of ovaries. The individual is, of course, a man, but may have been brought up as a woman, and married as such. I have met with an instance of this unfortunate error, in which the patient had been married ten years.

The diagnosis, according to the condition found, is *rudimentary vagina*, *absence of the vagina*, or *pseudo-hermaphrodisism*.

2. **Secondary Dyspareunia.**—In this class of case intercourse was painless at the beginning of married life, but has been painful recently. We shall pursue our inquiry by ascertaining whether the pain is referred to the vulva or to the deeper part of the pelvis.

A. PAIN REFERRED TO THE VULVA.—Associated symptoms will now require our attention.

(a) The patient complains of soreness in the vulva, even independently of intercourse; otherwise, she has nothing to complain of. On examination, the vulva presents some excoriation or laceration, or perhaps a fissure in the neighbourhood of the hymen, or the vulvo-vaginal orifice is reddened, swollen, and tender, as the outcome (we may discover) of immoderate intercourse. The diagnosis is, accordingly, *traumatism of the vulva*.

(b) There is soreness of the vulva and vagina, with pain on micturition, and a yellowish discharge. The history is a recent one. On examination, vulvo-vaginitis is present. The diagnosis is *vaginitis*, *probably gonorrhæal*.

(c) In addition to soreness and leucorrhœa or xanthorrhœa, the patient states that she has a painful swelling on one side of the privates, which causes great pain on sitting and standing. On examination, one labium majus is found to be the seat of a pyriform swelling. The diagnosis is *Bartholinian cyst* or *abscess*.

(d) The patient has recently been confined, and states that she was torn during the birth of the child. She may add that the tear was sewn up at the time. On examination, there is evidence of a tear of the perineum, which has failed to heal completely at one spot; or it has healed, but left a painful scar; or we may find an unhealed or

painful cicatrix in the vagina itself. The diagnosis is, accordingly, *incompletely healed or painful perineal or vaginal scar*.

(e) Intercourse is painful and accompanied by a little bleeding; there is also pain on passing water and at other times, referred to the urethral orifice. On examination, the urethra presents a caruncle, which is very tender to the touch and bleeds easily. The diagnosis is *urethral caruncle*.

B. PAIN REFERRED TO THE DEEPER PART OF THE PELVIS.—(a) The patient refers the pain to one or other iliac region, the pain is present independently of intercourse, and feels as if it shoots down to the perineum. There may be pain on defæcation. On examination, the uterus is normal; on one side, the ovary is enlarged, very tender, and lies prolapsed by the side of the uterus, or behind it, in the pouch of Douglas. The diagnosis is *prolapsed cystic ovary*.

(b) There is pain in the side and also in the back, with a feeling of weight and bearing-down. The patient suffers from leucorrhœa. On examination, the fundus of the uterus is lying in the pouch of Douglas, imprisoning the ovary of one side, which lies below it. The other ovary may be prolapsed also, or it may be lying higher and out of reach of painful pressure. The diagnosis is *retroversion of the uterus, with prolapsed ovary*.

(c) Pain in the side is very acute, and there is a constant dragging in the pelvis. The pain may affect one or both sides. The patient suffers from xanthorrhœa, or has done so at some antecedent period. On examination, the uterus is more or less fixed; the tubes are thickened or markedly enlarged. The diagnosis is *chronic salpingitis*.

It is, of course, evident that in any condition of acute

pelvic inflammation intercourse would be attended with great pain ; but we need not consider this class of case here, because intercourse would not take place in such circumstances, and consequently the symptom or symptoms for which the patient would seek advice would not include dyspareunia.



SYNOPSIS OF CASES OF DYSPAREUNIA.

Leading Symptom.	Associated Symptoms.	Physical Signs.	Diagnosis.
1. PRIMARY DYSPAREUNIA	(a) Young, nervous married woman; (incomplete intercourse)	Vaginismus; pelvic organs normal	Neurosis
	(b) Young married woman; no symptoms, or incomplete intercourse	(i.) Hymen rigid and unyielding (ii.) Vulva small; vagina narrow; uterus small (iii.) Double uterus and vagina (iv.) No vaginal orifice (v.) Vagina short and narrow, or absent; or pseudo-hermaphroditism	Rigidity of the hymen Vaginal stenosis  Double vagina with persistent septum Vaginal atresia Rudimentary vagina or absence of the vagina  Traumatism of the vulva
	(a) Soreness of the vulva	Excoriation, laceration, or fissure of the vulva or vagina; or bruising and inflammation Vagina inflamed; urethritis	Vulvo-vaginitis (gonorrhoeal) Bartholinian cyst or abscess Incompletely healed or painful perineal or vaginal scar Urethral caruncle
	(b) Soreness; xanthorrhœa; painful micturition	Pyriform swelling in labium majus	
	(c) Soreness; leucorrhœa; painful vulvar swelling	Unhealed spot on perineum, or painful scar of perineum or vagina	
2. SECONDARY DYSPAREUNIA	(a) Pain referred to vulva	Urethral caruncle	
	(b) Soreness; xanthorrhœa; painful micturition	Ovary enlarged, tender, lying low Uterus retroverted or flexed; ovary low and tender Uterus fixed; tubes thickened or enlarged	Prolapsed cystic ovary Retroversion, with prolapsed ovary Chronic salpingitis
	(c) Pain both sides; dragging in pelvis; leucorrhœa or xanthorrhœa		
B. Pain referred deeply			

## CHAPTER XIV

### LEADING SYMPTOM: STERILITY

STERILITY, as a pathological state, means incapacity to conceive, but, as a symptom, it means merely the non-occurrence of conception in a married woman. The distinction is important, because, although a woman may be sterile in both senses—that is, actually as well as apparently—she may, on the other hand, be sterile in only one sense. Thus a single woman with an undeveloped uterus is actually sterile, but she is not apparently so; and, on the contrary, a normally endowed woman married to an impotent man is apparently, but not actually, sterile. In investigating a case in which a woman has been married for some years without conceiving, we may find the pelvic organs quite normal, and we must guard ourselves against assuming that the responsibility lies with her and not with her partner.

In this chapter sterility is discussed as a symptom, and we may begin by drawing a broad distinction between primary sterility, where a woman has never conceived, and secondary sterility, where a woman has been pregnant in her early married life, but not for some years since, although she is still of a child-bearing age. From a descriptive standpoint, we should classify sterility as congenital, due to developmental error; and acquired, due

to disease. But a pathological classification prejudices the case, and is therefore not permissible when considering the subject from our present standpoint.

1. **Primary Sterility.**—What associated symptoms have we to guide us ?

(a) In the first type of case there are no associated symptoms. The patient feels perfectly well, and menstruates regularly and normally. On examination, the pelvic organs are quite normal. In such a case the husband should be examined, and if he is normal, or has had children by a former wife, we must regard the sterility as unexplained, or, according to our fancy, we may ascribe it to *defective ovulation* or *sexual incompatibility*.

(b) The patient feels well ; there is no dyspareunia ; menstruation is scanty and irregular or infrequent ; or perhaps it has never been established. On examination, we find :

(i.) The vulva and vagina are normal ; the uterus is small, the uterine cavity measuring two inches or less in length ; the cervix is small and conical, and the os externum is small. The diagnosis is *under-developed* or *infantile uterus*, according to its degree.

(ii.) The vulva and vagina are normal or under-developed ; the uterus is so small as to be represented only by a small knob. The diagnosis is *rudimentary uterus*.

(c) The patient complains of dyspareunia, or states that intercourse has never been properly effected. Menstruation is normal. On examination, we find :

(i.) The hymen is rigid and unyielding ; the uterus and appendages are normal. The diagnosis is *incomplete intercourse from rigidity of the hymen*.

(ii.) The hymen is normally torn ; the pelvic organs are normal. Digital examination is painful, and leads to

marked spasm of the sphincter vaginæ, or the vagina may be unduly narrow. The diagnosis is *incomplete intercourse from vaginismus* or *vaginal stenosis*.

(iii.) The vagina is double, each half being under full size, and the longitudinal septum is persistent and complete. The diagnosis is *double vagina*.

(d) The patient states that intercourse has never been effected, and that she has never menstruated. On examination, we find that the vagina is absent or represented only by a shallow pit, or that its entrance is occluded by a septum, or that there is some gross malformation, such as pseudo-hermaphroditism. The diagnosis is *absence or atresia of the vagina*.

(e) There is no dyspareunia, and the patient has no symptoms except dysmenorrhœa, which is rather severe. This type of patient is frequently very stout. On examination, the cervix is small and conical; the os is 'pinhole.' The fundus is sharply flexed forward, and forms a right or acute angle with the cervix. The diagnosis is *stenosis and ante flexion*.

(f) The patient complains of backache, dysmenorrhœa, and perhaps leucorrhœa. On examination, the cervix is normal or small; the fundus is acutely retroflexed, and lies in the pouch of Douglas. The ovaries are normal or prolapsed. In the latter case we may elicit a history of dyspareunia. The diagnosis is *retroflexion and version of the uterus*.

(g) The patient states that soon after her marriage she observed a yellow discharge, the onset of which was associated with painful micturition. Menstruation has been more abundant than it was before marriage. She suffers from pelvic pain, referred especially to one or both iliac regions, and she may have dyspareunia. On examination, the tubes are thickened, or considerably enlarged,

so as to form a defined tumour on each side of the uterus. The latter may be normal, but is more likely to be fixed and perhaps retroverted. The diagnosis is *pyosalpinx*, *hydrosalpinx*, *tubo-ovarian cyst or abscess*, or *chronic salpingitis*, according to the stage arrived at.

(h) Menstruation has always been free, and has latterly become abundant. There may have been some hæmorrhage in addition in the menstrual intervals. This may comprise all the symptoms, or there may be pain in the pelvis, a feeling of pressure on the bladder, or frequency of micturition, which sometimes gives place to retention of urine at the commencement of menstruation. On examination, the uterus is large, hard, the seat of a fibroid tumour or of multiple tumours, or a fibroid polypus presents at the os externum or projects from the cervix. The diagnosis is *uterine fibromyoma*.

2. **Secondary Sterility.**—After a woman has had several children she may arrive at a state of exhausted fertility and bear no more; but this does not come within the scope of our consideration, because such a patient is not likely to come complaining of not conceiving. Apart from this state of things, we may say that secondary sterility is the result of disease, in contrast with the primary form, which, we have found, may be due either to disease or to under-development.

(a) The patient states that she has not been well since the birth of her child. She suffers from leucorrhœa, back-ache, weight in the pelvis, and increased menstruation. On examination, we find the vaginal walls and outlet relaxed, the cervix is adenomatous, the uterus is low in the pelvis, bulky, perhaps retroverted. The diagnosis is *endometritis and prolapse*. This is a not infrequent picture; but the endometritis may be present without any marked displacement either downwards or backwards.

(b) Like the previous patient, this one says that she has never been well since her confinement, which was a difficult one, perhaps instrumental. She had 'child-bed fever' following the labour, and was very ill for months afterwards. On examination, the pelvic organs have lost their normal mobility and are tender to bimanual manipulation. There is thickening of the tubes and ovaries, or swelling and induration of the broad ligaments. The diagnosis is *pelvic inflammation following delivery*.

(c) The patient had a normal confinement, but shortly after resuming marital relations she began to suffer from pain in the vagina and a yellow discharge. She also had pain on passing water. On examination, we find the pelvic indications of the ravages of gonorrhœa. The diagnosis is *tubal disease*.

Secondary, like primary, sterility may be associated with retroversion or fibroids.

SYNOPSIS OF CASES OF STERILITY.

Leading Symptom.	Associated Symptoms.	Physical Signs.	Diagnosis.
1. PRIMARY STERILITY	<p>(a) None</p> <p>(b) Menstruation scanty and irregular or absent</p> <p>(c) Dyspareunia or incomplete coitus</p> <p>(d) Intercourse has not been possible; primary amenorrhœa</p> <p>(e) Dysmenorrhœa without dyspareunia; (obesity)</p> <p>(f) Backache; dysmenorrhœa; leucorrhœa</p> <p>(g) Xanthorrhœa after marriage; menorrhagia; painful micturition; pelvic pain (dyspareunia)</p> <p>(h) Menorrhagia and metrorrhagia; pressure symptoms</p> <p>(i) Ill-health since confinement; back-ache, leucorrhœa, menorrhagia</p> <p>(j) Illness since difficult confinement, with puerperal fever</p> <p>(k) History of gonorrhœa contracted after confinement</p>	<p>Normal</p> <p>(i.) Vulva and vagina normal; uterus small</p> <p>(ii.) Vulva normal or under-developed, uterus rudimentary</p> <p>(i) Hymen rigid and unyielding; pelvic organs normal</p> <p>(ii.) Vaginal spasm; organs normal</p> <p>(iii.) Doubling of genital canal</p> <p>Vagina absent or occluded by a septum; or pseudo-hermaphroditism</p> <p>Cervix small and conical; os small; acute ante flexion of the fundus</p> <p>Fundus acutely retroflexed in pouch of Douglas</p> <p>Swelling or enlargement of tubes; fixation of the uterus</p> <p>Uterus hard, large, smooth, or irregular and knobby</p> <p>Laxity of vagina; uterus low, large, with erosion; perhaps retroversion</p> <p>Fixation of pelvic organs; swelling of tubes or broad ligaments</p> <p>Pelvic signs of tubal disease</p>	<p>Sexual incompatibility or defective ovulation</p> <p>Under-developed or infantile uterus</p> <p>Rudimentary uterus</p> <p>Incomplete coitus from rigid hymen</p> <p>Incomplete coitus from vaginismus or vaginal stenosis</p> <p>Incomplete coitus from double vagina</p> <p>Absence or atresia of the vagina</p> <p>Stenosis and ante flexion</p> <p>Retroflexion and version</p> <p>Pyosalpinx, hydrosalpinx, tubo-ovarian cyst or abscess, or chronic salpingitis</p> <p>Uterine fibromyoma</p> <p>Endometritis and prolapse</p> <p>Pelvic inflammation following labour</p> <p>Tubal disease</p>
2. SECONDARY STERILITY			

## CHAPTER XV

### LEADING SYMPTOM : REPEATED ABORTIONS

REPEATED abortions were formerly spoken of as if aborting were a habit to which some women were addicted. Now it is customary to regard repeated abortions as an indication of some pathological condition. Occasionally, however, we may be baffled in our attempt to explain the recurrence of the accident until we discover that it is due to a resort to criminal procedures.

The following types are met with :

(a) The patient states that her first two or three pregnancies resulted in abortion, although each successive pregnancy lasted longer than the previous one, and perhaps the last one resulted in a still-born child at full time. On inquiry, we ascertain that two or three months after marriage the patient suffered from a bad sore throat and a rash, and that her hair started falling out. On examination, the pelvic organs may be normal, or we may find a condition of endometritis, as indicated by enlargement of the uterus, erosion of the cervix, and a muco-purulent discharge. The diagnosis is *acquired syphilis*, with, perhaps, a *syphilitic endometritis*.

(b) The history of abortions is in the inverse order to that found in the previous type—that is to say, the first pregnancy resulted in the birth of a healthy, living child.



This was followed by a still-birth at term, and this in turn by repeated abortions, the duration of pregnancy becoming progressively shorter. The abortions have usually taken place without difficulty, in marked contrast to the difficulties in the way of retained and adherent placenta, which are characteristic of syphilitic abortions (Taylor). Either the patient or her husband gives a 'strumous' history. On examination, the pelvic organs appear normal. The diagnosis is *recurrent abortion, due to tuberculosis*.

(c) The abortions may or may not have followed the birth of a living child, but the series was inaugurated by either a confinement or a miscarriage associated with retained products of conception, and followed by menorrhagia. The patient complains of pelvic pain, backache, leucorrhœa, menorrhagia, etc. On examination, the uterus is bulky, the cervix is thickened, and probably the seat of 'erosion.' On dilating the cervical canal, the endometrium is thickened and spongy; perhaps an old fragment of placental tissue is found. The diagnosis is *endometritis*.

(d) The abortions have followed the birth of a child at full time. The confinement may have been difficult, or the child very large. A characteristic feature of the abortions has been the facility with which the ovum has been expelled, perhaps with hardly any pain. On examination, a deep bilateral laceration of the cervix is discovered. The pelvic organs are otherwise normal. The diagnosis is *laceration of the cervix*.

(e) We shall only briefly touch on the fact that a patient complaining of repeated abortion may present the symptoms and signs of a *uterine fibroid*. It is evident, however, that when a patient suffers from a tumour of this nature, such symptoms as pain and hæmorrhage are

more likely to lead her to seek advice than the fact of repeated abortions.

(*f*) Similarly, in those cases in which a patient miscarries repeatedly as the result of nephritis, other symptoms than repeated abortion are complained of in the first instance.

SYNOPSIS OF CASES OF REPEATED ABORTION.

Leading Symptom.	Associated Symptoms.	Physical Signs.	Diagnosis.
<p>REPEATED ABORTION</p>	<p>(a) Early abortion with pregnancies lengthening up to full time : history of sore throat, rash, falling hair, etc.</p>	<p>Pelvic organs normal or signs of endometritis</p>	<p>Syphilis</p>
	<p>(b) Early full-time pregnancies followed by abortions becoming progressively earlier, strumous history</p>	<p>Pelvic organs normal (signs of tuberculosis elsewhere)</p>	<p>Recurrent abortion due to tuberculosis</p>
	<p>(c) Abortion inaugurated by a delivery with retained placenta, etc. : pelvic pain, leucorrhoea, menorrhagia</p>	<p>Uterus bulky, cervix thickened, with 'erosion' : muco-pus</p>	<p>Endometritis</p>
	<p>(d) Abortions follow a full-time confinement, and are markedly easy, the ovum 'falling out'</p>	<p>Cervix is widely and deeply torn on both sides</p>	<p>Laceration of the cervix</p>
	<p>(e) Symptoms of fibroids</p>	<p>Signs of fibroids</p>	<p>Uterine fibroids</p>
	<p>(f) Symptoms of nephritis</p>	<p>Albuminuria and signs of nephritis</p>	<p>Nephritis</p>

## CHAPTER XVI

### LEADING SYMPTOM: BEARING DOWN

By 'bearing down,' patients generally mean either a feeling that the pelvic contents are falling out through the vagina, or a feeling that there is a foreign body in the vagina inducing the necessity of straining or bearing down so as to expel it. Patients complaining of this symptom state, not infrequently, as we shall see, that 'the womb comes down,' or that there is 'falling of the womb.' By this they mean that something projects from the vagina. They do not necessarily mean the uterus, for the popular conception of 'the womb' is not the uterus of anatomists, but anything from the vaginal orifice to the whole belly. Bearing down is a leading symptom in a variety of clinical types and anatomical conditions, which we shall now review :

(a) The patient is a single woman, or a married nullipara. Menstruation is normal, and it may be that bearing down or falling of the womb is the only thing complained of. On examination—

(i.) The cervix may be found presenting at the vaginal orifice, or projecting as much as 2 or 3 inches beyond the vulva. In a virgin the hymen may be intact, or it may be stretched by the pressure of the cervix against it. The vagina may be the normal length, the cervix filling the

whole of it (Fig. 11), or, in marked cases, where the cervix projects far, the vagina may share in the prolapse, and so show an apparent shortening, as in Fig. 13. On passing the sound, it is found to enter the uterus for a distance of 4 to 6 inches. Bimanual examination shows that the enlargement of the uterus involves only its length, not its breadth. The fundus may be high up, in its normal position, or, in marked cases, it shares in the general downward trend. The diagnosis is *congenital hyperplasia of the vaginal portion of the cervix*.

(ii.) The superficial appearance is as just described, and the uterine cavity is lengthened, but the vaginal portion of the cervix presents the normal proportions, as indicated by the position on it of the vaginal reflection and the attachment of the bladder, whilst the vagina shows a marked apparent shortening (Fig. 12). The diagnosis is *hyperplasia of the supravaginal portion of the cervix*.

(b) The patient is probably a parous woman, though occasionally this type is found in a nullipara. Menstruation is normal, or slightly increased in quantity. There is aching in the pelvis, backache, and perhaps leucorrhœa. On examination—

(i.) The cervix is low in the vagina, or presents at the vulva. The vagina appears to be shortened. In marked contradistinction to the previous group, the length of the uterine canal is only slightly above the normal. The fundus takes the normal forward direction. The diagnosis is *prolapse of the uterus*.

(ii.) The physical signs are those just enumerated, except that the fundus of the uterus is very much retroverted. The diagnosis is *prolapse and retroversion*. We may here observe that retroversion is usually the first stage in prolapse, and therefore the combination of the two conditions is the one most frequently found. In order that a uterus

may become prolapsed, and yet preserve its normal direction, the pelvis must be unusually roomy.

(c) The patient is a parous woman, and complains of falling of the womb. She has probably been torn in one of her confinements. She may complain of frequency of micturition, or of inability to hold her water, or she may have difficulty in passing water, saying that she has to push something back before she can empty the bladder.

On examination, we find—

(i.) There is a marked bulging of the anterior vaginal wall, especially on straining. It may form an ovoid swelling the size of a turkey's egg. The diagnosis is *cystocele*.

(ii.) The bulging affects the posterior vaginal wall, and there is a considerable deficiency of the perineum. The diagnosis is *rectocele*. We may note that in this condition the patient does not complain of bladder symptoms.

(iii.) There is a combination of the two conditions just described. The diagnosis is *cystocele and rectocele*.

(iv.) In addition to the prolapse of the vaginal walls, the uterus lies low in the vagina. The diagnosis is *prolapse of the uterus, with cystocele and rectocele*, a condition which is also described as prolapse of the uterus and vagina, or, in the phraseology of the Edinburgh school, hernia of the displaceable portion of the pelvic floor.

(d) The patient is a parous woman, who complains of falling of the womb, and of a swelling which lies constantly between her legs. On examination, it is found that the vagina is turned inside out, forming a swelling of variable size, of which the lowest portion consists of the cervix. Not uncommonly there are circular or oval clean-cut ulcerated patches on the exposed surface, and the vaginal walls, instead of being soft and moist, are hard,

dry, and pale, resembling skin. This condition is a further stage of that last described, and the diagnosis is *procidentia totalis*.

(e) The patient, a parous woman, complains of bearing-down pain, and perhaps of falling of the womb, with pain in the pelvis generally, and backache, discharge, and slight, almost constant, bleeding. On examination, the vagina is occupied by a reddish, rounded, shaggy swelling, which can be traced up to the external os, or, in extreme cases, becomes lost on the vaginal wall all round, without any trace of a cervical canal being present. This swelling may lie partly outside the vulva. Careful inspection shows that its surface bears a resemblance to the uterine mucosa, and that near the most prominent portion two minute orifices can be seen, one on each side. Bimanual examination, especially under an anæsthetic, shows that the upper part of the swelling is not prominent and rounded, like the uterine fundus, but presents a conical or a cup-shaped depression. The diagnosis is *chronic inversion of the uterus*.

(f) The patient is a nullipara, or, at any rate, a woman who has not been pregnant for several years. In addition to bearing down, she complains of excessive loss at the monthly periods. There may be no other symptoms, or she may also have pain in the pelvis, and bladder disturbance. On examination—

(i.) A smooth, rounded swelling is found in the vagina, varying in size from a cricket-ball to a foetal head. If of moderate size, it can be traced up to a pedicle lying in the cervical canal; if large, it may so fill up the vagina that its upper pole cannot be reached. The diagnosis is *uterine fibroid extruded into the vagina*.

(ii.) In rare cases we may find a condition similar to that just described; but, in addition, on bimanual examination, the normal rounded fundus of the uterus is

replaced by a concavity. The diagnosis is *extruded uterine fibroid*, with *inversion of the fundus*. As a matter of fact, there would probably be great difficulty in diagnosing such a condition prior to operation.

(g) Another rare type is that in which a woman complains of bearing down and of an offensive discharge; and, on examination, a foreign body is found in the vagina, consisting either of something introduced previously by the patient or of a forgotten pessary, of whose existence the patient was perhaps not aware. The diagnosis is *foreign body in the vagina*.



**SYNOPSIS OF CASES OF BEARING DOWN.**

Leading Symptom.	Associated Symptom.	Physical Signs.	Diagnosis
<b>BEARING DOWN</b>	<p>(a) Patient single, or nullipara; no symptoms or 'falling of the womb'</p> <p>(b) Parous woman; aching in back and pelvis; leucorrhœa</p> <p>(c) Parous woman; 'falling of the womb'; history of tear at confinement; bladder symptoms</p> <p>(d) Parous woman; 'falling of the womb'; swelling between the legs</p> <p>(e) Parous woman; pain in back and pelvis; discharge; almost constant bleeding</p> <p>(f) Nullipara; menorrhagia; perhaps pain in pelvis and bladder troubles</p> <p>(g) Offensive discharge</p>	<p>(i.) Cervix greatly lengthened, and protruding at the vulva or protruding; vagina normal length; uterus much elongated</p> <p>(ii.) As above, but vagina apparently shortened and vaginal cervix normal length</p> <p>(i.) Cervix low in vagina; uterus normal length; fundus in normal direction</p> <p>(ii.) As above, but fundus retroverted</p> <p>(i.) Bulging of anterior vaginal wall</p> <p>(ii.) Bulging of posterior vaginal wall</p> <p>(iii.) Bulging of anterior and posterior vaginal walls</p> <p>(iv.) Bulging of vaginal walls; uterus low in vagina</p> <p>Uterus and vagina lying outside the vulva</p> <p>Reddish shaggy swelling in the vagina, bleeding readily, with orifices of Fallopian tubes visible; cup-like depression above it felt bimanually</p> <p>(i.) Smooth rounded swelling in vagina, perhaps filling it; tumour has pedicle passing up into the uterus; fundus normal, or with fibroids</p> <p>(ii.) As above, but normal fundus replaced by cup-shaped depression</p> <p>Pessary or other foreign body in the vagina</p>	<p>Hyperplasia of vaginal portion of cervix</p> <p>Hyperplasia of supra-vaginal portion of cervix</p> <p>Prolapse of the uterus</p> <p>Prolapse and retroversion of the uterus</p> <p>Cystocele</p> <p>Rectocele</p> <p>Cystocele and rectocele</p> <p>Prolapse of uterus and vagina</p> <p>Total procidentia</p> <p>Chronic inversion of the uterus</p> <p>Uterine myoma extruded into the vagina</p> <p>Extruded uterine myoma with inversion of the uterus</p> <p>Foreign body in the vagina</p>

## CHAPTER XVII

### LEADING SYMPTOM: BOWEL OR BLADDER DISTURBANCE

DISTURBANCE of the bowels or bladder is sometimes a prominent symptom in the diseases of women, and must accordingly find a place in our review of leading symptoms. We shall consider the bowels and bladder separately.

**A. Bowel Disturbance.**—This is met with in several forms.

1. *Pain on Defæcation.*—We need not here discuss painful defæcation in its relation to rectal disease, but shall rather assume that the intestinal tract is healthy. Two principal types are then found.

(a) The associated symptoms complained of are more or less constant iliac pain, probably referred to the left side, and dyspareunia. The patient feels well otherwise. On examination, the uterus is normal; the left ovary is prolapsed, very tender, and slightly enlarged. The diagnosis is *prolapsed and cystic ovary*.

(b) In this case, also, there may be dyspareunia; but the chief associated symptoms are backache, leucorrhœa, and a moderate degree of menorrhagia. On examination, the uterus is sharply retroflexed and verted; the ovaries are probably also prolapsed. The diagnosis is *retroflexion of the uterus*.

(c) The patient complains of considerable pelvic pain, and of xanthorrhœa; there is a history of painful micturition, following on an attack of gonorrhœa. There may be a rise of temperature. On examination, the uterine appendages are enlarged so as to form a considerable swelling on both sides of the uterus (especially the left) and behind it. The mobility of the uterus is impaired or abolished. The diagnosis is *inflammatory disease of the uterine appendages*.

(d) The symptoms probably date from a recent confinement, following which the patient was very ill. She is still febrile, and has much pain in the pelvis, especially the left side. On examination, the uterus is fixed; to the left of it there is a considerable swelling in the situation of the left broad ligament, with brawny induration of the vaginal vault. The diagnosis is *pelvic cellulitis* or *pelvic abscess*.

2. *Constipation*.—Inasmuch as the majority of women suffer from constipation, it is evident that we cannot attach much importance to it as a gynæcological symptom. Nevertheless, there are some cases in which constipation is directly due to, or aggravated by, disease of the genital organs, and therefore we must glance at them here. We shall not go fully into these cases, because, as a rule, other symptoms are more prominent.

(a) The patient has backache, leucorrhœa, and menorrhagia; she has a difficulty in passing her motions, 'as if something were in the way.' On examination, a large retroverted fundus is found pressing on the rectum. The diagnosis is *retroversion of the uterus*.

(b) There is a general pelvic pain, and perhaps menorrhagia and symptoms of pressure on the bladder. On examination—

(i.) A hard fibroid tumour of the uterus is found impacted in the pelvis. The tumour may occupy the

retroverted body of the uterus, or it may be a pedunculated myoma lying in the pouch of Douglas or occupying the broad ligament, or a large cervix-fibroid filling up the pelvis. The diagnosis is *impacted uterine fibroid* or *cervix-fibroid*.

(ii.) The uterus is normal ; by the side of it or behind it is a tense cystic swelling jammed in the pelvis. The diagnosis is *impacted ovarian tumour*.

(iii.) The mass in the pelvis is an inflammatory one, consisting of the uterine appendages, an abscess situated in the broad ligament, or a circumscribed intraperitoneal abscess. The diagnosis is *pelvic inflammation*.

3. *Incontinence of Fæces*.—(a) The patient gives a history of inability to control her motions, dating from a confinement ; she may have had a very difficult labour, and perhaps tells us that she was badly torn. She also suffers from bearing down, or from falling of the womb. On examination, the perineum is found torn right through the rectum. There may be also a cystocele, rectocele, or prolapse of the uterus. The diagnosis is *complete rupture of the perineum*.

(b) The incontinence is not constant, but troubles the patient whenever the motions are loose ; she also frequently passes flatus by the vagina. There may be a history of a difficult labour, with rupture of the perineum, which failed to unite completely. On examination, a communication between the vagina and rectum is found. The diagnosis is *recto-vaginal fistula*.

(c) The rectal symptoms are as in the last case, but they have no relation to a confinement. The patient has suffered for some time from irregular hæmorrhage, offensive vaginal discharge, and pain in the pelvis. On examination, a carcinomatous ulcer is found, arising from the posterior lip of the cervix or from the posterior

vaginal wall; the ulcer has perforated through into the rectum. The diagnosis is *carcinoma of the cervix or vagina ulcerating into the rectum*.

**B. Bladder Disturbance.**— This also takes several forms.

1. *Painful Micturition.*— There are various troubles of the urinary organs, in which pain occurs on passing water, such as cystitis, a stone or other foreign body in the bladder. These are mentioned here in order that they may be borne in mind when investigating a case; but as we are now considering urinary symptoms only in their relation to genital disorders, we need not dwell on them. We have to notice three types of painful micturition.

(a) There are no associated symptoms; or perhaps there is a little blood-stained discharge at times, or a little bleeding after coitus. On examination, a red, tender swelling is found at the urethral meatus, arising from the lower part of the posterior wall of the urethra. The diagnosis is *urethral caruncle*.

(b) The pain on micturition began with the appearance of a profuse yellow discharge from the vagina, of recent date. On examination, the vaginal walls are reddened and bathed in pus; a drop of pus can be pressed out of the urethra. The orifices of the Bartholinian ducts are red and stand out prominently, and a droplet of pus may escape on pressing the gland and duct. The diagnosis is *gonorrhœa*.

(c) The patient has suffered for some time from an offensive, watery, vaginal discharge and irregular hæmorrhage; there is pain in the pelvis. On examination, the cervix or vagina is the seat of a carcinomatous growth spreading anteriorly so as to invade the base of the bladder. The diagnosis is *carcinoma of the cervix or vagina, invading the bladder*.

2. *Frequent Micturition.*—(a) In the first type met with there are no associated symptoms; or at most there is a little backache and general lassitude. On examination—

(i.) The pelvic organs appear quite normal, or at most there is a little uterine congestion; the bladder appears normal. We must then make a speculative diagnosis of *bladder irritability of functional origin or due to pelvic congestion.*

(ii.) The genital organs are normal; the bladder is contracted, as shown by its incapacity for moderate distension, even under anæsthesia. The diagnosis is *contracted bladder.*

(b) The patient has bearing-down pain, or falling of the womb, and perhaps complains of backache or leucorrhœa. On examination, we find—

(i.) A large retroverted uterus, the cervix of which is drawn forwards and upwards, and lies in contact with the base of the bladder. The diagnosis is *retroverted and enlarged uterus.*

(ii.) The uterus lies low in the vagina, and encroaches on the space required by the bladder in the pelvis. The diagnosis is *prolapse of the uterus.*

(iii.) The anterior vaginal wall bulges downwards, especially when the patient stands or strains. The diagnosis is *cystocele.*

(iv.) The uterus and vaginal walls lie outside the vulva. The diagnosis is *procidencia totalis.*

3. *Retention of Urine, preceded by Frequency of Micturition.*—We have to consider here a group of cases in which a swelling in the pelvis of moderate size first causes frequency of micturition due to irritation of the base of the bladder; when the swelling gets larger, it leads to complete retention of urine, due to the fact that the

urethra and the base of the bladder are actually compressed between the swelling and the pubes.

(a) The patient has not menstruated for three or four months; she is sick in the mornings, and has other symptoms of pregnancy. She has had a good deal of backache and bearing down. On examination, the uterus is enlarged to the size of a pregnant uterus, corresponding to the term of amenorrhœa; the fundus occupies the hollow of the sacrum, the cervix is drawn high up behind the pubes. On examination of the abdomen, a dull pyriform swelling rises from the pubes to the umbilicus; the passage of a catheter proves that this is the distended bladder. The diagnosis is *retroversion of the gravid uterus*.

(b) The patient presents some symptoms of pregnancy; the last normal menstruation was three or four months previously, but for the last six weeks there has been a slight, almost constant 'show' of blood forming a brownish discharge; or there may have been such a discharge for a few days only. The discharge was ushered in by an attack of pain, more marked on one side, and the patient thought she was going to have a miscarriage. The retention has come on during the last day or two. On examination, a swelling of moderately firm and rather 'doughy' consistence fills up the hollow of the sacrum, and pushes the vagina forwards. On attempting to push it up into the abdomen, it 'pits' slightly, but cannot be moved. The cervix is high up, behind the pubes; it is not so soft as the normal cervix of pregnancy. On careful bimanual examination, especially under an anæsthetic, a swelling like the normal uterine fundus is felt a little to one side above the pubes, and continuous with the cervix. A sound passed into the uterus enters only  $2\frac{1}{2}$  to 3 inches. The diagnosis is *extra-uterine pregnancy*, with the gestation sac lying wholly or partly in the pouch of Douglas.

(c) The patient suffers from weight in the pelvis and bearing down; she has probably been subject to menorrhagia for some months or a year or two. She has noticed that the retention of urine has coincided with the onset of the last two or three monthly periods; in the intervals of menstruation she has no retention, but, on the contrary, suffers from great frequency of micturition. On examination, a hard tumour connected with the uterus is found almost completely filling the pelvis. The diagnosis is *impacted uterine fibroid*.

4. *Incontinence of Urine*.—This is met with in three principal types:

(a) The patient is a young girl, just in her 'teens,' or younger. The mother says that she wets the bed at night. This is not properly a gynæcological condition. On examination, the pelvic organs would be found to be normal, and for our present purpose we may rest content with a diagnosis of *enuresis nocturnæ*.

(b) The patient complains that at times she is unable to hold her water, especially when she is out walking. She suffers constantly from bearing down, and perhaps from falling of the womb. On examination, there is bulging of the anterior vaginal wall, which comes down so as to form a swelling the size of an egg. The uterus may be prolapsed and the perineum deficient. The diagnosis is *cystocele*.

(c) The incontinence is constant, and takes the form of a continual slight dribbling of urine. On examination, a fistulous communication is discovered between the bladder or urethra, and the uterus or vagina. For fuller details of the methods of distinguishing between the different kinds of fistula, the reader is referred to Chapter XI., 6. The diagnosis is *vesico-vaginal fistula*, or one of the other varieties described.



5. *Passage of Flatus through the Bladder.*—This is a very rare condition, and when the occurrence is verified, it necessarily indicates that the bladder communicates with some portion of the intestinal tract, either directly, or by means of an intervening abscess cavity; or that the bladder communicates with an abscess containing gas-producing bacilli. As a rule, a swelling will be found in the pelvis, either on one side of the bladder or behind it; but it will almost certainly be impossible to make out the exact state of things except by resorting to an abdominal operation.

I have met with two instances in which this distressing symptom was present. One was a patient whose appendages I removed for tuberculous salpingitis; for a short time after the operation she had a fæcal fistula. It was presumed that she developed an abscess, probably tuberculous, communicating with the bladder, and with some portion of the bowel; but she gradually got quite well without resort to further operation. The other patient had a large swelling on the right side of the pelvis; at the operation she was found to have a thick-walled abscess, communicating with two portions of intestine—namely, the ileum and the cæcum. The abscess wall was dissected out, and the two holes in the bowel were sewn up, and she recovered without further bladder trouble. The actual communication with the bladder, which we must presume to have existed, was not discovered during the operation.

## SYNOPSIS OF BOWEL AND BLADDER DISTURBANCES.

Leading Symptom.	Associated Symptoms.	Physical Signs.	Diagnosis.
A. BOWEL DISTURBANCE			
1. Pain on Defaecation	(a) Iliac pain; dyspareunia (b) Backache; leucorrhœa; menorrhagia; dyspareunia (c) Pelvic pain; xanthorrhœa; rise of temperature (d) Pelvic pain; rise of temperature; history of recent confinement (a) Backache; leucorrhœa; menorrhagia (b) Pelvic pain; pressure on bladder; probably menorrhagia	Left ovary prolapsed and cystic Uterus retroflexed; probably ovaries prolapsed Fixation of the uterus, with a tender swelling on each side Tender swelling in left broad ligament; induration of vaginal vault Uterus large, retroverted (i.) Hard fibroid tumour of uterus, cervix, or broad ligament (ii.) Uterus normal; tense cystic swelling in the pelvis (iii.) Inflammatory mass in the pelvis Perineum torn through into the rectum	Prolapsed cystic ovary Retroflexion of the uterus Inflammatory disease of the appendages Pelvic cellulitis or pelvic abscess Retroversion of the uterus Impacted uterine myoma or cervix myoma Impacted ovarian tumour Pelvic inflammation Complete rupture of the perineum
2. Constipation			
3. Incontinence of Fæces	(a) Bearing down; falling of womb; symptoms date from a difficult labour		

<p>(b) Incontinence when motions are loose ; passage of flatus through the vagina ; history of difficult labour</p> <p>(c) Incontinence as in last case ; irregular hæmorrhage ; watery, offensive discharge</p>	<p>Fistulous communication between rectum and vagina</p> <p>Carcinomatous ulcer on posterior vaginal wall, opening into the rectum</p>	<p>Recto-vaginal fistula</p> <p>Carcinoma of cervix or vagina, ulcerating into the rectum</p>
<p>(a) None, or slight blood-stained discharge, or bleeding after coitus</p> <p>(b) Symptoms date from appearance of a yellow discharge</p> <p>(c) Irregular hæmorrhage ; offensive watery discharge ; pelvic pain</p> <p>(a) None</p>	<p>Urethral caruncle</p> <p>Vagina inflamed and bathed in muco-pus ; urethritis</p> <p>Carcinomatous growth spreading anteriorly</p> <p>(i.) None (ii.) Pelvic organs normal ; bladder contracted</p> <p>(i.) Uterus large and retroverted (ii.) Uterus large, lying low in the vagina (iii.) Bulging of anterior vaginal wall (iv.) Uterus and vagina lie outside the vulva</p>	<p>Urethral caruncle</p> <p>Gonorrhœa</p> <p>Carcinoma of cervix or vagina invading the base of the bladder</p> <p>Contracted bladder</p> <p>Retroverted enlarged uterus</p> <p>Prolapse of the uterus</p> <p>Cystocele</p> <p>Procidencia totalis</p>
<p>(b) Bearing down ; falling of the womb ; backache ; leucorrhœa</p> <p>(c) Earlier stages in the cases in the next group</p>		

B. BLADDER DISTURBANCE  
1. Painful Micturition

2. Frequent Micturition

SYNOPSIS OF BOWEL AND BLADDER DISTURBANCES—*continued.*

Leading Symptom.	Associated Symptoms.	Physical Signs.	Diagnosis.
B. BLADDER DISTURBANCE <i>continued</i> 3. Retention of Urine	(a) Three to four months' amenorrhœa; symptoms of pregnancy; backache (b) Amenorrhœa, followed by scanty brownish discharge; pain on one side (c) Bearing-down; weight in the pelvis; menorrhagia; retention coincides with menstruation	Bladder distended and reaching to umbilicus; pregnant uterus lying in hollow of sacrum Uterus pushed up against pubes; doughy swelling filling up the pelvis Hard uterine tumour filling the pelvis	Retroversion of the gravid uterus Extra-uterine pregnancy Impacted uterine myoma
4. Incontinence of Urine	(a) None; enuresis is at night only (b) Bearing down; falling of the womb; enuresis is not constant (c) Incontinence is constant, the urine escaping from the vagina	None Bulging of anterior vaginal wall	Enuresis nocturnæ Cystocele
5. Passage of flatus through the vagina	Various	Fistulous communication between ureter, bladder, or urethra, and uterus or vagina Various	Vesico-vaginal or other fistula Fistula between bowel and bladder, or abscess communicating with bowel and bladder

## CHAPTER XVIII

### LEADING SYMPTOM: SWELLING OF THE VULVA

PATIENTS sometimes come complaining of a swelling 'in the privates' or 'between the legs'; and this symptom covers about a score of different conditions. There may or may not be associated symptoms; and from the point of view of diagnosis, symptoms are here of very little importance, because as a rule an inspection of the vulva is sufficient to establish the diagnosis. It will be convenient, however, as a matter of systematic investigation, to consider the cases in groups, according to the presence and nature of the associated symptoms.

(a) In the first group there are no associated symptoms at all; the patient is merely conscious that there is a swelling which should not be there; at the most she suffers a little inconvenience or discomfort from it when she is sitting down or walking. On inspection of the vulva, we find one of the following conditions present:

(i.) A sessile tumour is present in the labium majus or the mons veneris. It is of doughy consistence, more or less lobulated; the skin pits on puckering it up over the swelling. The diagnosis is *lipoma of the vulva*.

(ii.) A pedunculated tumour hangs from the labium majus, or, more rarely, from the labium minus; it is soft and flabby in consistence. Occasionally one or more of

such tumours may spring from the vestibule, with long slender pedicles. The diagnosis is *fibromyxoma of the vulva*.

(iii.) A hard, smooth tumour is embedded in the substance of the labium majus, or hangs therefrom by a pedicle. There is no sign of ulceration or inflammation about it, and, if it is sessile, the skin moves over it. The diagnosis is *fibroma of the vulva*.

(iv.) The vulva is the seat of one or more warty growths, similar to warts elsewhere. The diagnosis is *papillomata of the vulva*.

(v.) The clitoris or labia, or both, are greatly enlarged, the skin over the swollen portions is pale and thickened, and rugose like the rind of an orange. The diagnosis is *elephantiasis of the vulva*.

(vi.) A smooth, rounded, or ovoid swelling occupies the upper and outer portion of the labium majus, in the direction of the inguinal canal. It presents no impulse when the patient coughs or strains; it does not vary in size; it feels tense, and may have a slight lateral mobility. The diagnosis is *hydrocele of the canal of Nuck*.

(vii.) A portion or the whole of the vulva is swollen and pale, pitting on pressure; the swelling affects especially the prepuce clitoridis and the labia minora, and, in extreme cases, the mons veneris and labia majora share in the process, until a swelling the size of a foetal head may be present. In some cases one side only is affected. The diagnosis is *œdema of the vulva*.

(viii.) A small, firm, or hard swelling is present in the situation of the clitoris, or on some portion of the labia majora. The skin is involved in the swelling and shows a tendency to ulceration. The diagnosis is *early carcinoma of the vulva*.

(ix.) The swelling occupies the lower part of one or

other labium majus. It is smooth, tensely cystic, of a rounded or ovoid shape. It can be readily grasped between a finger in the vagina and the thumb placed outside the labium majus, and it can be felt to be connected with the orifice of the Bartholinian duct. The skin over it is pale and non-adherent. The diagnosis is *Bartholinian cyst*.

(b) The swelling is a painful one, and is associated with more or less discharge of pus or muco-pus from the vagina. The symptoms have been present for some days only, or for a week or two. There is pain on sitting and walking. On examination, we find—

(i.) One or more hard swellings with ulcerated surface, situated especially about the labia minora, but also on other parts of the vulva. The vagina has a purulent discharge; there are painful and enlarged glands in the groins. The diagnosis is *chancroids of the vulva*.

(ii.) The vulva and parts surrounding it are covered with flattened circular or oval raised patches, with a moist or 'weeping' surface. The discharge from these patches is of a sero-purulent character. The patches tend to merge into one another. The diagnosis is *condylomata of the vulva*.

(iii.) The lower part of the labium majus on one side is the seat of a tender painful swelling, of spherical or pyriform shape; the skin over the swelling is inflamed and adherent, vulvo-vaginitis is also present. The orifice of the Bartholinian duct is red and prominent. The diagnosis is *abscess of the Bartholinian duct*.

(c) The patient complains of bearing down and falling of the womb, and states that the swelling comes down in the front passage. She may have bladder symptoms in the form of frequency of micturition, difficulty in passing water, or inability to hold the water when walking, cough-

ing, or straining in any way. The following conditions may be found on examination :

(i.) There is a bulging of the anterior or posterior vaginal walls, or both. When the patient strains, the bulging may form a swelling the size of a hen's egg. The uterus will probably, but not necessarily, be found low down in the vagina. The diagnosis is *cystocele* or *rectocele*, with perhaps *prolapse of the uterus* in addition.

(ii.) The cervix is found outside the vulva, dragging down with it the vaginal walls. The uterus is more or less elongated. According to the position of the fundus, whether low down in the pelvis or about in its normal position, the diagnosis is *procidentia totalis* or *hyperplasia of the supravaginal portion of the cervix*, or, if the length of the vagina is undiminished, the diagnosis is *hyperplasia of the vaginal portion of the cervix*.

(iii.) A rounded, reddish, shaggy swelling protrudes from the vagina ; the uterine orifices of the Fallopian tubes can be distinguished on it. On bimanual or recto-abdominal examination, the fundus of the uterus is found to be absent, being replaced by a concavity above the cervix. The diagnosis is *inversion of the uterus*.

(iv.) A smooth rounded swelling projects from the vulva ; it has a long pedicle, which can be traced up till it disappears in the cervical canal. The fundus of the uterus can be felt in its normal position, probably enlarged. The diagnosis is *pedunculated uterine fibromyoma*.

(v.) A pale rounded cystic swelling presents at the orifice of the vulva ; it is found to originate in the anterior vaginal wall, to one or other side of the middle line ; it has no pedicle, but lies sessile on the wall of the vagina. In all probability one or more similar swellings can be felt higher up in the vagina. The diagnosis is *vaginal cyst*.



(d) The patient states that she has a swelling at one side of the vulva, which is most marked when she has been standing for some time and in the evenings. After lying down, and when she gets up in the morning, she does not notice it. She has no pain from the swelling, but only a sense of dragging or fulness in the vulva. On examination, one of two conditions will be found :

(i.) A swelling occupies the upper part of the labium majus on one side, coming down into the labium from the direction of the inguinal canal. An impulse can be detected in it when the patient coughs. The swelling can be pressed backwards and upwards till it disappears, leaving an unduly patent inguinal ring. The diagnosis is *inguinal hernia*.

(ii.) The labium majus of one side is greatly distended ; the swelling is soft and compressible, and conveys to the touch the classical feeling of 'worms in a bag.' Greatly dilated veins can be seen on the surface of the swelling, as well as over the adjacent parts of the vulva and vagina. When the patient lies down the swelling almost entirely disappears ; when she stands it gradually fills and becomes tense. The whole vulva may be affected, and dilated tortuous veins may be seen going up over the mons veneris, and also extending down the thighs. In most cases it will be found that the patient has advanced several months in pregnancy. The diagnosis is *varix or varicocele of the vulva*.

(e) A patient who has a history of having suffered from such a swelling as we have just described has had an injury to the vulva from a fall, a blow, or the traumatism incidental to labour. Since then the swelling has been larger, harder, and painful. On examination, the labium is rather tensely distended, and looks red and congested ; or it may have the bluish-black appearance of a bruise. The

## SYNOPSIS OF CASES OF SWELLING OF THE VULVA.

Leading Symptom.	Associated Symptoms.	Physical Signs.	Diagnosis.
SWELLING OF THE VULVA	(a) None, or discomfort on sitting or walking	(i.) Sessile, doughy, lobulated swelling (ii.) Pedunculated, flabby, or soft swelling on labium or vestibule (iii.) Hard, smooth swelling imbedded in labium, or pedunculated (iv.) One or more warty growths (v.) Swelling of clitoris or labia; skin pale, thickened, rugose (vi.) Smooth, round, or ovoid swelling in upper part of labium; irreducible (vii.) Swelling of part or whole of the vulva; skin pale, pitting on pressure (viii.) Small, hard swelling of clitoris or labium; skin involved (ix.) Round or pyriform swelling in lower part of labium majus; smooth, cystic	Lipoma of the vulva Fibromyxoma of the vulva Fibroma of the vulva Papillomata of the vulva Elephantiasis of the vulva Hydrocele of the canal of Nuck Oedema of the vulva Early carcinoma of the vulva Bartholinian cyst

<p>(b) Swelling is painful; discharge of mucus from vagina</p>	<p>(i.) Hard ulcerated swellings on the vulva; enlarged tender glands (ii) Multiple flattened, raised patches, with discharging surface (iii.) Swelling in lower part of labium majus; skin reddened; vulvovaginitis</p>	<p>Chancroids of the vulva Condylomata of the vulva Bartholinian abscess</p>
<p>(c) Bearing down; falling of the womb; bladder symptoms</p>	<p>(i) Bulging of vaginal walls (ii.) Cervix protruding</p>	<p>Cystocele or rectocele Procidentia or hyperplasia of the cervix Inversion of the uterus</p>
<p>(d) Swelling varies in size, and disappears when lying down</p>	<p>(iii.) Rounded red, shaggy swelling protruding from vagina; orifices of Fallopian tubes (iv.) Smooth, pedunculated swelling protruding from vagina (v.) Pale cystic swelling in vaginal wall</p>	<p>Pedunculated uterine myoma Vaginal cyst Inguinal hernia Varix of the vulva</p>
<p>(e) History of varix; recent injury or confinement</p>	<p>(i.) Smooth swelling in upper part of labium; reducible</p>	<p>Hæmatoma of the vulva</p>
<p>(f) Swelling is painful, and bleeds</p>	<p>(ii.) Labium distended with enlarged veins Doughy swelling of labium; skin red or bruised-looking Hard ulcerated swelling on clitoris, labium, or vagina; enlarged inguinal glands</p>	<p>Carcinoma of clitoris, labium, or vagina</p>

swelling is firm or doughy in consistence. The diagnosis is *hematoma of the vulva*.

(f) The swelling of the vulva is associated with pain and bleeding, or instead of blood there may be a sero-sanguineous discharge. On examination, a hard ulcerated swelling is found on the clitoris, the labia, or presenting at the vaginal orifice. The inguinal glands are enlarged. The diagnosis is *carcinoma of the clitoris, labium, or vagina*.

## CHAPTER XIX

### LEADING SYMPTOM : SWELLING OF THE ABDOMEN

I HAVE discussed in Chapter VI. the interpretation of swellings that may be found in the abdomen. Many of those conditions are such that the patient is not cognisant of any enlargement of the abdomen, and therefore they are not dealt with here. I am now rather supposing that enlargement of the abdomen is a prominent symptom, which has attracted the patient's attention. We shall then have to differentiate the various conditions that may cause this symptom. As before, we shall open the inquiry by ascertaining what associated symptoms are present; and the first and most obvious question is this: Is the swelling associated with any alteration in the menstrual function? The cases will at once fall into three groups, according to whether menstruation is unaltered, absent, or increased.

1. **Menstruation is unaltered.** In this group we have a number of types.

(a) The patient has no symptoms at all beyond the swelling of the abdomen. She may be a single or married woman. In the latter case she may be sterile, or she may have had children. She may be any age from fifteen to fifty. On examination of the abdomen, it is found to be smoothly and uniformly distended, and the respiratory

movements of the abdominal wall are restricted, as in Fig. 8. The limits of the tumour are fairly easily defined on palpation. Above, the limit may be the umbilicus or higher, up to the ensiform cartilage. Probably a fluid thrill can be detected through the whole or a part of the swelling. On percussion, the front of the abdomen is absolutely dull. The dullness goes down towards the flanks, but the flanks themselves are resonant. Vaginal examination may fail to give any additional information, because the abdominal distension may preclude bimanual palpation; but, on the other hand, it may be possible to make out the uterus, distinct from the tumour, and either crowded down into the hollow of the sacrum, or pressed forwards against the pubes. The cervix is normal, and presents none of the softening characteristic of pregnancy. The breasts show negative signs. The diagnosis is *ovarian tumour*.

It may be possible to carry the diagnosis a little further. Thus, if the thrill obtained on palpation is felt readily all over the tumour, it is probably a unilocular cyst, in which case it is likely to be either a parovarian cyst, or a dermoid. Localized indurations of the surface would support the view that it was dermoid. If, on the other hand, the thrill is limited to certain areas, and the surface of the tumour is rather uneven or lobulated, we have probably to do with a true ovarian or multilocular cyst.

Further, it may be possible to determine the presence of a second tumour situated in the pelvis, or rising up into the abdomen on one side of the larger tumour. We should then make a diagnosis of bilateral ovarian cyst.

Two very different conditions may simulate an ovarian cyst so closely that a differential diagnosis cannot be made, and the nature of the case is evident only when the abdomen is opened. These are a *large hydronephrosis* and

*encysted or localized tuberculous hydroperitoneum.* A number of cases are on record in which one or other of these conditions was found when an operation was undertaken on the diagnosis of ovarian cyst. Either condition may be present without causing any symptoms or signs other than those produced by an ovarian cyst.

Sometimes, however, the diagnosis is relatively easy. For example, if a patient has been known to have a floating kidney, or presents a history of marked variations in the amount of urine passed at a time, or has passed considerably less urine than usual since the abdomen began to swell; or if a distinct note of resonance could be detected superficial to the tumour, the diagnosis of hydro-nephrosis would probably be correct. Or, if a patient showed signs of tuberculosis in the lungs, or was subject to night-sweats or rises of temperature, or looked tuberculous, or if the skin of the abdomen had the dry, harsh character sometimes found in cases of tuberculous peritonitis, the latter would be the correct diagnosis.

(b) The patient, as in the previous case, presents no symptoms other than enlargement of the abdomen. She is either single or a married nullipara, and her age is probably thirty to forty-five. On examination, a firm tumour is felt, situated in the lower part of the abdomen, and rising as high as the umbilicus or higher. It yields a quite dull percussion note, but conveys no fluid thrill nor cystic feeling. It has the dead resistance of a solid tumour. The breasts are negative. Vaginal examination shows that the tumour dips down into the pelvis. The uterus is distinct, but it may be possible to make out that the tumour appears to be attached to it.

Here we shall probably have to be content with a provisional diagnosis, for the case is one of *subserous (pedunculated) myoma, solid ovarian tumour, or myoma of the*

*round ligament.* If it be possible to palpate the ovaries accurately and determine that they are independent of the tumour, we can exclude solid ovarian tumour, but it must be remembered that a small subserous myoma situated laterally might be mistaken for an ovary, the latter being actually embodied in the tumour. Therefore the experienced surgeon will almost certainly refrain from a too positive diagnosis. I do not think that it is possible to make a confident diagnosis of a myoma of the round ligament.

These tumours, like ovarian cysts, are simulated by two very different conditions—namely, an *enlarged wandering spleen* and a *solid omental tumour*. A suspicion that the tumour was a wandering spleen might be excited if it presented on one of its borders the characteristic splenic notch; or if the spleen were found to be definitely absent from its normal situation (a point by no means easy to determine), or if the patient were found to be suffering from leucocythæmia. The diagnosis would be easy if the tumour had been previously felt in other situations, such as the left hypochondrium.

A solid omental tumour is in many cases of a malignant character, and if the patient had been losing flesh, or were known to have a malignant growth in the bowel or elsewhere, the probability of the abdominal tumour being omental would be suggested. But in the absence of such indications, the nature of the tumour would, in all probability, remain uncertain until the abdomen was opened.

(c) The patient complains of weight and dragging in the right hypochondrium, perhaps of pain in that situation. There may or may not have been jaundice. On examination, a swelling is felt occupying the right hypochondrium, and passing downwards to the umbilicus, or lower. No distinction between the tumour and the liver can be made



out. The lower margin of the tumour may be thickened and rounded, or it may be rather sharp, like the edge of the liver. The diagnosis is *hepatic enlargement*. I shall not enter into the question of the differential diagnosis of the forms and causes of hepatic enlargement, such as syphilis, carcinoma, hepatic or subdiaphragmatic abscess, etc., for such a case passes into the province of the physician or the surgeon.

(d) The patient states that she feels movements in the abdomen, and that she is getting gradually larger. She may state that she believes herself to be pregnant, although she admits that menstruation has occurred regularly and without interruption. She may be a young married woman, or she may have married late in life, or she may be approaching the age of the climacteric. On examination, the breasts are negative. The respiratory movements of the abdominal wall affect the abdominal contour right down to the pubes, as in Fig. 7. The abdominal wall shows a copious deposit of fat, and on percussion there is resonance over the whole abdomen. The note may, indeed, be tympanitic; and the patient admits that she suffers from flatulence. In some cases the abdomen appears distended, and feels hard on palpation. Nevertheless, the respiratory movements are as we have just described them, and on administering an anæsthetic the abdominal wall becomes soft and yielding. The diagnosis is *abdominal distension due to flatulence and obesity*, and if the patient firmly believes that she is pregnant, and presents the hardness and bulging of the abdominal wall just described, we may call it a case of *pseudo-cyesis*, or *phantom tumour*.

(e) The patient presents the symptoms and signs of cardiac or renal disease, or cirrhosis of the liver, or obstruction of the portal circulation. There may be œdema

of the face, or extremities. On examination, the abdomen is considerably distended, but as the patient lies on her back, the prominence of the middle portion of the abdomen is replaced by a bulging of the flanks, the flatness of the abdomen contrasting markedly with the protrusion found in cases of tumour. If one wanted a comparison, one might liken such an abdomen to the appearance of the abdomen of a supine female frog just before spawning-time. On palpation, no definite swelling is found; the respiratory contour of the abdomen is that shown in Fig. 7. On percussion, a resonant note is elicited over the anterior portion of the abdomen, especially in the neighbourhood of the epigastrium and umbilicus. The flanks are quite dull, and the dulness may invade the suprapubic region. The line of demarcation between the dull and resonant areas is curved or crescentic, with the concavity upwards, in sharp contrast to the corresponding line in the case of a tumour, which has a convexity upwards. The area of dulness varies with the position of the patient; when she is lying on one side the flank which is uppermost becomes resonant, and a part of the area previously resonant becomes dull. The diagnosis is *ascites*.

(f) The patient has become larger in the abdomen, but has lost flesh on the chest and limbs. She has a cachectic appearance. On examination, we find—

(i.) Physical signs such as those just described as being characteristic of ascites; the assumption is that the fluid in the abdomen is due to some malignant growth in the liver, or elsewhere in the peritoneum.

(ii.) If the fluid is not too abundant, or if it has been lessened by tapping, we may be able to make out some nodules or even considerable growths situated in some portion of the peritoneal cavity. The diagnosis is *carcinoma of the peritoneum*.

(iii.) In addition to free fluid it is possible to recognise the presence of a tumour in the pelvis. It may be single or bilateral; the size of a fist, or so large as to cause a tumour the size of the pregnant uterus at term. If the tumour can be palpated abdominally, its surface will probably be found to be irregular and nodular. The diagnosis is *ovarian carcinoma or papilloma with hydro-peritoneum*.

(iv.) A tumour is present in the abdomen, presenting the physical signs of a multilocular ovarian cyst; portions of the tumour feel solid. There is no evidence of the presence of free fluid in the abdomen. The tumour has not the mobility usually found with ovarian cysts; the uterus may appear rather intimately connected with it. In a case of this kind, where the patient has lost flesh, and perhaps has had pain, and where the symptoms and signs are not classical, the most probable diagnosis is *malignant ovarian tumour*.

(g) The patient gives a history of gradual increase in the size of the abdomen, without any pain until quite recently. Pain came on rather suddenly and very acutely a few days ago, and has continued since. If the onset of pain dates back a week or two, the patient may present some rise of temperature, the pain becoming rather generalized in the abdomen instead of being localized to one spot. On examination, a rounded, tense, cystic swelling is discovered, distinct from the uterus; it is tender to manipulation, and if the case is associated with pain of longer duration and rise of temperature, there will be general abdominal tenderness. The diagnosis is *ovarian cyst with a twisted pedicle*. The presence of general tenderness and rise of temperature will indicate that the tumour is complicated by localized or general peritonitis, with adhesions.

We may note here that a *large appendix abscess* may present points of resemblance to an ovarian cyst with twisted pedicle; in both we may have a smooth, rounded tumour, with pain, and a moderate rise of temperature. The appendix abscess will be situated towards the right of the middle line; an ovarian tumour may take up a similar position, even if it originates on the left side, and it may become fixed to the right by adhesions. Vomiting may be present in both conditions. The leading distinguishing feature between the two conditions will be the mode of onset, for an appendix abscess has a short history, and the swelling will have developed rapidly with pain from the first, whilst the ovarian tumour has probably been in existence for a considerable time, and the swelling has been noticed before there has been any pain. But even this difference is not pathognomonic, because an ovarian cyst may have been unnoticed until the twisting of the pedicle has called attention to it; and this accident is apt to produce a marked increase in the size of the tumour due to passive venous engorgement or hæmorrhage into its cavities.

**2. Menstruation is Absent.** Three natural subdivisions of this group present themselves, according as the amenorrhœa is primary, secondary, or climacteric.

A. *The Patient has never menstruated.* Several types are met with in which abdominal swelling is associated with primary amenorrhœa.

(a) The first type is exactly the same as we have fully considered under 1 (a), where the diagnosis rests between *ovarian cyst*, a *large hydronephrosis*, and *tuberculous peritonitis with a circumscribed effusion*; and it is not necessary to repeat the sketch of the case.

(b) The patient, who is a child or a young girl, has had gradually increasing distension of the abdomen, and this

has lately been associated with wasting. Precise inquiry may elicit the fact that the swelling first showed itself in the lumbar region, and became more general at a later stage. On examination, a large, firm tumour can be felt; if large, it may appear to fill up the abdomen; if smaller, it will be found to be situated chiefly on one side. In either case it extends well backwards into the loin on one side. Careful percussion shows that the tumour is dull on deep percussion, whilst light percussion elicits a resonant note over a part or the whole of it. Examined by the vagina or rectum, the tumour does not appear to descend into the pelvis; and it may be possible to feel the ovaries independent of it. The diagnosis is *sarcoma of the kidney*.

A condition that may simulate this is a *solid ovarian tumour*. The chief points of distinction are that in the latter case there is probably little or no wasting; the tumour is dull all over, even on light percussion, and it appears to descend into the pelvis.

(c) The patient, besides having an abdominal swelling complains of pain, referred especially to the hypogastrium. We may be able to elicit the fact that the pain was at first intermittent, coming on at intervals of three or four weeks; and that, judging from the character of the pain, the mother thought that the child was going to commence menstruating. Lately the duration of the pain has steadily increased, and now it is almost continuous.

On examination, the breasts are childish, and show no appearances characteristic of pregnancy. The lower part of the abdomen is the seat of a smooth, rounded tumour, which feels rather like a pregnant uterus. On examination of the vulva, it is found that the vagina is completely occluded, either at the vulva, or a little higher up. If at the vulva, a bulging membrane replaces the vaginal orifice.

The diagnosis is *retained menstrual products* (*cryptomenorrhœa*), and it is established beyond doubt when, on incising the membrane, a dark, treacly fluid is liberated.

(d) The swelling of the abdomen has been noticed for several months; the young girl has appeared to be fretful and ill at ease, and she may have been sick at times, especially in the mornings. There may be a history of criminal assault. On examination, the breasts are enlarged, and contain a secretion. The abdomen is distended by a smooth, rounded tumour, whose consistence varies intermittently. It may be possible to feel foetal parts or movements, and to hear the foetal heart. On examination of the vagina, the hymen is deficient, the cervix is soft, the vagina and vulva may present a dusky or violet discoloration, and, bimanually, the swelling is found to be uterine. The diagnosis is *pregnancy*.

Conception before the establishment of menstruation is, of course, a rare occurrence; but it has been known to take place in the case of young, unmarried girls, and also in some cases when a young girl has got married before puberty.

B. *The Patient has ceased menstruating for Several Months.* With secondary amenorrhœa, associated with abdominal swelling, pregnancy is, of course, the first thing to think of.

(a) The first type is that in which the patient presents the symptoms and physical signs of normal pregnancy. Here there is no difficulty, and we may confidently say that the diagnosis is *pregnancy*.

(b) In the second type the symptoms are those of pregnancy, including complete amenorrhœa of several months' duration; but the patient states that the abdomen is much larger than it should be. On examination—

(i.) The abdomen is very large; it is occupied by a

smooth, rather tense tumour. Fœtal parts can be made out; and appear to correspond to only one fœtus. Only one foetal heart can be heard. The diagnosis is *hydramnios*.

(ii.) The abdomen is larger than the term of amenorrhœa justifies; the fœtal parts can be made out, and appear to present an unusual number of limbs. Instead of two smooth, rounded portions, corresponding to a head and a breech, three, or perhaps four, such can be felt. The fœtal heart can be heard in two places, and the pulse-rate is different in these places. The diagnosis is *twin pregnancy*.

(iii.) The abdomen is unusually large; careful palpation shows that the tumour is not uniform and homogeneous, but appears to consist of two portions. The one has the consistence of the pregnant uterus, and in it fœtal parts and movements can be felt. The other portion appears to be distinct; it is smooth, rounded, or flattened, and feels cystic. It may be lower in the pelvis than the first tumour, or higher up in the abdomen, or the two parts may be side by side. The diagnosis is *ovarian cyst complicating pregnancy*.

(iv.) The abdomen is larger than normal; a swelling is felt, which appears to be the pregnant uterus. By the side, or above, or lower in the pelvis, a very hard tumour is felt; it may feel either entirely distinct or partially so, occupying some portion of the uterine tumour. Sometimes several hard masses may be felt, and in the earlier stages of pregnancy they may appear to represent a greater total volume than the portion which is regarded as the seat of pregnancy. The diagnosis is *uterine myoma complicating pregnancy*.

I may observe, in passing, that when an intramural myoma complicates pregnancy, the diagnosis may be very

difficult ; but if, on repeated examination, a part of the uterus feels distinct and hard, taking no apparent share in the rhythmic contraction and relaxation characteristic of the pregnant uterus, we should be justified in diagnosing a myoma, complicating the pregnancy.

(c) In a third type the patient presents the symptoms of pregnancy. She may state that when she was from two to three months pregnant she was taken rather ill one day with faintness and pain in the side, and that she noticed a 'show,' which went on slightly for several days and then ceased. On examination, the breasts contain secretion. The abdomen has not the smooth, rounded, prominent contour characteristic of pregnancy. The parts of the fœtus may be felt with rather startling distinctness, as if the fœtus lay close under the abdominal wall, and as if the liquor amnii were in small quantity. On percussion, we may find that, in place of the usual dulness over the front of the abdomen, there is a resonant note almost down to the pubes. On vaginal examination, the cervix is smaller and harder than usual, and it may be lying high up behind the pubes. Careful bimanual examination, if necessary under an anæsthetic, shows that the cervix is continuous with a small mass, which is evidently a normal, unimpregnated uterus ; if the sound be passed into this, it enters only the normal distance. The diagnosis is *extra-uterine pregnancy advancing to full time*.

(d) There is an uncommon type, in which a woman notices a swelling of the abdomen, and complains of stoppage of menstruation. Or she may say that she has not had a normal period for several months, and that there has been only a little show each month instead. Careful questioning may elicit the fact that the swelling of the abdomen really preceded the term of cessation or diminution of menstruation, and that men-



struation has been scanty for a long time. The patient may show indications of lung trouble, and give a history of loss of flesh, night-sweats, and rise of temperature in the evenings. On examination, the breast signs are negative; the skin of the abdomen feels dry and harsh. A smooth, rounded tumour is felt in the abdomen; it readily transmits a thrill when lightly tapped. On vaginal examination, the uterus is found to be normal, and not enlarged; there are no physical signs of pregnancy. The diagnosis rests between an ovarian cyst and tuberculous peritonitis. The physical signs are much the same in both cases; but the gradual diminution and cessation of menstruation, combined with the history and symptoms already mentioned, must lead us to the diagnosis of *tuberculous peritonitis with encysted effusion*.

C. *Menstruation has ceased, owing to the Menopause.* A patient, after the menopause, is liable to the same causes of abdominal swelling as we have discussed under unaltered menstruation. At this age distension, due to fat and flatulence, is common, and pseudo-cyesis may be met with. All that is necessary to add to what has been said already is that when menstruation has ceased only a few months, great care is sometimes necessary to enable us to decide whether the patient is really pregnant or not. Thus, a patient of forty-nine or fifty may come with a history of several months' amenorrhœa and swelling of the abdomen; perhaps she believes herself to be pregnant. She may be very fat, and it may be a difficult matter to decide whether or not the uterus is enlarged. I have a vivid remembrance of a patient of this type, aged forty-nine. I was quite unable to determine the presence of a pregnant uterus, even after several examinations, but she was delivered of a full-term child three months after I last saw her.

3. **Menstruation is increased in Quantity.** It will be convenient to consider under this heading both the cases with menorrhagia and those with metrorrhagia, for it not infrequently happens that metrorrhagia comes on after menorrhagia has been going on for some time.

(a) In one clinical type abdominal swelling and losses of blood (either at or between the periods) may be the only symptoms: there may be a little pain at times, or there may be pressure symptoms; but, on the other hand, there may be a conspicuous absence of both pain and discomfort. We find that this one clinical type may present widely different conditions on examination.

(i.) The swelling in the abdomen extends up to the umbilicus or higher. The tumour is very hard, and is perhaps nodular or multiple. On examination, the uterus is involved in, and in fact forms, the tumour; the sound passes in a distance of 4 inches or more. The diagnosis is *uterine myoma* or *multiple myomata*.

(ii.) The uterus is the seat of a large hard tumour, as above. A separate swelling is felt by the side of the uterus; this may be rather soft or cystic, and its nature will be a matter of surmise, because an ovarian cyst and a fibrocystic myoma would feel much the same on examination. On the other hand, the separate swelling may be quite hard, and may prove to be either an outlying subserous or pedunculated myoma or a solid ovarian tumour. The diagnosis in such case will be *uterine myoma with an ovarian tumour* or *with a pedunculated myoma*.

(iii.) The uterus feels the normal size; a large tumour is felt by the side of it; or there may be two or more tumours. Here, again, the diagnosis offers several possibilities. The uterus may be normal, and the tumour is a malignant ovarian growth. We may note that a simple ovarian cyst or tumour does not give rise to hæmorrhage

when the uterus is normal. Or the tumour may be a pedunculated myoma, and the hæmorrhage is due to a small intra-uterine polypus. Or the tumour may be a simple ovarian cyst, while the uterus is the seat of the curious change known as fibrosis, and the hæmorrhage is explained in this way. The diagnosis, therefore, is an open one, the possibilities being *ovarian carcinoma, pedunculated myoma* or *ovarian cyst* or *cysts with uterine fibrosis*.

(b) In another type, besides swelling of the abdomen and hæmorrhage, the patient complains of abdominal pain, and there may be some rise of temperature in the evenings, or even periodical rigors. With such a history we shall expect to find inflammatory changes complicating a tumour; the exact nature of the complication cannot be foretold with accuracy before operation, and indeed even when the abdomen is opened it may be very difficult at first to make out the precise state of things. The diagnosis lies between the following conditions: *Uterine myomata with inflammatory or septic changes; myomata with localized peritonitis; myoma complicated by an ovarian tumour with twisted pedicle; myoma with suppurating ovarian cyst; myoma with pyosalpinx and peritonitis; myoma with appendicitis; ovarian carcinoma and peritonitis; suppurating ovarian cyst and uterine fibrosis.*

In these complex conditions I believe that an exact diagnosis is not possible; in the absence of the classical symptoms and signs of any particular condition, the only safe plan is to be prepared for any complication.

## Gynaecological Diagnosis

## SYNOPSIS OF CASES OF ABDOMINAL SWELLING.

Leading Symptom.	Associated Symptoms.	Physical Signs.	Diagnosis.
ABDOMINAL SWELLING I. Menstruation normal	(a) None	Defined tumour, dull over the front of the abdomen; fluid thrill; uterus normal	Ovarian tumour; large hydro-nephrosis; encysted tuberculous hydroperitoneum
	(b) None; patient is single or a married nullipara	Defined solid tumour, separate from the uterus	Solid ovarian tumour; pedunculated myoma; fibroma of the round ligament; enlarged wandering spleen; solid omental tumour
	(c) Weight and dragging in the right hypochondrium (jaundice)	Solid tumour extending downwards from the right hypochondrium	Hepatic enlargement
	(d) Movements in the abdomen; gradual enlargement; hope of pregnancy	General enlargement of abdomen; respiratory movement down to the pubes; obesity; tympanites, breast signs negative; abdomen softens under anaesthesia	Flatulence and obesity; pseudocystitis or phantom tumour
	(e) Cardiac, renal or hepatic disease; oedema of face or extremities	Abdomen flattens in supine position; dullness in flanks and hypogastrum, with concave margin. Respiratory movement down to pubes	Ascites
	(f) Loss of flesh; cachexia	(i.) Physical signs of ascites (ii.) Ascites; nodules of growth	Carcinoma involving the peritoneum
	(g) Recent pain; rise of temperature	(iii.) Free fluid in the abdomen; a tumour on one or both sides of the uterus (iv.) Physical signs of multilocular ovarian tumour Rounded, tense, cystic swelling; abdominal tenderness	Carcinoma of the peritoneum (probably secondary) Ovarian papilloma or carcinoma with hydroperitoneum Malignant ovarian tumour Ovarian cyst, with twisted pedicle; (large appendix abscess)

<p>2. Menstruation absent</p>	<p>(a) None</p> <p>(b) Patient is young; wasting; swelling first appeared in loin</p> <p>(c) Pain in hypogastrum, at first intermittent</p> <p>(d) Morning sickness (history of rape.)</p>	<p>Physical signs of ovarian cyst</p> <p>Large firm tumour, connected especially with the lumbar region; dulness on deep percussion, and resonance on light percussion</p> <p>Breasts negative; doughy or firm swelling in hypogastrum; atresia of the vagina</p> <p>Breasts contain secretion; hymen deficient; physical signs of pregnancy</p> <p>Physical signs of pregnancy</p> <p>(i.) Unusual enlargement, with tense, fluid tumour, which is uterine</p> <p>(ii.) Parts of two foetuses felt; two fetal hearts heard</p> <p>(iii.) Abdomen contains two tumours, one with signs of pregnancy, the other cystic</p> <p>(iv.) A hard, solid tumour is felt in addition to the pregnant uterus</p> <p>Foetal parts felt too distinctly; front of the abdomen resonant; uterus felt separate, small, empty</p> <p>Skin of abdomen is dry and harsh; smooth rounded tumour in the abdomen; uterus normal</p>	<p>Ovarian cyst; tuberculous peritonitis; large hydronephrosis</p> <p>Sarcoma of the kidney; (solid ovarian tumour)</p> <p>Retained menstrual products, or cryptomenorrhœa</p> <p>Pregnancy</p> <p>Pregnancy</p> <p>Hydramnios</p> <p>Twin pregnancy</p> <p>Ovarian cyst complicating pregnancy</p> <p>Myoma complicating pregnancy</p> <p>Extra-uterine pregnancy advancing to term</p> <p>Tuberculous encysted hydroperitoneum, with tuberculous salpingitis</p>
<p>A. Primary Amenorrhœa</p>	<p>(a) Symptoms of pregnancy</p> <p>(b) Symptoms of pregnancy; abdomen unusually large</p>	<p>Physical signs of pregnancy</p>	<p>Pregnancy</p>
<p>B. Secondary Amenorrhœa</p>	<p>(c) Symptoms of pregnancy, with those of extra-uterine pregnancy</p> <p>(d) Partial or complete amenorrhœa, which followed the abdominal swelling; history of lung trouble; rise of temperature and night-sweats</p>	<p>Physical signs of pregnancy</p>	<p>Extra-uterine pregnancy advancing to term</p>

SYNOPSIS OF CASES OF ABDOMINAL SWELLING—*continued.*

Leading Symptom.	Associated Symptoms.	Physical Signs.	Diagnosis.
C. Climacteric Amenorrhœa	—	—	The same group of conditions as may occur with unaltered menstruation
3. Menorrhagia or Metrorrhagia	(a) None, or slight pain or pressure symptoms	(i.) Hard tumour involving the uterus; cavity of uterus lengthened (ii.) Hard uterine tumour; separate tumour, which may be hard or cystic (iii.) Uterus normal size; hard tumour or cystic tumour by the side of the uterus	Uterine myoma or multiple myomata Uterine myoma and pedunculated myoma; uterine myoma with ovarian tumour Ovarian carcinoma; pedunculated myoma; ovarian cyst, with uterine fibrosis
	(b) Abdominal pain; rise of temperature in the evenings; (rigors)	Abdominal tumour; abdominal tenderness; possibly one or more swellings in addition to the principal tumour	Uterine myoma with septic changes; myoma with localized peritonitis; myoma and ovarian tumour with twisted pedicle; myoma with suppurating ovarian cyst; myoma with pyosalpinx; ovarian carcinoma and peritonitis; suppurating ovarian cyst and uterine fibrosis; myoma with appendicitis

## CHAPTER XX

### CONCLUSION

I HAVE now completed my survey of gynæcological conditions as they may be traced out from the starting-point of symptoms. The survey has taken the form of a series of sketches broadly outlined; finished pictures would have involved a much larger work, and would have been out of touch with my purpose, because I desired to bring out in strong relief those salient features that help the most in arriving at a diagnosis; and this could not have been done in finished pictures without spoiling their harmony and proportion.

Some of the cases most difficult to deal with are those that may be summed up as presenting 'a plethora of symptoms and a paucity of signs'; everything must be excluded; and the difficulty largely resembles that involved in proving a negative.

There is a quite opposite class of case in which no symptoms are present at all; and yet there is a definite pathological condition present. Starting from symptoms, as we have done, such cases have necessarily not been touched upon hitherto; and so it is necessary to make a brief mention of them before bringing these observations to a close.

In the course of making an abdominal examination on

account of symptoms in no way gynaecological, we may discover that there is a tumour rising up into the lower part of the abdomen from the pelvis; this may be a sub-peritoneal myoma that is not large enough to cause pressure symptoms or to affect the patient's figure; there is no menorrhagia nor metrorrhagia because there is no intra-uterine growth. Or the tumour may be a small ovarian cyst or dermoid, or a myoma of the round ligament.

So also in the course of a vaginal examination we may find that there is a deep laceration of the cervix, or a marked ante flexion or retroversion of the uterus; or there may be a small ovarian cyst, or a small subperitoneal myoma; or the vagina may be the seat of one or more small cysts, derived from unobliterated remnants of the Gartnerian duct; or there may be some malformation, such as a double uterus, and perhaps even a double vagina. It is a well-known fact that a woman may be the mother of several children and yet have an unsuspected double uterus; even a double vagina in a married woman may be discovered only by accident, whilst it is natural that in a single woman it should pass unobserved.

In other cases the patient may present certain symptoms having reference to the pelvic organs; and on making an examination some condition is discovered which has no relation at all to the symptoms. For example, a patient who had been married for two years came to know if there was any reason why she should not have children, and an ovarian dermoid was discovered. Another complained of 'something falling in the passage,' and was found to have a uterus didelphys.

Speaking generally, a woman who has no symptoms is not likely to be found suffering from any inflammatory condition; the conditions most likely to be present with-



out symptoms are small tumours and cysts, certain malformations, and certain displacements.

Numerically, this class of case is not important; but it is of the greatest importance as an illustration of the teaching that a diagnosis must not be made on symptoms, and that it is not permissible to express an opinion as to the condition of the pelvic organs except after a careful bimanual examination.

The most expert and the most experienced must make mistakes in diagnosis; there is only one unpardonable sin, and that is to make a mistake as the result of careless or inadequate examination, or from having failed to make any examination at all.

## INDEX

- ABDOMINAL EXAMINATION**, 18,  
     56  
     movement during respiration,  
     57  
     swellings, 57, 187  
**Abortion**, habit of, 14, 158  
     impending, 129  
     incomplete, 123, 129  
     missed, 129  
     repeated, 14, 158  
     threatened, 109, 129  
**Age**, significance in diagnosis, 11  
**Amenorrhœa**, 40, 92  
     climacteric, 41, 96, 97  
     constitutional, 92, 95  
     primary, 40, 92  
     secondary, 40, 94  
**Anæmia**, significance of, 17  
**Anamnesis**, 6  
**Appendix abscess**, 61, 195  
**Ascites**, 57, 192  
**Atresia of the os externum**, 97  
     of the vagina, 94, 103, 195  
  
**Backache**, 43, 104, 109  
**Barnes's speculum**, 32  
**Bartholinian abscess**, 112, 148,  
     181  
     cyst, 112, 148, 181  
**Bearing-down pain**, 162  
**Bimanual examination**, 25, 70  
     palpation of the uterus, 28  
**Bivalve speculum**, 33  
**Bladder disturbance**, 48, 171  
**Bowel disturbance**, 48, 168  
  
**Canal of Nuck**, hydrocele of, 64,  
     180  
**Carcinoma of the cervix**, 87, 107,  
     126, 127, 138, 171  
     of the clitoris, 63, 186  
     of the ovary, 193, 201  
     of the peritoneum, 192  
     of the uterus, 126  
     of the vagina, 67, 127, 171,  
     186  
     of the vulva, 63, 180, 186  
**Caruncle**, urethral, 63, 127, 149,  
     171  
**Case-sheet**, example of, 7  
**Case-taking**, 6  
**Cervix**, adenoma of, 84, 85, 127,  
     136, 139  
     carcinoma of, 87, 107, 126,  
     127, 138, 171  
     conical, 67, 83  
     double, 87  
     erosion of. See Adenoma of  
     examination of, 67  
     hyperplasia of, 67, 163, 182  
     laceration of, 83, 159  
     myoma of, 125  
     normal, 82  
     polypus of, 86  
**Chorio-epithelioma**, 125  
**Civil state**, significance in diag-  
     nosis, 12  
**Climacteric**, 96  
     hæmorrhage, 46  
**Clitoris**, carcinoma of, 63  
     elephantiasis of, 180  
     elongation of, 62  
**Condylomata of the vulva**, 136,  
     181  
**Confinements**, significance in  
     diagnosis, 14  
**Congenital retroflexion of the  
     uterus**, 119  
**Congestion of the pelvis**, 135  
     of the uterus, 101, 105, 119  
     of the vulva, 143  
**Constipation as a symptom**, 169  
**Cryptomenorrhœa**, 40, 93, 94, 103,  
     196  
**Cusco's speculum**, 33

- Cyst of the ovary, 58, 108, 149, 188, 189, 194, 201  
of the vagina, 65, 182
- Cystitis, 143
- Cystocele, 65, 164, 172, 174, 182
- Deciduoma malignum, 125
- Defective ovulation, 95, 153
- Delayed puberty, 93
- Digital examination, 23
- Discharge, 47, 135  
blood-stained, 47, 138  
brownish, 46, 48, 124, 129, 139  
foetid, 47, 138  
gonorrhœal, 47, 136  
mucous, 47  
purulent, 47, 136  
urinous, 139  
watery, 47, 138  
white, 47, 135  
yellow, 136
- Dorsal position, 21
- Double cervix, 87  
uterus, 72, 74, 75, 76, 205  
vagina, 147, 154
- Dysmenorrhœa, 42, 100
- Dyspareunia, 49, 146  
primary, 146  
secondary, 148
- Elephantiasis of the vulva, 180
- Endometritis, 102, 105, 119, 136, 143, 159
- Examination, abdominal, 18, 56  
bimanual, 25, 70  
general, 16  
method of, 16  
position for, 19  
speculum, 80  
vaginal, 19, 64  
vulvar, 62
- Extra uterine pregnancy, 47, 107, 108, 129, 130, 173  
differential diagnosis, 124  
going on to term, 198  
mesometric, 130  
ruptured, 129, 130
- Fallopian tube, palpation of, 30
- Family history, significance in diagnosis, 12
- Ferguson's speculum, 31
- Fibroid polypus, 86, 121, 125, 126
- Fibroma of the ovary, 79  
of the vulva, 180
- Fibromyoma of the uterus. See Myoma
- Fibromyxoma of the vulva, 63, 180
- Fibrosis of the uterus, 121, 201
- Fistula, recto-vaginal, 65, 80, 139, 170  
urethro-vaginal, 80, 139  
vesico-vaginal, 65, 80, 139, 174
- Flatulence, 57, 104, 191
- Flatus, passage of, through bladder, 175
- Foreign bodies in the vagina, 69, 166
- Frequent micturition, 48, 172
- Functional congestion of puberty, 119
- Genu-pectoral position, 19
- Gonorrhœa, 45, 111, 136, 148, 171
- Gonorrhœal condylomata, 136, 181  
salpingitis, 102, 109, 113, 120, 137, 149, 155, 156, 169  
vaginitis, 148
- Gynæcological notes, 7  
position, 21
- Habit of abortion, 14, 158
- Hæmatocolpos, 94
- Hæmatometra, primary, 71, 94  
secondary, 41, 97, 98
- Hæmatosalpinx, 94
- Hæmorrhage, 44, 118  
accidental, 131  
associated with menstruation, 44, 118  
at the menopause, 46  
during pregnancy, 46, 127  
independent of menstruation, 45, 121
- Hepatic enlargement, 191
- Hernia, inguinal, 183
- Hour-glass contraction of the vagina, 24
- Hydatidiform mole, 130
- Hydramnios, 197
- Hydrocele of the canal of Nuck, 64, 180
- Hydronephrosis, 58, 188, 194

- Hydroperitoneum, 58, 189, 193, 194
- Hydrosalpinx, 109, 155  
intermittent, 103
- Hymen, excessive tear of, 122  
imperforate. See Atresia of the vagina  
rigidity of, 147, 153
- Hyperplasia of the supravaginal cervix, 67, 163, 182  
of the vaginal portion of the cervix, 67, 163, 182
- Impacted fundus of the uterus, 106  
myoma, 102, 105, 170  
ovarian tumour, 170
- Incontinence of fæces, 170  
of urine, 174
- Inguinal hernia, 183
- Injury causing hæmorrhage, 121  
of the vagina, 122  
of the vulva, 122, 148
- Instruments for diagnosis, 31
- Intermenstrual pain, 42, 102
- Intermittent hydrosalpinx, 103
- Inversion of the uterus, acute, 110  
of the uterus, chronic, 165, 166, 182
- Knee-elbow position, 19
- Kraurosis vulvæ, 49, 64, 144
- Lateral position, 20
- Leucorrhœa, 47, 135
- Lithotomy position, 19
- Malformation of the uterus, 72, 206  
of the vagina, 64, 147, 154  
of the vulva, 62, 147, 154
- Menopause, 96  
premature, 97, 98
- Menorrhagia, 44, 118
- Menstruation during pregnancy, 46, 128  
significance in diagnosis, 13
- Metrorrhagia, 45, 121
- Miscarriages, significance in diagnosis, 14
- Mittelschmerz, 102
- Mucous polypus, 86, 119
- Myoma of the cervix, 125  
of the mesometrium, 79
- Myoma of the round ligament, 79, 190, 206  
of the uterus, 106, 120, 126, 155, 165, 200  
of the uterus complicating pregnancy, 197  
of the uterus, impacted, 102, 106, 170  
of the uterus, pedunculated, 106, 182, 189, 200  
of the uterus, polypoid, 86, 121, 125  
of the uterus, sloughing, 138  
of the uterus with inversion, 166
- Neugebauer's speculum, 33
- Obesity, significance of, 18
- Omental tumours, 190
- Oöphoritis, 108
- Ovarian carcinoma, 193, 201  
cyst, 58, 108, 149, 188, 189, 194, 201  
cyst complicating pregnancy, 197  
cyst, ruptured, 110  
cyst, suppurating, 113, 201  
cyst with twisted pedicle, 111, 193  
papilloma, 193  
tumour, 106, 188, 189  
tumour impacted, 170
- Ovary, palpation of, 30  
prolapse of, 102, 108, 149, 168
- Pain, 41, 100
- Painful defæcation, 48, 168  
intercourse, 49, 145  
menstruation, 42, 100  
micturition, 48, 171
- Pelvic abscess, 112, 113, 169, 170  
cellulitis, 156, 169  
peritonitis, 112, 113, 156  
swellings, 77, 78  
tumours, 79
- Perineum, rupture of, 170
- Phantom tumour, 57, 191
- Placenta prævia, 131
- Polypus, fibroid, 86, 121, 125  
mucous, 86, 119  
placental, 124
- Position, dorsal, 21  
for examination, 19

- Position, genupectoral, 19  
 gynæcological, 21  
 lateral, 20  
 lithotomy, 19  
 semiprone or Sims's, 20
- Pregnancy, 41, 96, 128, 196, 197  
 extra uterine. See Extra-uterine pregnancy  
 hæmorrhage during, 46, 127  
 menstruation during, 46, 128  
 with carcinoma of the cervix, 131  
 with cervical polypus, 128  
 with ovarian cyst, 197  
 with uterine myoma, 197
- Premature menopause, 97, 98
- Previous health, significance in diagnosis, 13
- Primary amenorrhœa, 40, 92  
 dyspareunia, 146  
 sterility, 50, 153
- Procidencia totalis, 165, 172, 182
- Prolapse of the ovaries, 102, 108, 149, 168  
 of the uterus, 67, 105, 155, 163, 164, 172, 182  
 of the vagina, 164, 182
- Pruritus, 49, 142
- Pseudo-cyosis, 57, 191, 199
- Pseudo-hermaphroditism, 62, 147
- Pyometra, 138
- Pyosalpinx, 102, 109, 120, 137, 155
- Rectocele, 164, 182
- Recto-vaginal fistula, 80, 170
- Respiratory movement of abdomen, 57
- Retained pessary, 47, 137, 139  
 placenta, 124  
 products of conception, 120, 123  
 of menstruation, 93, 94, 196
- Retention of urine, 49, 172  
 during menstruation, 49, 174
- Retroversion of the gravid uterus, 106, 173  
 of the uterus, 72, 105, 136, 149, 154, 168, 169, 172  
 of the uterus, acute, 109  
 of the uterus, congenital, 119
- Round ligament, myoma of, 190, 206
- Round ligament, palpation of, 30
- Ruptured extra-uterine pregnancy, 111  
 ovarian cyst, 110  
 perineum, 170
- Salpingitis, 102, 109, 113, 120, 137, 149, 155, 156, 109
- Sarcoma of the kidney, 195  
 of the uterus, 126  
 of the vagina, 127
- Scanty menstruation, 40
- Secondary amenorrhœa, 40, 94  
 dyspareunia, 148  
 hæmatometra, 41, 97, 98  
 sterility, 51, 155
- Semiprone position, 20
- Signs, interpretation of, 56
- Sims's position, 20  
 speculum, 32
- Sound, uterine, 33  
 method of passing, 34
- Speculum, Barnes's, 32  
 crescent, 32  
 Cusco's, 33  
 examination, 80  
 Ferguson's, 31  
 Neugebauer's 33  
 pictures of the cervix, 82-87  
 Sims's, 32
- Spleen, wandering, 61, 190
- Stenosis of the cervical canal, 101, 154  
 of the vagina, 147, 154
- Sterility, 50, 152
- Subinvolution, 120
- Superinvolution, 98
- Swabs and swab-holders, 37
- Swelling of the abdomen, 57, 187
- Swellings, abdominal, 57, 61, 187  
 pelvic, 61, 62, 77, 78  
 vulvar, 63, 179
- Symptoms, gynæcological, 39  
 significance of, 38
- Syphilis, 158
- Temperature, significance of, 18
- Traumata of vagina, 65  
 of vulva, 63
- Tubal pregnancy. See Extra-uterine pregnancy
- Tuberculous peritonitis, 189, 194, 197

- Tubo-ovarian abscess, 109, 155  
     cyst, 109, 155  
 Twisted pedicle of ovarian cyst,  
     111, 193
- Ureter, palpation of, 30  
 Urethral caruncle, 63, 127, 149,  
     171  
 Uterine sound, 33  
 Uterus bicornis, 72, 75, 76  
     carcinoma of, 126  
     congestion of, 101, 105, 119  
     didelphys, 72, 76  
     displacements of, 72, 101  
     fibromyoma of. See Myoma  
     of  
     fibrosis of, 121  
     gravid, retroversion of, 106  
     infantile, 72, 73, 153  
     inflammation of, 101  
     inversion of, acute, 110  
     inversion of, chronic, 165, 166,  
     182  
     malformations of, 72  
     myoma of, 106, 120, 121, 126,  
     155, 165, 189, 200, 201  
     myoma of, impacted, 102, 106,  
     170, 174  
     position of, 72  
     prolapse of, 67, 105, 155, 163,  
     172, 182  
     retroversion of, 72, 105, 109,  
     119, 136, 149, 154, 163, 168,  
     172  
     rudimentary, 72, 73, 153  
     sarcoma of, 126  
     septus, 72, 74, 75  
     subinvolution of, 120  
     superinvolution of, 98  
     unicornis, 72, 74
- Vagina, abnormal contents in,  
     69  
     abscess discharging through,  
     137  
     atresia of, 147, 154, 195
- Vagina, carcinoma of, 127  
     cysts of, 65, 182  
     displacements of, 65, 164  
     double, 147, 154  
     examination of, 19, 23, 64  
     foreign body in, 69, 166  
     injuries of, 65, 122, 137  
     malformations of, 64, 147, 154  
     prolapse of, 164  
     sarcoma of, 127  
     stenosis of, 147, 154  
     surroundings of, 69  
     ulceration of, 139
- Vaginal examination, 19, 23, 64  
     fistulæ, 65, 80, 139, 170
- Vaginismus, 154  
 Vaginitis, 148
- Vesicovaginal fistula, 65, 80, 139,  
     174
- Vulva, carcinoma of, 180, 186  
     chancroids of, 63, 180  
     condylomata of, 63, 180  
     cutaneous diseases of, 64  
     elephantiasis of, 180  
     fibroma of, 64, 180  
     fibromyxoma of, 63, 64, 180  
     gonorrhœa of, 63  
     hæmatoma of, 64, 186  
     inflammation of, 63  
     injuries of, 63, 122, 148  
     inspection of, 62  
     kraurosis of, 49, 64, 144  
     lipoma of, 64, 179  
     malformation of, 62  
     œdema of, 64, 180  
     papilloma of, 64, 180  
     pruritus of, 49, 142  
     swellings of, 63, 179  
     varix of, 64, 183  
     varix of, ruptured, 122, 183
- Vulvitis pruriginosa, 143
- Wandering spleen, 61  
 Wasting, significance of, 18
- Xanthorrhœa, 47, 136

THE END