

## TECHNICAL MEMORANDA.

---

### Anterior Colporrhaphy and its Combination with Amputation of the Cervix as a Single Operation.

By W. E. FOTHERGILL, Manchester.

A PRELIMINARY note on the modifications now figured appeared in the *British Medical Journal*, April, 1913, and a later development was mentioned in this Journal in July, 1914. The plates, now reproduced by the courtesy of the *American Journal of Surgery*, explain the technique much better than the rough diagrams previously used. I have therefore thought it worth while to publish them in this Journal together with a brief explanatory text.

Fig. I. illustrates a modification of ordinary anterior colporrhaphy which is useful in cases of true prolapse when the uterus is not elongated and when the cervix is healthy and not hypertrophied. The dotted line shows the usual incision. The plain line shows the incision extended upwards and backwards on both sides of the cervix so that the wound becomes a triangle with its apex at the urethral orifice and its broad base crossing the vaginal roof just in front of the cervix. The closure of this wound from side to side brings together in the middle line in front of the cervix the tissues which formerly lay at its sides. The cervix is thus pushed upwards and backwards towards the hollow of the sacrum. The body of the uterus at the same time passes forward into a position of anteversion and is kept there by intra-abdominal pressure. The recurrence of prolapse is thus effectively prevented. The operation is completed by a moderate repair of the perineum done so as to restore the natural size, slope and curve of the vagina. This modification was first described by the writer in the Transactions of the Edinburgh Obstetric Society, 1907-8.

Figs. II. to VI. illustrate the combination of anterior colporrhaphy with amputation of the cervix as a single operation. This device is useful in cases of true prolapse whenever the uterus is more than three inches long and whenever the cervix is lacerated and unhealthy. It is also useful in cases of elongation of the cervix with inversion of the vagina from above downwards. In short, whenever it is necessary to amputate the cervix when operating on any variety of genital prolapse, it is best to remove the cervix together with part of the anterior vaginal wall. For ordinary amputation of the cervix is a bad preliminary to an anterior

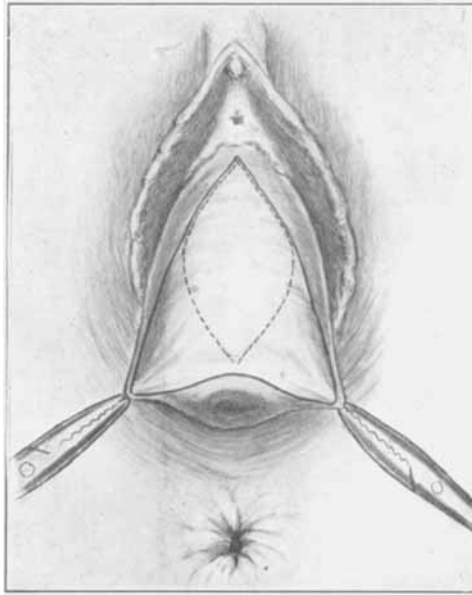


Fig. 1. Colporrhaphy without amputation of the cervix.

The dotted line shows the usual incision. The plain line shows the author's incision, extending upwards and backwards on either side of the cervix.

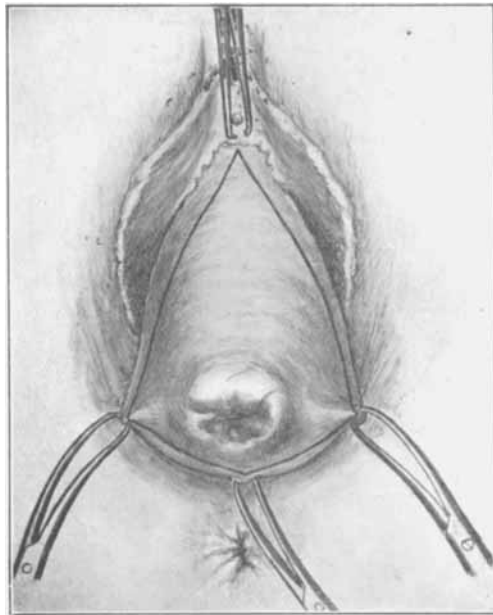


Fig. 2. Colporrhaphy combined with amputation of the cervix.

The line of incision.

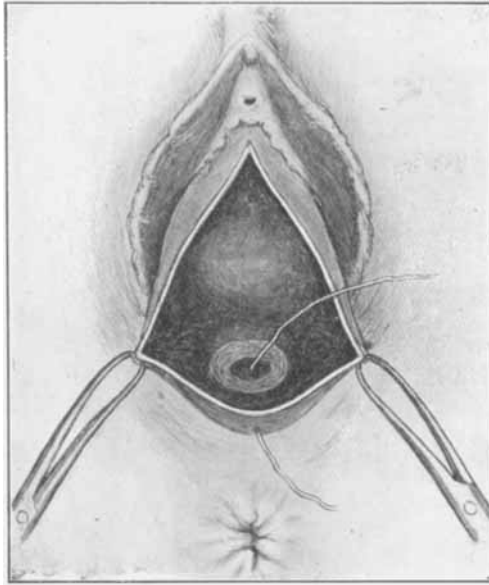


Fig. 3. Colporrhaphy combined with amputation of the cervix.

The triangle of vaginal wall has been removed with the cervix in one piece. The suture has been inserted from the cervical canal through uterine wall and vaginal wall.

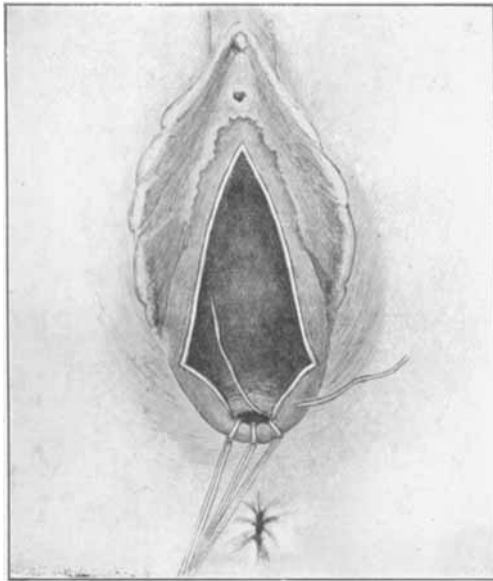


Fig. 4. Colporrhaphy combined with amputation of the cervix.

The first three sutures have been inserted and tied. They are left long and serve as tractors until the suturing of the cervical stump is complete. The fourth suture has been inserted through the vaginal wall and uterine wall into the cervical canal.

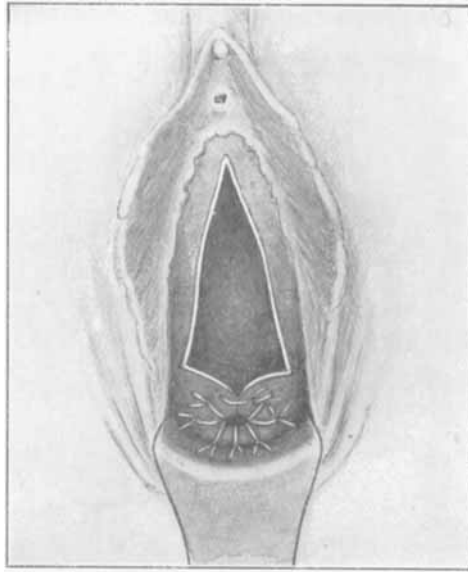


Fig. 5. Colporrhaphy combined with amputation of the cervix.

The suturing of the stump of the cervix is complete. The first suture uniting the sides of the wound has been inserted and tied.

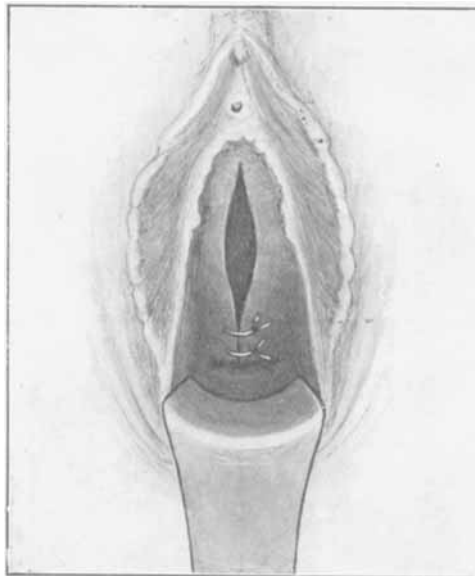


Fig. 6. Colporrhaphy combined with amputation of the cervix.

More sutures have been inserted, tied, and cut. The stump of the cervix has passed upwards and backwards into the hollow of the sacrum and is no longer visible. The uterus is now anteverted.

colporrhaphy; and, when these two operations have been done *seriatim*, the uterus is left in a position of retroversion, with the cervix looking downwards and forwards and much too near the vaginal orifice. It is therefore best to combine the two operations in one after a preliminary dilatation of the cervix and curetting.

The incision for this purpose is shown in Fig. II. When the vaginal wall enclosed by the incision has been separated from the bladder and the paravaginal and parametric tissue, the cervix is clipped round and round as far as may be necessary. It is then cut straight across so as to leave the uterus not more than three inches long. The amputated portion of the cervix comes away in one piece together with the flap of vaginal wall. Fig. III. shows the appearance of the wound. Figs. IV., V. and VI. show the way in which it is closed.

Catgut is the only suture material, as after this operation it is impossible to get access to the parts for the removal of stitches. When the stump of the cervix has been covered in the sides of the wound begin to approach one another in front of it. The cervix then recedes towards the hollow of the sacrum, and the remaining stitches must be tied with the fingers within the vagina. For if enough vaginal wall has been removed the sides of the wound will not come together unless the uterus is well within the pelvis. At the end of the operation the stump of the cervix is far back, high up and out of sight; the uterus is in anteversion. The perineum should be repaired so as to restore the original condition without unduly narrowing the vagina.

This operation has been completely satisfactory in several hundreds of cases. It has repeatedly stood the test of subsequent parturition and has been used for several patients over 70 years of age. It renders abdominal operations, hysterectomies and interpositions absolutely unnecessary even for the worst cases of prolapse. It should not be done (1) just before a menstrual period, (2) during the four or five months following parturition, or (3) until a clean and healthy condition of the parts has been secured by rest and treatment. The parts should not be irritated at the beginning of the operation by unduly vigorous attempts at disinfection. Vaginal packing should not be used at the end of the operation unless it is really necessary to check oozing. During healing vaginal douching should be avoided except in occasional cases which are complicated by infection of the wounds.