Trans Am Gyn Soc 1936 V-61

TOTAL VERSUS SUBTOTAL HYSTERECTOMY

A Clinical and Technical Study

J. R. Goodall, M.D., Montreal, Que.

THIS is merely an expression of opinion based upon personal experience arising out of 550 consecutive cases of hysterectomy, about equally divided into the two categories. The two series are as alike as possible in every circumstance and antecedent. In the first half of the series, the subtotals markedly preponderate. As my experience and finesse improved, the totals greatly outnumbered the subtotals, so that for the past year, the total hysterectomies constitute about 90 per cent of all my hysterectomies. The uterine pathology included all the common diseases. Many were complicated by appendage troubles of almost every variety. The uterine preponderant diseases were fibroids, fibrosis, corporeal malignancy, advanced cervical disease, chiefly in the third and fourth decades, and states of pelvic allergy associated with uncontrollable uterine hemorrhage. There were only five cases of cervical cancer, after treatment by radium, in which hysterectomy was deemed advisable.

I wish to state most emphatically that it is fartherest from my intention to force the unskilled gynecologic surgeon into an operation, graver than that for which he is fitted by experience. But to the skillful surgeon, to whom a slightly longer operation presents no greater deterrent than the extra time that is expended, the total hysterectomy, *caeteris paribus,* will present great advantages to the patient, as well as great surgical satisfaction.

There are advantages and disadvantages to each of the two types of hysterectomy.

The disadvantages of total hysterectomy are:

1. Greater time expended at operation.
2. Greater skill required.
3. Greater blood loss.
4. Greater danger to vital organs.
5. Greater difficulty if the pelvic organs are fixed deeply in the pelvic cavity, or if patients are obese.

The advantages of total hysterectomy are:

1. Fewer immediate postoperative complications.
2. Fewer remote sequelae.
3. Smoother recoveries.

history-of-obgyn.com

The disadvantages require no further elucidation. I believe they will receive general acceptance. On the other hand, the advantages may require considerable discussion.

The average difference between a subtotal and total hysterectomy is between five and fifteen minutes, a negligible factor in the average case. The skill required is merely that derived from experience, preferably primarily derived from one who has perfected the technic, with an accurate knowledge of the relative and absolute propinquity of the vital pelvic structures, and care in avoiding undue tension upon tissues. Tension is one of the greatest deterrents to forming union, and one of the most frequent causes of postoperative pain. The great onus of care in these cases surrounds the invisible ureters. To some they become a mental bogey. A ureteral complex, you will excuse the term, is one of the worst of emotional acquisitions in the surgeon. Some men seem to be unable to avoid them, and their mental stress to go wide of them seems to act like a lodestone.

To the best of my knowledge, I have never injured a ureter or bladder in hysterectomy. That does not mean that it has not happened, but merely, if it did, it was not only unobtrusive, but not even recognizable when sought. Operative bladder injuries are rarer than ureteral complications, in the experience of the general run of gynecologic surgeons. It is my experience that it is extremely difficult to injure the bladder when it is empty and contracted. It is one of the most elusive organs.

The difference in the blood loss in the two types of operation may be negligible. In the ordinary run of cases it is so. But it can be considerable, especially in hemorrhagic cases, or when a clamp or suture fails in its requirements. A word of caution here may not be amiss. A careful preoperative inquiry into the patient's history, as to untimely or copious uterine hemorrhages, nosebleeds, migraine, and familial history of vascular instabilities, may make one cautious in carefully suturing raw surfaces completely, and insisting upon a most thorough hemostasis. Where the history is at all suggestive of a hemorrhagic state, the usefulness of a preoperative blood transfusion and a repetition of the same on the seventh day after surgical intervention will obviate the serious oozing at operation, and prevent late postoperative bleeding. It is a singular fact that vascular unstables are prone to develop an advanced state of hemorrhagic tendency about the eighth day. This, though frequently occurring as an expression of a low state of sepsis, is also a sequel of low platelet count at that period, and, in most cases, can be forestalled by a carefully matched transfusion. These cases should be matched for three-quarters of an hour, and any abnormality should be guarded against. These nonseptic hemorrhagic cases are prone to develop wheals at the point of any hypodermic injection, and other signs of skin irritability. A special paper is being devoted to this important subject. Should the secondary hemorrhage be due to sepsis, it will occur

history-of-obgyn.com

usually between the eighth and twelfth day after operation. The sepsis is frequently ignored, because the temperature seldom rises more than a fraction above 99° F. and is usually continued over several days. It is in just these types of septic cases that either blood or vessel, or both, becomes so altered by the bacterial toxin, that diapedesis or rhexis occurs. Hemorrhagic states, as previously stated in my monograph on puerperal infections, rarely occur in acutely septic cases, but are most common in the continued cumulative low-grade infections, which do not rouse the body to the formation of antigens. When vaginal hemorrhage occurs, and it has occurred in my series of total hysterectomies in 2.25 per cent of cases, it has always been in these two types of cases: the vascular unstables, both septic and nonseptic; the vagina should at once be cleared of clots and packed gently with gauze with an uterine packer. To leave the vagina filled with clots is tantamount to inviting further bleeding. In every instance, this procedure, preceded by a transfusion, has promptly arrested the bleeding.

Generally speaking, total hysterectomy is easier in the parous than in the nulliparous, due to the greater mobility of the uterus, owing to the lengthening of its ligaments. Low set, fixed uteri may present unusually difficult surgical circumstances. Particularly is this so in cases of subacute or chronic pelvic inflammatory disease. But the difficulty, when overcome, brings a sense of great satisfaction, for it is in just these types of cases that it pays to remove the cervix with its susceptible mucosa.

About 70 per cent of patients who have total hysterectomies void spontaneously after operation, as against 45 per cent of subtotals. This circumstance, confirmed by all my house surgeons in the four different hospitals, seems contrary to all the laws of probability. An explanation has been sought, but nothing satisfying has been forthcoming. Is it that in the subtotal only, certain branches of the autonomic nervous system are severed, and that others are thereby thrown out of normal function; whereas, in the total hysterectomies, the majority, if not all, of the autonomic nervous system to the bladder is severed, causing the bladder, therefore, to become an automaton without sympathetic nervous control? In our present imperfect knowledge of autonomic vesical control and autonomic vesical distribution, it is quite impossible to vouchsafe anything but theories. Consult any work upon the results of section of the sympathetics upon vesical control, and one is led into a perfect orgy of contradictions and confirmations among the experimenters. The low percentage of spontaneous bladder evacuations in subtotals has been explained, by one of my colleagues, upon the basis of an inflammation spreading from the retained cervical stump to the bladder, an explanation that seems quite inadequate for many valid reasons.

Primary hemorrhage has never occurred in any one of the 550 cases, so that in this respect they are equal. Thrombophlebitis is a much more

history-of-obgyn.com

common complication in subtotal hysterectomies. The comparison is most striking. The percentage was three to one.

In all clean cases, thrombophlebitis may be taken as an index of a man's technic, both in obstetrics and in gynecology. Let this be most emphatically stated. So many, whether from ignorance or self-deception, assume that thrombophlebitis is an unpreventable misfortune, quite beyond their control. There is a ready explanation for the preponderance of thrombophlebitis in subtotals. It is to be found in the cervical mucosa. Just a few lines about pelvic thrombophlebitis. It is rarely diagnosable, except in its secondary complications. It is rarely acute, and most dangerous when of low-grade infection, or in its defervescence after an acute or subacute attack. The general agent of thrombophlebitis is an infection of low virulence and in the vast majority of cases it emanates from a mucosal disease. In this respect, the mucosa of the cervix fills all the requirements. Hence the relatively higher percentage of thrombophlebitis in subtotals, as against totals. The aseptic technic in both operations in my series was essentially the same, so the higher percentage must have been due to an agent residing in the tissues. And now, when upon the subject, it may be opportune to stress something which has not received sufficient attention: inflammatory diseases run very different courses, depending upon the tissues in which they are placed. Infections in mesoblastic and ectodermal tissues usually run a purely local and rapidly conclusive course, or a virulent and rapidly critical stage with an equally rapid cure. Restoration to normal function is usually complete in proportion to the rapidity of the disease, provided the patient survives the storm. In mucosal diseases, however, the great majority are subacute or chronic from their inception. Those that are not tend to become so eventually, and the tendency for the disease to linger indefinitely is the rule. This tendency leads eventually to two distinct changes, hyperplasia or hyperfunction, or both. The virulence dies down, and the corporeal reaction is then seldom sufficiently active to effect a complete cure. Thrombophlebitides are preponderantly mucosal in origin. In the cervical mucosa we have a classical example of these changes, and the organisms of the cervix are ready, in their attenuated form, to become the active agents of thrombophlebitis. That these organisms are still markedly pathogenetic can be clearly shown by the frequent incidence of secondary septic hemorrhage, when cervical amputations and suchlike operations were the vogue. Many of us in those years saw women, ostensibly in the bloom of health, submit themselves to cervical operations, only to be found on the 8th to the 12th day almost at the point of death, through septic hemorrhage. Why? Because we amputated through diseased mucosa. Why the delay to the twelfth day? Because the organism was semivirulent. Many of these cases developed pelvic thrombophlebitis and succumbed to its accidents. Mucosal disease is one of the greatest

history-of-obgyn.com

menaces to primary union. Can this mucosal menace be removed by cautery? That depends. In many cases, the disease is limited to the mucosa proper, an endocervitis. In others, the organism is invasive, causing a large, hard, cystic cervix, a cervicitis. In still others, there may be combination of both.

In cases of simple endocervicitis, coning out the cervix and cauterizing the residual portion of the canal may be effective. In the cervicitis types, cauterization, except it be very deep and destructive, is more harmful than no cauterization at all. The ideal remedy is total removal, when the skill and experience overbalance the risk.

Drainage was not used at all in any of the cases, and complete closure is a fixture.

Subtotal hysterectomy is often disappointing in its late sequelae. In a goodly percentage of my cases a leucorrhea developed, which did not exist prior to operation. In many cases, endocervicitis and ectropion developed after operation, necessitating treatment. This invariably leads to disappointment in the efficiency of operation. Both the above changes, I believe, can be attributed to the abnormal status of the cervix. Doubtless, in subtotal operations, the cervix must suffer changes in nutrition and nervous impulses, which eventually lead to a state of pathology.

That these abnormal changes are in part dependent upon the menstrual flux is shown by the infrequence of these abnormal developments when both ovaries are removed with the body of the uterus. In five of my patients, there were very troublesome cervical hemorrhages, that came on some months after subtotal hysterectomy. Four of these were operated upon for continuous metrorrhagia, that resisted every form of treatment; none of them showed any appreciable pelvic pathology, either by bimanual examination, or at the time of operation. Two of them had two sterilizing series of deep x-ray, with recurrence of hemorrhages after a period of amenorrhea. One had radium once, and three series of deep x-ray in doses estimated sufficient to sterilize, at least temporarily, if not permanently. It is my practice to cone out the cervix in all subtotals, and I feel very confident that no endometrium had remained, unless it had invaded the domain of the cervical mucosa. One is inclined to believe that, in some of these cases, vicarious menstruation is set up. This is a very logical conclusion, when one considers that the genital canal, from the fimbriated end to the hymen, is developed from a common "anlage," yet it exhibits four variations of epithelium, and four widely different functions. And when we consider that the endosalpinx, endometrium and vagina respond to the menstrual cycle, it would be extraordinary did not the cervix show a similarly periodic change.

In one such interesting case, a woman at 42 first came under my observation. She had had a subtotal hysterectomy for fibroids, five years previously. For the past

history-of-obgyn.com

year she had regularly periodic discharges of blood, simulating menstruation, every three weeks. She was an intelligent English woman, who said that the blood was unlike menstruation in that it came on and stopped more slowly than normal menstruation. She came fearing cancer. Nothing abnormal could be found on examination. Operation for other causes had to be done, and the stump was removed at the same time. It showed no trace of pathology. It is necessary but to mention the incidence of carcinoma in the stump of a subtotal hysterectomy. The assurance to a patient that cancer of the uterus is an impossibility after total hysterectomy is a comfort to the patient in which the surgeon rightly shares. Cancer of uterus is a constantly recurring fear in the emotional life of every woman of postmaturity.

It is not a matter of indifference whether one allows the ovaries to remain. With their removal, the incidence of late cervical pathology is greatly reduced; the incidence of immediate and intermediate postoperative hemorrhage is reduced, especially in vascular unstables; and the late return of bleeding from the stump is practically unknown after total removal of the ovaries, except in cases of newgrowth. There is not the slightest doubt that ovulation, estrin and progestin formation keep the tissues in the pelvis in a constant state of flux, with varying nutritional changes, rendering them much more susceptible to changes bordering upon, or invasive of, the domain of pathology.

My final plea is, if one's skill and experience warrant, if the case is a suitable one, a retrospect of cases shows that the total hysterectomy has much to commend it, above a subtotal. Where, on the other hand, the surgical risk, arising either in the surgeon or in the patient, would make the immediate risk the greater, then pursue the course that your conscience will dictate. But do not stop there, as regards the welfare of your prospective cases. Make yourself as proficient in the total as in the subtotal. It can be done. The mortality in this series is nil. The rest is in the lap of the gods.

TECHNIC OF TOTAL HYSTERECTOMY

The vagina is cleansed with sterile liquid green soap, and thoroughly dried. Care is exercised to empty the bladder completely.

Catgut, of the plain variety, chiefly Davis and Geck product, was used throughout. No. 2 was used for all major ligature purposes (never any larger size), and No. 1 for all peritoneal work. A minimum of catgut in each case was used. In over 90 per cent of cases, six No. 2 ligatures were sufficient. These were, ligation of the infundibulopelvic ligaments or the uteroovarian broad ligament, depending upon whether the appendages were to remain, or not. The next two ligatures are upon the lateral upturn of the uterine arteries, and the last two are upon the lower uterine branches, as far down as the fornices. The vault of the vagina is sutured continuously in two layers, with single No. 1, or No. 2, catgut as described later, and the peritoneum of the pelvic floor is united always by a single continuous No. 1 suture. Curved noncutting needles are used throughout, except when sewing the cervical stump in subtotal hysterectomy. I cannot overemphasize the importance of this little precaution. Round needles transfix. Cutting needles make a buttonhole and cause much unnecessary bleeding.

history-of-obgyn.com

OPERATION

The abdomen having been opened, the patient is placed in an exaggerated Trendelenburg position. The intestines are then packed off, and the pelvis explored. In the uncomplicated cases, one determines at once whether the appendages are to be removed or not. If these are to be removed, they are held up by the hand of an assistant or by the operator, and the broad ligament *"clear space"* is located. This is a space below the ovary, bounded internally and outwardly by the uterine vessels. It consists merely of two layers of peritoneum, without any appreci-

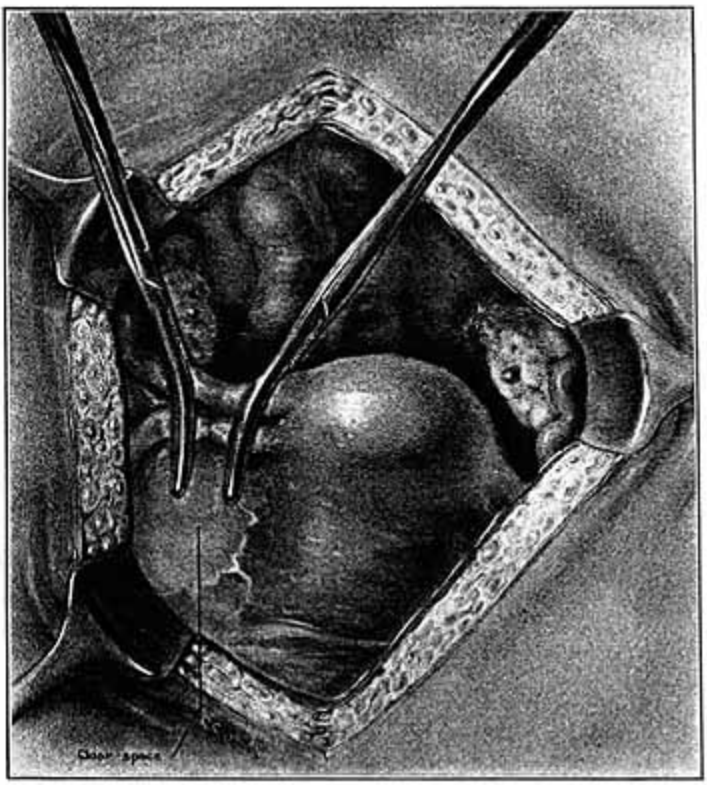

Fig. 1.

able tissues between them. If the finger impinges upon this area from behind, the digit will shine through anteriorly, or if the broad ligament is held up when tissues are lax, the space is translucent. A "Kelly" curved clamp (Fig. 1) is now placed upon the infundibulopelvic and round ligaments, having its tip in the clear space, and its convexity inward. A second and similar clamp is now placed upon the broad ligament between the ovary and uterus, with its tip juxtaposed to the tip of the first clamp. The appendages on that side are now completely isolated vascularly. In ordinary cases, the second clamp will include the proximal end of the tube, uteroovarian and round ligaments. This second clamp should be placed with its convexity outward. The appendages are now excised, being careful to leave at

history-of-obgyn.com

least a quarter of an inch of tissue protruding through the forceps at the cut margin. This is to prevent slipping. The Kelly forceps should have longitudinal rugae along the whole blade, except at the tip, where they are corrugated, to prevent slipping.

The infundibulopelvic and round ligaments are now ligated by a figure of eight, which should transfix the round ligament, then through the "clear space," and again transfix the round ligament in the opposite direction. Ligation is then completed. The clamp should be released slowly as the ligature is tightened. I cannot

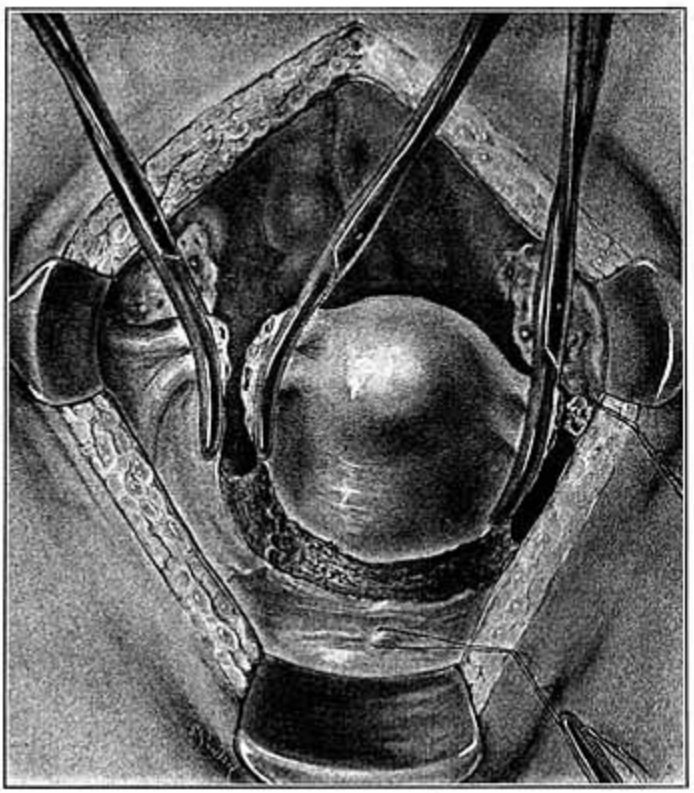

Fig. 2.

overemphasize the importance of this little procedure. Too quick release of the clamp, specially when dealing with the uterines, is inviting trouble, by allowing the tissues to escape from the grasp of the ligature.

The infundibulopelvic ligature is left long, and held by a forceps. On the opposite side the appendages are to remain. The "clear space" is again defined. The ovary and round ligament are pulled toward the pelvic wall and the first Kelly forceps is placed over the broad ligament, proximal to the ovary. Its tip should be in the center of the "clear space." Its convexity should be inward. A second is placed parallel to this, separated by one-third to one-half inch, with its convexity outward. These clamps include, in uncomplicated cases, tube, uteroovarian

history-of-obgyn.com

and round ligament. Incision and ligation is now performed as described above, being careful to transfix the round ligament. There remain now but two Kelly clamps, which act as tractors upon the uterus. It is never necessary to grasp the uterus with volcella or any other form of tractor. These cause unnecessary loss of blood and tearing of tissue.

By its tractors the uterus is now pulled up and backward by the assistant, and the vesicouterine pouch exposed, by an anterior retractor. The anterior leaf of the peritoneum is now picked up on the left side at the vertex of the incision in the "clear space," and with a curved scissors, the peritoneum is incised in a curved

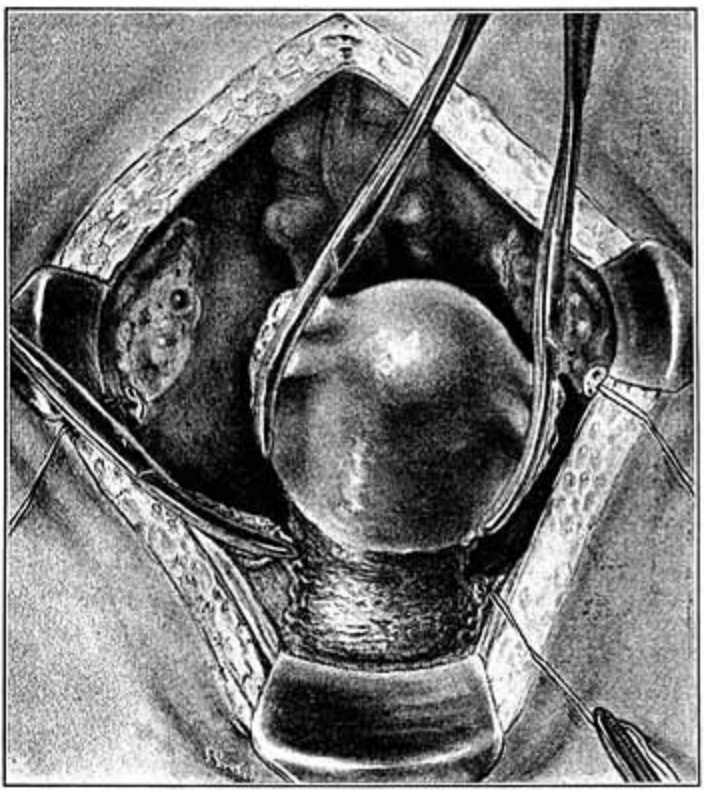

Fig. 3.

line in the vesicouterine peritoneal reflexion. The incision should end in the anterior leaf in the right "clear space." The operator now takes hold of the tractors with the left hand, and, with the index finger covered with one layer of sponge, the bladder is pushed down from the uterus and cervix. A No. 2 catgut now is made to transfix twice the bladder muscularis and vesical peritoneum (Fig. 2). This is not tied, merely held by an artery forceps. Traction is now put upon it by the second assistant, and a long special retractor measuring 2¾ by 4¾ is slipped below the reflected bladder, and the whole anterior wall of the uterus is now exposed. The uterus is again held by the operator and the separation of the bladder is now completed by the sponge-covered finger, down to the junction of the upper and middle

history-of-obgyn.com

thirds of the vagina. An additional precaution lends a great deal of comfort. This consists in pushing the garnished finger well out on either side of the cervix and vagina, to separate the bladder from this region and to displace the ureters outwardly. A "Kocker" forceps with museux tip is now placed upon the upper uterine artery, at right angles to the uterine wall (Fig. 3). Its tip should impinge well into the uterine muscularis. Ordinarily it should be not less than ½ inch and not more than one inch above the portio. This can be easily determined by a finger of one hand in the anterior, and another finger posterior to the vagina. A similar clamp is placed on the opposite uterine at the same height. The artery is now cut ¼ inch from the clamp margin on both sides. In cases of large uterine tumors, it is neater to place on each side, a second similar clamp ½ inch above the first ones, to prevent a large escape of blood into the pelvic cavity. With a curved round needle the

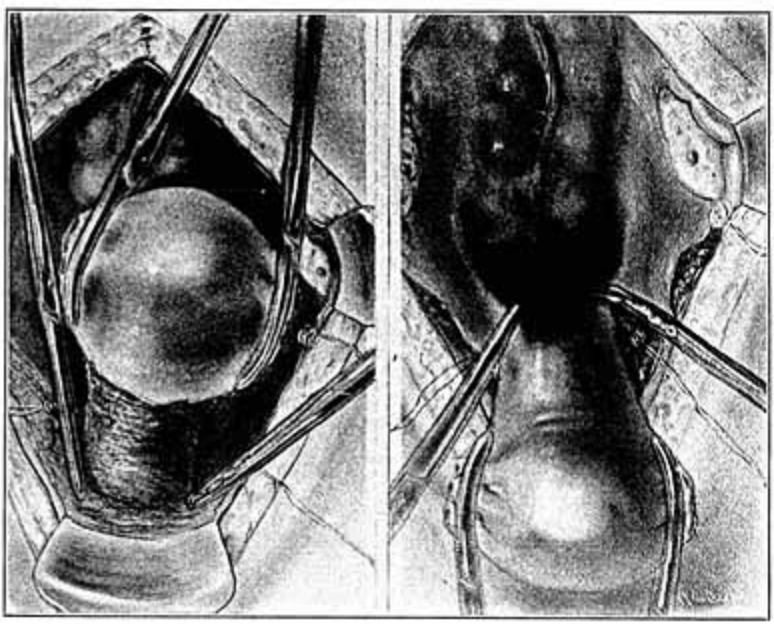

Fig. 4.

tissues are transfixed just below the forceps. The needle should not be driven through too close to the uterine wall, for reasons which will appear later. Ligation is now completed on both sides, and the clamps are removed.

The next step is securing the cervical branches of the uterines. Proceed as follows. First make sure that the bladder is clear, as above described, and held well out of the way of the cervix. Hemostasis should be complete. With the tractors pull the uterus up and out of the incision, and toward the symphysis, and expose the pouch of Douglas. Define the uterosacral ligaments (Fig. 4). Have your assistant pull the ligature on the upper uterine outward. Span the lower uterine with a "Kocker," placing the tip of the posterior blade mesial to the uterosacral of that side. Having made this impression posteriorly, turn your attention to the anterior blade. See that it is deep enough to go beyond the fornix. Then close it tightly on the cervix. Repeat the process on the opposite side. Care in placing these

history-of-obgyn.com

clamps ensures safety to the ureters and bladder. The assistant now takes the handle of this forceps and draws outward and the operator cuts with a scissors boldly down the broad ligament, cutting always upon the cervix so as to leave one-fourth of an inch of tissue beyond the forceps on the cut side. The fact that you have reached the fornix is announced by a hollow sound quite different from that of the cervical tissues when severed by scissors. The process is repeated upon the other side of the cervix. When properly placed these last two straight clamps should converge at their points. The tissues uniting the lateral fornice to their broad ligaments are very loose and relatively bloodless, so that a portion of the lateral wall of the vagina can usually be freed, to equal that previously attained on the anterior wall. The assistant now holds the handle of the "Kocker" outward, the fornix of the vagina is now grasped with an "Allis" forceps on each side, the vagina is transfixed with a scalpel anteriorly, and the lower margin of the cut surface is caught with an Allis forceps. The circumcision of the vagina is now completed, above the two Allis forceps on the fornices (Fig. 5). The posterior vaginal wall is also grasped with a

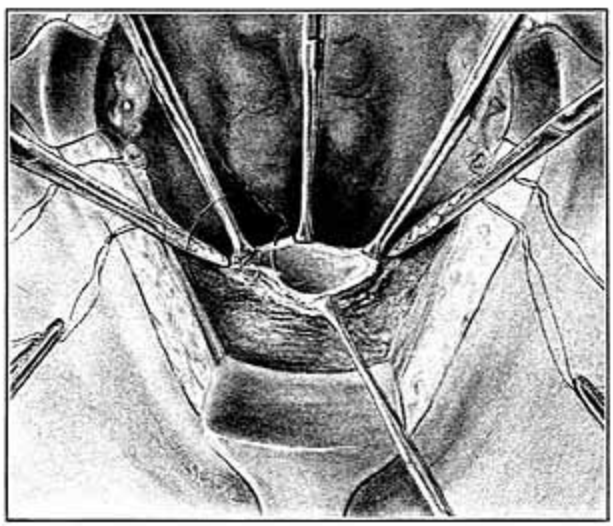

Fig. 5.

similar forceps. The vaginal vault is now defined by these four Allis forceps: one anterior, one posterior, two lateral. Any vessel in the paravaginal tissues (usually on the posterior wall) is caught within the grasp of an Allis. It is recommended that hemostat crushing forceps never be used where an Allis or other toothed non-crushing forceps will better serve the purpose.

It is never necessary to ligate the vaginal vessels. A continuous single No. 1 or No. 2 plain catgut (it should be long) is now used to close the vagina. One should begin at the patient's right, transfix from behind forward, and tie the first suture below and outside the Allis on the right lateral vault. The end should be held. Then continue across the vagina, being careful to close the left fornix completely. This suture should incorporate only the vaginal mucosa. Having reached the vicinity of the tip of the left Kocker, which still holds the lower uterines, the operator places a second layer over the vault, with the same continuous suture (Fig. 6). This should include posteriorly the intermediary tissues between the vaginal mucosa and peritoneum of the Douglas' pouch (including the latter, if so desired), and anteriorly

history-of-obgyn.com

usually a well-defined cut layer of fascia between the base of the bladder and the vaginal wall. This is important in fixing the bladder from a sliding prolapse. The suturing should laterally stop short of the tips of the Kockers. The vault closure is now complete with the tying of the two ends of the continuous suture.

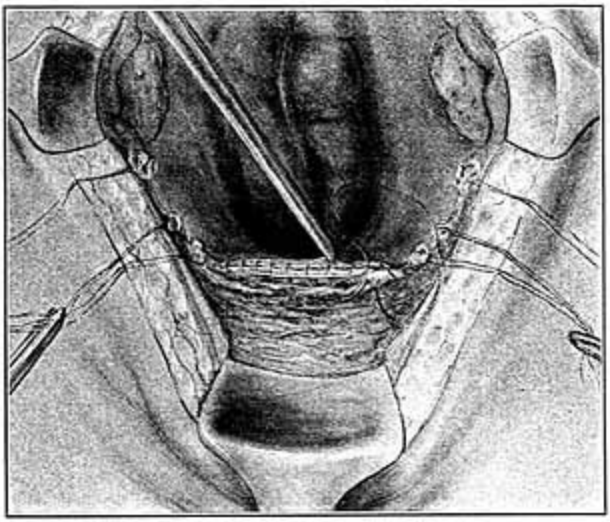

Fig. 6.

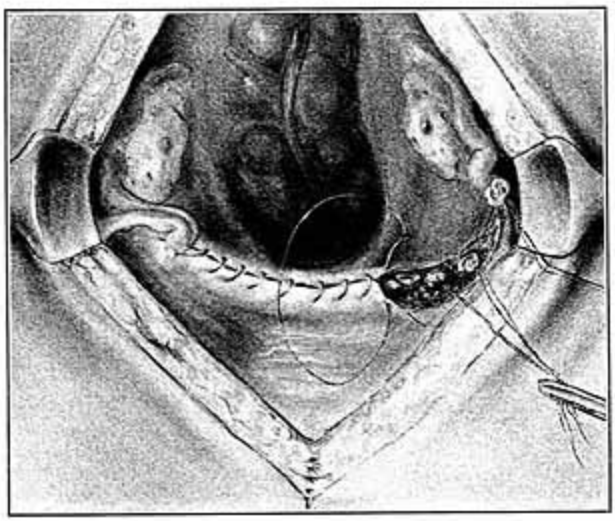

Fig. 7.

The lower uterines are now tied by transfixing the broad ligaments, just exterior to and slightly above the tip of the forceps, to insure that the ligature will remain distal to the forceps. The ligature is now looped and tightened down to the upper

history-of-obgyn.com

margin of the tissue within the grasp of the forceps, as the handle of the Kocker is held toward the median line. The assistant now pulls the *handle* of the Kocker outward and the *tip* inward, and when so held, the operator tightens the suture, and, upon his dictum, the ligature is tightened synchronously as the assistant slowly releases the clamp. This ligature is inside the one previously placed upon the upper uterine. As a further precaution the ligature upon the lower uterines may now be tied over the ligature of the upper uterine ligature, in Staffordshire fashion. I have abandoned this method as unnecessary and productive of more knots for internal digestion.

Hemostasis should now be complete. The pelvic peritoneum is now closed as follows (Fig. 7). This is the most dangerous part of the operation. It is in this procedure that damage or ligation of the ureters most frequently occurs. I have catheterized the ureters in many cases, to demonstrate this. No. 1 single continuous is used. The posterior leaf of the clear space on the right is transfixed, then the suture is carried through the stump of the infundibulopelvic ligament (if appendages have been removed), or of the broad ligament (if appendages remain) internal to the primary ligature, and then it should pick up the layer of the anterior peritoneum beyond the round ligament. The assistant now pulls the ligature inwardly and one ties over the stump. The primary ligature and the single end of the continuous are now cut. One continues inwardly from right to left, closing posterior and anterior layers of peritoneum. As soon as one approaches the ligated uterines, one must proceed with greater caution. It is just here that the ureter emerges from among the uterine vessels and is covered only by a layer of peritoneum. Care should be taken that only peritoneum is included in the suture bite on the posterior wall. Once one has got past the right uterine ligature, one can proceed with impunity until the left uterine ligature is reached, where similar precaution is necessary. The left stump of the broad ligament or infundibulopelvic ligament is treated in a manner similar to the right. This line of suture draws the lateral supporting structures into a firm band of support in unison with the vaginal vault. The pelvic peritoneum has now been completely closed, and should be quite free from any exposed raw surface. Peritoneal toilet and closure of the abdominal wound complete the operation.

1472 Sherbrooke Street West

history-of-obgyn.com