

ELEPHANTINE DEVELOPMENT OF THE CLITORIS.

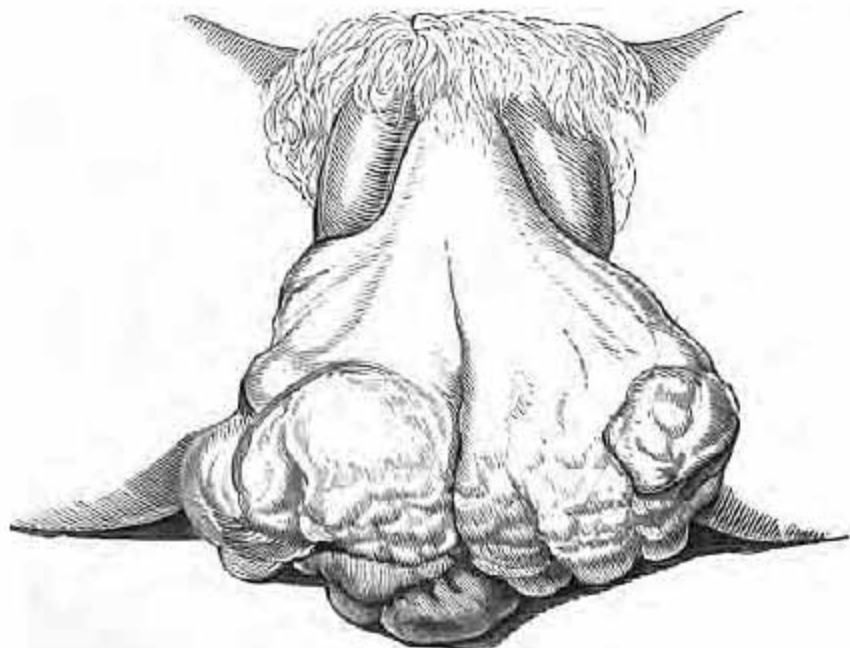By W. R. ROGERS, M.D., M.R.C. Phy. Lond.,

PHYSICIAN TO THE SAMARITAN HOSPITAL FOR WOMEN AND CHILDREN.

I VENTURE to think the subjoined short case not unworthy of being brought to the notice of this Society, illustrated as it is by the accompanying drawings of life size.

It shows to what extent of disfigurement a habit unfortunately too prevalent may transform the natural parts, especially when the constitution is tainted with syphilis.

FIG. 7.

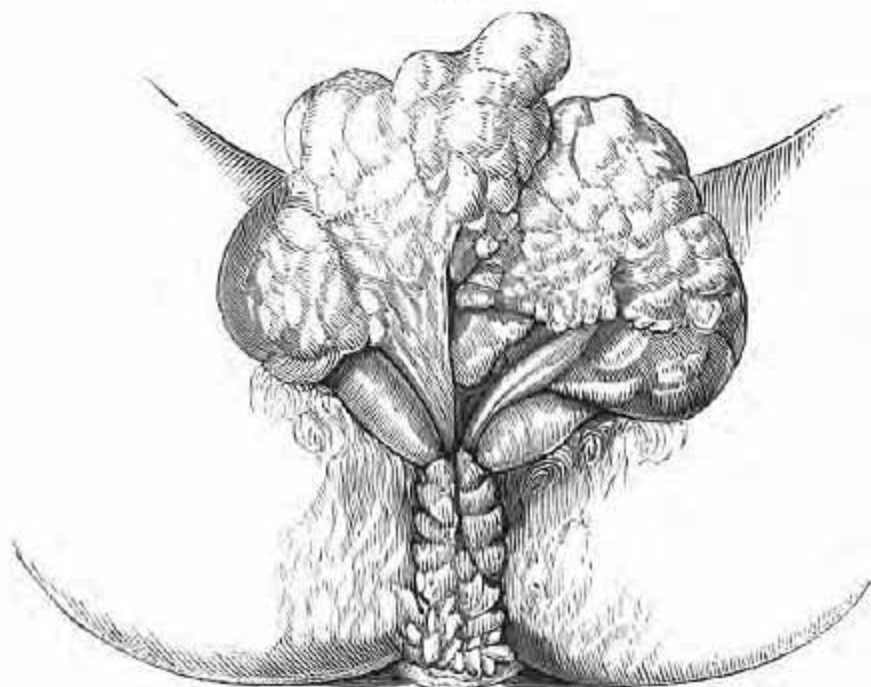


Mary R., æt. 25, admitted into the Samaritan Free Hospital, November 19th, 1866. She was in a very reduced state of health from the discharge and irritation of her privates, from the enormous size of the clitoris, and of warty growths around the anus. On careful examination her

lungs were found tuberculous; her mother died of phthisis some years before. On questioning the patient she admitted having had sexual intercourse several times with a young man whom she believes never had syphilis; previously she masturbated occasionally. On his death four years ago she recommenced the habit, till it brought on the enlargement now seen in the drawings. The discharges from the larger growth she thinks brought out the smaller ones around the anus. She concealed her wretched state as long as she could, and was then sent to the Samaritan Hospital.

After a course of cod-liver oil, steel and quinine, which greatly improved her health, I ligatured the elephantine

FIG. 8.



clitoris, having frozen it by two of Dr. Richardson's ether spray jets, and cut off the smaller growths. The part came away in a few days, and healed rapidly, leaving no disfigurement; all irritation subsided, and no one would now imagine that any operation had been performed on the parts, as there

is a good-sized and nearly normal clitoris remaining. Dr. Churchill in his fourth edition of the 'Diseases of Women,' page 72, figures from Dr. M'Clintock's work on 'Diseases of Women' a similar growth; there is a like suspicion of syphilitic contamination in mine as in Dr. M'Clintock's case; but no mercury or iodide of potassium was given. She left the hospital to return home, the parts natural in every respect.

Fig. 7.—Front view of enlarged clitoris.

Fig. 8.—Back part of clitoris, which has been raised and turned up to show its posterior aspect and entrance to vagina; perinæum and anus covered with warty growths. These woodcuts are greatly reduced from the natural size.