

THE
NEW YORK JOURNAL
OF
GYNÆCOLOGY AND OBSTETRICS.

SEPTEMBER, 1893.

PATHOLOGY AND TREATMENT OF INJURIES OF THE
PELVIC FLOOR,¹

WITH SPECIAL REFERENCE TO SUBCUTANEOUS LACERATIONS OF THE
LEVATOR ANI AND TRANSVERSUS PERINÆI MUSCLES AND
THE FORMATION OF RECTOCELE.

BY ALEXANDER J. C. SKENE, M. D.,

Brooklyn, N. Y.

I intend to add a few items to a subject that has already been elaborately treated by many writers. Such minor contributions as I have to offer could be soon made, were it not that in order to show the effect of the few touches which I propose to add to the original portraiture, abundantly presented in medical literature, it is necessary to reproduce in brief outline the portions which I desire to treat. The few facts which I have to present have been gathered during observations made from the standpoint of both physician and surgeon. In obstetric practice one has an opportunity to investigate lesions at

¹ Read before the The American Gynecological Society, May 17, 1893.

This paper has already appeared among the original contributions both of the American Gynecological Journal and The Annals of Gynecology and Pædiatry. Its author promised this journal the paper some time ago, and we assume that its appearance in the columns of our contemporaries, other than in abstract, is due to carelessness of Dr. Skene's secretary or to the stenographer. We present with the paper reproductions of Dr. Dickinson's excellent illustrations, and believe no further explanation is necessary for again publishing this valuable contribution.

the time when they occur, while a surgeon has an opportunity to study the pathological changes which takes place subsequently. This method of investigation should lead to definite and accurate conclusions, provided the observer has clear views regarding the anatomy and function of the pelvic floor, the injuries of which are under consideration.

Regarded as a mechanical structure the pelvic floor resembles a diaphragm composed of muscles and fascia which close the pelvic outlet. Its borders are attached to the bony walls of the pelvis, and it is held at its proper elevation by the levator ani muscle. Its mechanism is based upon the principles of the suspension bridge, the anchorage being represented by the pelvic bones, the floor representing the bridge and the levator ani muscle corresponding to the sustaining cable. (See figure I.) To make sure of being understood, the following classification is offered for consideration, and criticism, if need be:

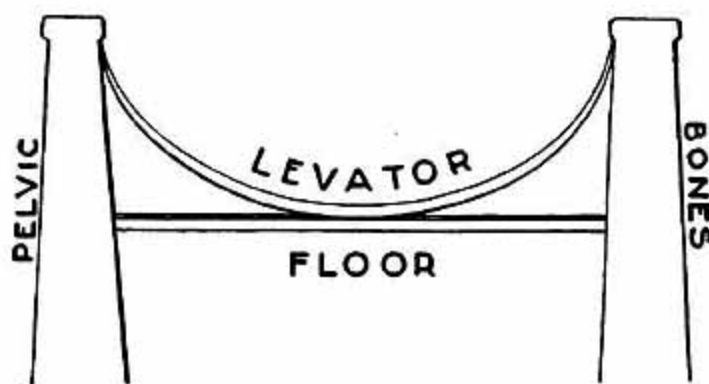


FIG. I.

All the injuries that are sustained by the pelvic floor are divided into two classes: first, those that occur in the median line of the floor and in a direction corresponding to the axis of the pelvis; and, second, those injuries which occur above the floor itself, transverse internal lacerations. The laceration in the median line occurs in various forms and degrees; first, a solution of continuity of all the tissues extending from the posterior commissure to the sphincter ani; second, the same injury as the above plus laceration of the sphincter. These are the injuries which have been recognized for ages: to these I have added another which I have found during my investigations, viz., subcutaneous lacerations of the muscles and fascia in the median line, usually limited to

the transversus perinæi muscle and fascia, but in rare cases involving the sphincter ani muscle.

Years ago, when I first called attention to this subject, I was not aware that the sphincter ani was ever involved in this form of injury, but I have seen since then at least three cases in which the sphincter ani was lacerated completely while the integument and mucous membrane of the vagina remained uninjured. The evidences that my observations were correct are that there was incontinence, the integument on either side was depressed where the lower fibres of the retracted muscles had drawn it inwards, and the most careful examination proved beyond a question that the integument had never been lacerated. I am aware of the fact that a complete laceration in the median line may unite by first intention leaving the sphincter ani ununited, and that the scar may be so faint as to be easily overlooked, but in the cases I have referred to I am positive from my own examination, and that of my associates, that no such injury to the integument ever occurred. Furthermore, I found in operating that when the integument was divided some thickening of the cellular tissue was apparent, due no doubt to a reparative exude which occurred at the time of the injury. I also found the ends of the muscle far apart, the lacerated ends being completely healed over by natural processes. In looking back I recall several more cases of this kind, but not having studied them with sufficient care, they are not available for my present purpose.

Injuries of the second class, which are transverse, and have been described as internal lacerations, consist in laceration of the anterior fibres of the levator ani muscle and fascia, and this is usually attended with separation of the muscular layer of the vaginal wall from the pelvic floor. In some cases the laceration is complete, involving the mucous membrane as well as the muscular coat of the vagina, and in very rare cases the laceration reaches upwards and outwards as far as the laceration of the levator ani muscle extends, but as a rule the laceration of the levator ani is subcutaneous, that is to say, not attended with laceration of the mucous membrane of the vaginal wall. The injury of this muscle I believe was first described in my early writing on the subject, but if this is an unjust claim on my part I shall be happy to have it corrected at this time.

In regard to the pathology of complete lacerations in the median line, nothing need be said as the subject is familiar to those who have interest in the matter, excepting subcutaneous lacerations of the

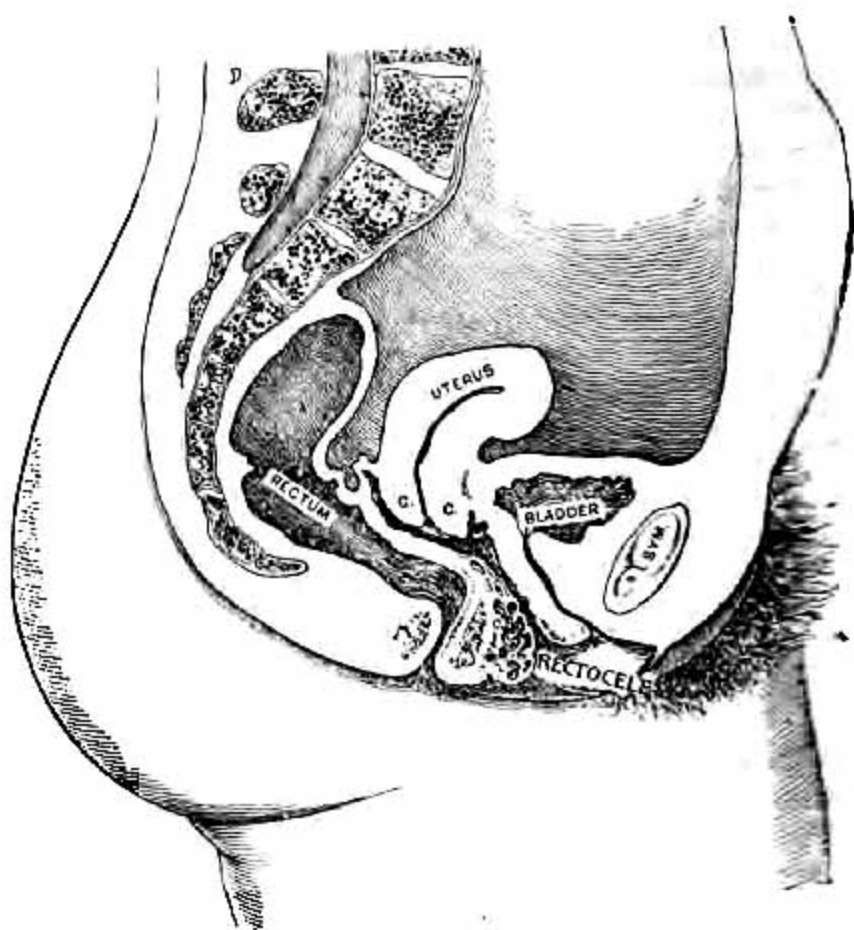


FIG. II.

muscle and fascia. These escape notice at the time when they occur unless carefully looked for. They are easily detected however, by grasping the pelvic floor in the median line between the thumb and finger. By this manipulation it will be found that all the structures, except the mucous membrane of the vagina and integument, have been divided and retracted, and there is nothing left of the fascia and muscular structure in the median line excepting the sphincter ani muscle.

The transverse internal laceration, when entirely confined to the muscular structures of the vagina and levator ani muscle, is not an easy lesion to detect owing to the fact that a similar condition is produced by sagging of the pelvic floor, following delivery and temporary paralysis.

The pathological changes which ultimately take place in the transverse lacerations are: A marked sagging of the pelvic floor, which in itself may be perfectly normal in structure. This sagging is apparent upon inspection, and as I have elsewhere pointed out, the diagnosis of this laceration is made from the fact that under stimulation the levator ani muscle fails to perform its function. The action of this muscle is to a large extent voluntary, and this voluntary power is lost and stimulation fails to call it into action. Of course the continuation of this sagging gives rise to or permits prolapsus of the vaginal walls, uterus and bladder. Rectocele is also said to follow in this injury, and possibly it may in rare cases, but I am fully assured from careful observation that the so-called rectocele is not a rectocele at all, but a prolapsus of the vaginal wall and a varicose condition of the veins lying between the vagina and the rectum just within or above the pelvic floor. This I have been able to demonstrate, in a vast majority of cases, by an examination which proved that there was no rectal diverticulum pointing towards the vulva, and that pressure upon the so-called rectocele caused it to disappear as soon as the blood was pressed out of the enlarged veins. This is shown in figure II. An argument which has been made against this by one of my friends, to whom I have explained my views on the subject, is that he has noticed in faecal accumulations the rectocele protruded through the vulva, especially on voluntary efforts being made to evacuate the rectum. This is offset by the fact that in most of such cases I have found that when the rectum is emptied its muscular walls contract and there is no diverticulum left. Of course the rectum loses its support when the levator ani muscle is lacerated, and is easily overdistended, and the distension must be towards the vagina and vulva, but is tem-

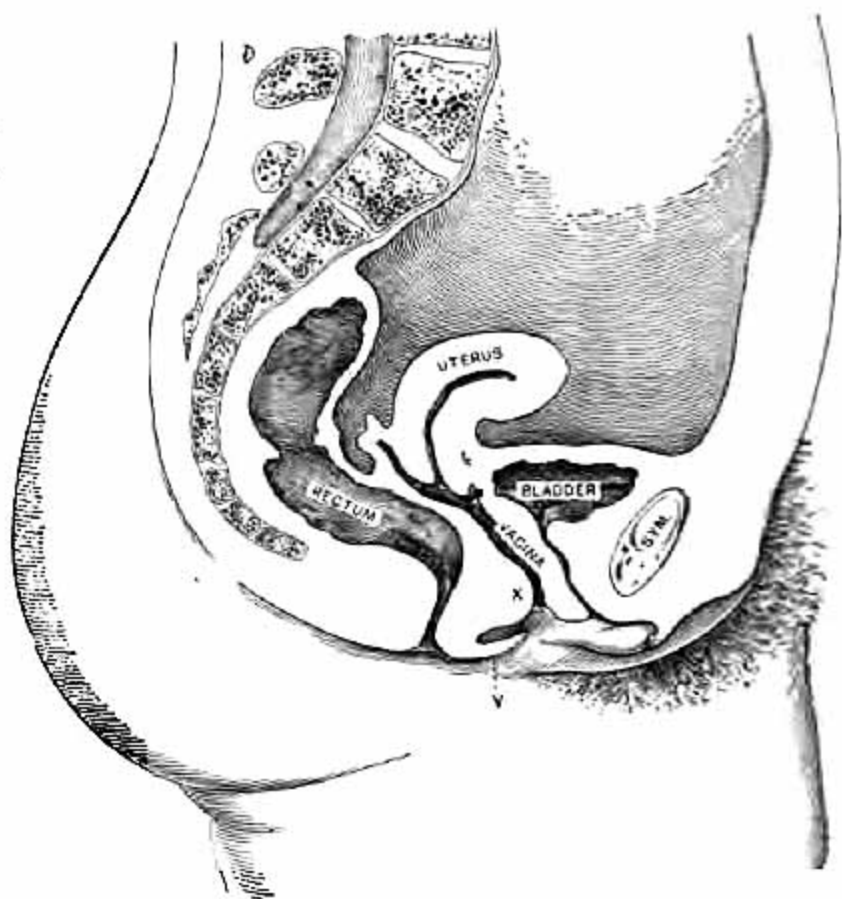


FIG. III.

porary, not permanent, and hence not a rectocele. I may say further in reference to this form of injury that it is followed by pathological changes which give rise to more distressing symptoms than any other. It is in this form of injury that prolapsus more frequently occurs, not only of the uterus and vaginal walls, but also of the bladder; and there is greater liability than in any other injury to the formation of varicose veins around the lower portion of the vagina and rectum, which give rise to no small degree of suffering. In this injury, too, subinvolution of the vagina and uterus most frequently occurs. All this has been clearly pointed out by Dr. Emmet, and by him alone as far as I have been able to discover. More than that, I believe that there is in addition to the subinvolution of the vagina a certain degree of areolar hyperlaxity, which accounts for the extraordinary thickening of the vaginal walls seen in this class; still more, if relief is not obtained there comes a time when atrophic changes of the vaginal walls take place which cause further changes in the venous circulation, and if the injury goes many years without repair, atrophy of the levator ani muscle occurs, and such changed structures become absolutely incurable by any method of operating. It is quite a number of years (sixteen or eighteen) since I called attention to the atrophic changes in the muscles which take place in cases of long standing, and though a certain amount of temporary relief is obtained by operating, prolapsus of all the pelvic organs recurs.

I formerly believed that in connection with transverse lacerations a subcutaneous laceration very often occurred, but I am satisfied now, after more extended observation, that in place of a laceration there is a thinning out and absorption of the tissues in the median line which produces a condition similar to that of subcutaneous laceration. This absorption is brought about by the sagging of the pelvic floor which makes undue traction upon the transversus perinæi muscles and fascia and as the posterior wall becomes prolapsed additional pressure is made at that point, and hence the absorption or atrophy which takes place in the median line. This change of structure resembles in every particular the lesion of subcutaneous laceration, but it is only found in cases that have existed for a long time, in which there is marked prolapsus of the vaginal walls and, of course, great sagging of the entire pelvic floor. These facts in regard to pathology have a very important bearing upon the question of treatment, as will be noted further on.

In laceration of all the tissues from the posterior commissure down to the sphincter ani muscle the scar tissue is the only pathological con-

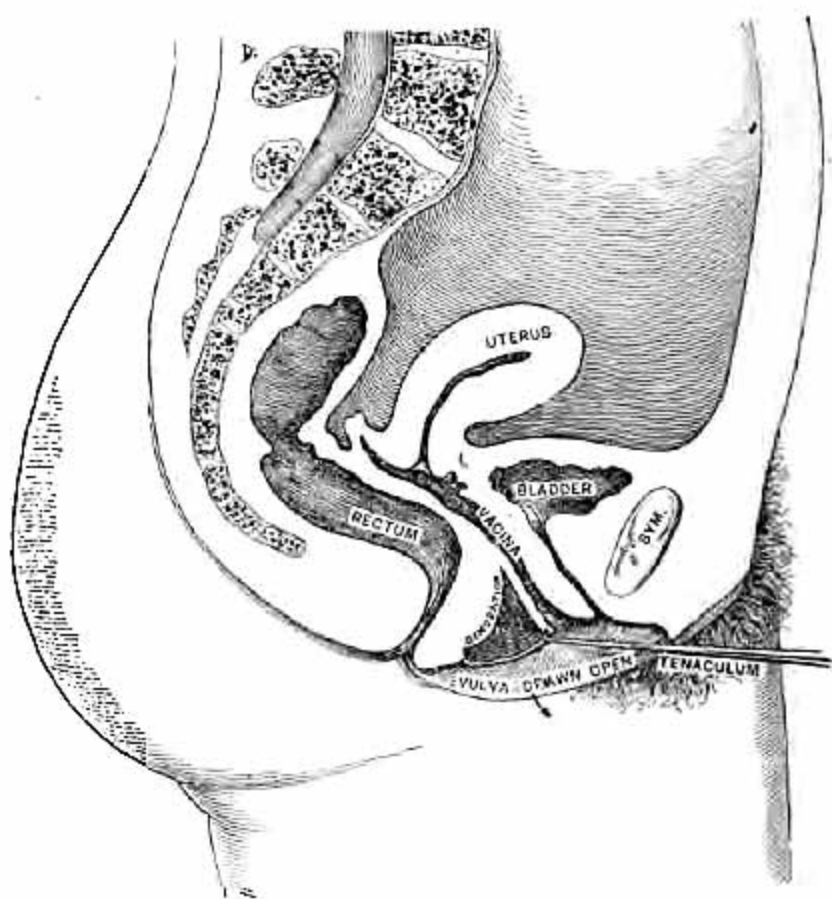


FIG. IV.

dition which is found and that rarely gives rise, at least for a number of years, to any suffering, because if the levator ani and the bulbo-cavernosus muscles are uninjured the remaining portion of the pelvic floor is brought forward and sufficiently closes the vulva to prevent prolapsus of the pelvic organs.

In regard to complete laceration involving the sphincter ani, I accept in full the pathology and treatment as described by Emmet, especially the treatment. A word, however, may be said with reference to certain changes which take place in subcutaneous laceration mentioned above. Immediately after it occurs it is easily detected, but after convalescence from confinement an examination will show an apparently sufficient pelvic floor, because the space between the divided ends of the muscles and fascia is filled in with an exudate which restores for the time-being the appearance of that ring or band which closes the vulva, and which has been called the perineal body, without any very good reason for the name. In a few months this exudate becomes absorbed and the pelvic floor at this point becomes thinned out and presents the physical signs to the touch that are present in the recent injury. See figure III. There is in this form of injury a little more sagging in the middle portion of the pelvic floor than is found in complete laceration.

TREATMENT.

While one can easily understand that during the experimental stage of plastic surgery of the pelvic floor many different operations were practiced and commended by numerous surgeons, there is no reason for so many different ways of surgically treating injuries of the pelvic floor at this time. As there are certain definite lesions, and the object of surgery is to restore the injured structures to their original condition, or as near as art and science can do so, there should be, by this time, more definite agreement among operators regarding this branch of plastic surgery. Perhaps the diversity of opinion arises from the fact that the exact nature of the injuries and the changes of structure which subsequently occur are not clearly understood. It may be for some such reason that in this department of gynecology there is such an extraordinary diversity in both theory and practice.

I operate simply by removing the scar tissue, and in so doing vivify the ends of the muscles and fascia that have been divided, when, in the median line, injuries extend from the posterior commissure to, and include all the tissues of the pelvic floor at this point. The vaginal

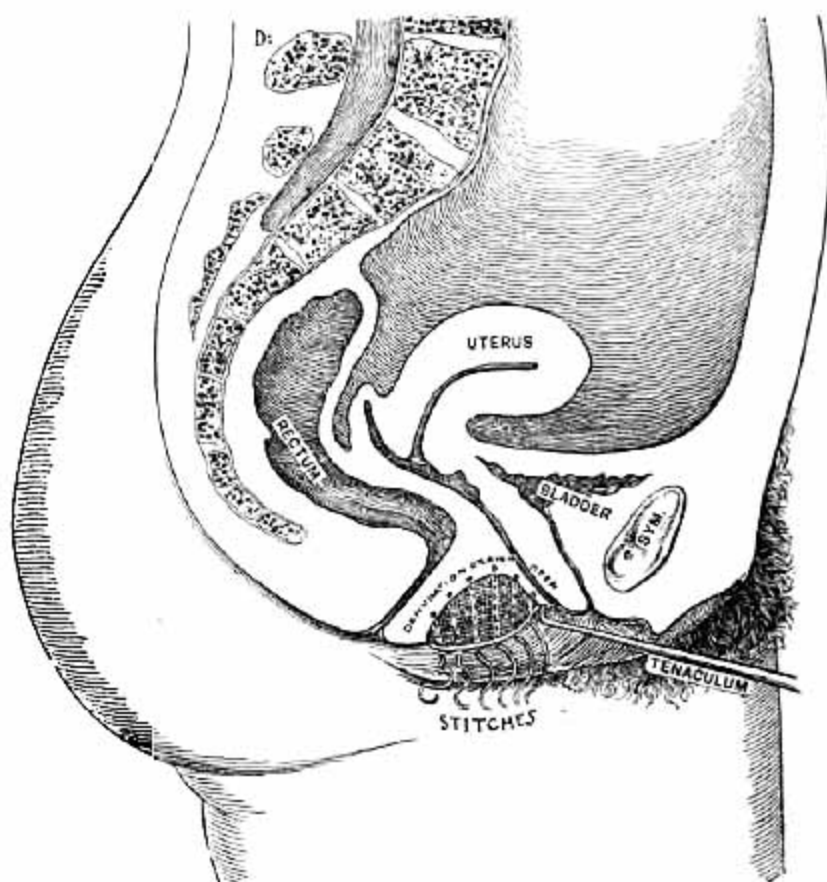


FIG. V.

wall which has been attached to the lower angle of the laceration is liberated and raised up so as to form the inner surface of the pelvic floor. The lateral surfaces are united with sutures, the upper two or three taking in the posterior surface of the vaginal wall, and uniting it to the inner surface of the pelvic floor.

In complete laceration involving the sphincter ani, I follow closely the principles involved in the operation as laid down by Dr. Emmet. If in any way I differ from him in some of the minor details, such as using silk in place of silver sutures, it is simply because it is convenient for me personally to do so, not with any disposition to try to improve upon what I conceive to be a perfect operation. This much of the treatment might be summed up in a sentence as follows, viz.: That in this class of injuries I follow the methods which appear to me to have resulted from the contributions of all the best operators from Baker Brown to Thomas Addis Emmet.

I especially desire to call attention to subcutaneous laceration in the median line when it involves the fascia and transversus perinæi muscle alone. Laceration of the sphincter ani subcutaneously is so rare that it may be omitted from the present consideration. The first stage in this operation is to make the incomplete laceration complete by dividing the integument from the posterior commissure down to the upper border of the sphincter ani, and any loose cellular tissue which may exist between the integument and the vaginal wall. If the termination of the vaginal wall is drawn downwards towards the sphincter and there is prolapsus of the posterior vaginal wall, giving the conditions seen in figure III, the vaginal wall is liberated below and separated from the cellular so that it can be raised up to the posterior commissure. Any thickened cellular tissue or exudate that is found in the wound is carefully trimmed out until the fascia and muscle on either side are reached. Quite often it is necessary to trim off some of the superfluous integument which has been produced by stretching. The wound is then closed in the same way as a recent laceration is sutured, excepting that the vaginal wall is caught in the upper sutures and united thereby to the pelvic floor as heretofore mentioned. This injury is the only one in which any kind of "flap-splitting" seems to be indicated or could possibly be of the slightest use in overcoming the injury.

Treatment of the Transverse or Internal Lacerations.

Dr. Emmet was the first surgeon to devise an operation for the relief of this injury. I had for long observed and comprehended the

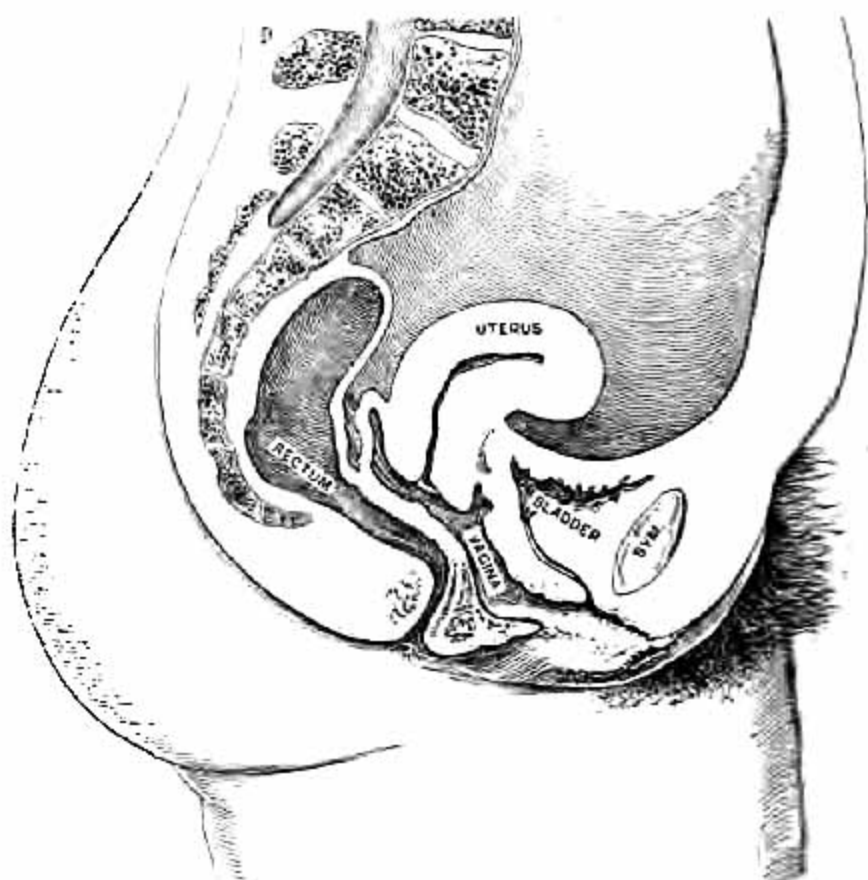


FIG. VI.

transverse or internal injury but never conceived of any method of remedying it until I heard from Emmet. It is true that by supporting the pelvic floor during convalescence from confinement, in cases in which this injury had occurred, some effort to repair the injury by natural healing processes was made, and quite successfully in some, but when the injury persisted and the usual pathological changes developed in consequence of this injury, no operation that I had ever tried was really of any service in restoring the structures. As soon as Dr. Emmet gave to the profession his discoveries in this department I saw the great importance of his valuable contribution to this branch of pelvic surgery, and I began at once to practice the operation as best I could. I have found that it meets every indication most fully in cases of transverse internal laceration in which the pelvic floor itself is in perfect condition. The operation is not adequate when the pelvic floor has sustained a subcutaneous laceration, or when atrophy has occurred in the median line from stretching, a common complication of the transverse laceration if permitted to exist for any great length of time. In these conditions I found it necessary to modify Dr. Emmet's method of operating in order to obtain the results required. Moreover, I have obtained better results by treating the so-called rectocele somewhat differently from the way in which it is treated by Dr. Emmet.

Taking it for granted that all are familiar with Dr. Emmet's operation I need only state wherein I have presumed to deviate in some particulars from his methods. In Emmet's operation we are directed to vivify the tissues up to the most prominent part of the rectocele, and then continue the vivifying upwards in the vagina on either side beyond the uppermost portion of the rectocele. No tissue is removed in the median line from the posterior commissure down towards the anus. So far as the lateral denudation in the vagina and suturing are concerned I follow the classical method. In the median line I remove only tissue enough to liberate the vaginal wall from the pelvic floor and then reflect it upwards and backwards. I then divide the tissues in the median line down to the sphincter ani muscle, or down to where I find muscular tissue and fascia; in other words, produce by incision a complete median laceration. The angles in the vagina are then brought together by the sutures down to the muscular tissue of the pelvic floor, that is, down to the bulbo-cavernosus and the ends of the transversus muscle on either side. The muscle, fascia and integument are then closed by sutures from below upwards; the enlarged vessels and cellular tissue are then crowded backwards towards the rectum

and the vaginal wall united to the floor of the pelvis with the sutures, which bring together the lateral edges of the pelvic floor.

Figure IV shows the conditions before denudation.

Figure V after denudation.

By this procedure the muscles and fascia in the median line are restored; the muscular wall of the vagina is attached to the pelvic floor as far back as the rectum and upwards to the posterior commissure. By this method the so-called rectocele is completely disposed of and the posterior wall is held downwards and backwards in its normal position; in other words, made to resume its normal relations to the pelvic floor. (See figure V).

In this way the essential requisites are obtained: first, the central part of the floor is restored; the so-called rectocele is disposed of without loss of vaginal tissue; the normal relations of the vagina and pelvic floor are established, and the overdistended veins receive more support than can be offered by any other operation known to me. The veins should not be wounded if this can possibly be avoided, either while vivifying the tissues or introducing sutures. If by chance a vein is wounded it should be excised, or the opening closed with a ligature. This guards the patient from phlebitis and extravasation. The veins can usually be avoided while suturing by separating them from the vaginal wall and pressing them downwards and backwards while passing the needle. In regard to the arteries which usually lie just beneath the vaginal wall, no harm comes from dividing them if they are ligated; in fact the closure of the arteries may be beneficial in lessening the blood supply during convalescence, thereby allowing the veins to regain their original calibre.

In regard to the treatment of prolapsus of the bladder and vaginal walls caused by injuries of the pelvic floor, especially in cases of long standing, it appears that colporrhaphy on the vagina for the purpose of correcting such lesion is as a rule unsatisfactory, as it favors the progress of atrophy and recurrence of the prolapsus. My attention was first called to this at a time when I did a large number of those operations, adopting in order the operations of Sims, Emmet, Martin of London, and Noeggerath. In watching the after-results in many of those cases I have found that atrophy of the vagina progressed with unusual rapidity and the prolapsus returned.

I believe that colporrhaphy is seldom resorted to at the present time, though it was quite in vogue a few years ago. Such treatment is unsatisfactory, excepting occasionally where in addition to the colpor-

rhaphy the injuries of the pelvic floor have been cured. In such cases the restoration of the perinæum would have accomplished the same object as well without as with the operation upon the vagina. This statement is not wholly based upon my own experience. Imperfect operating might be assigned as the cause of failure in my practice, but I have had an opportunity of examining a large number of patients operated upon by the highest surgical authorities of the age, and have found some failures among them also. At first, or immediately after operation, the success appears to be perfect, but as the atrophic changes go on in the vagina the scar tissue almost invariably gives way and the cystocele and prolapsus of the vaginal walls recur.

It is now several years that I have endeavored to relieve prolapsus of the bladder and urethra by operating to reunite the severed muscle fibres and fascia to the subpubic ligament. This principle upon which the operation is based is the same as in Dr. Emmet's operation for internal lacerations, especially related to the posterior vaginal wall, and I find that the same principle can be applied in operating for the relief of prolapsus of the anterior vaginal wall and cystocele.