

BULLETIN

OF

THE JOHNS HOPKINS HOSPITAL.

Vol. VII.—Nos. 59-60.]

BALTIMORE, FEBRUARY-MARCH, 1896.

[Price, 15 Cents.

CONTENTS.

	PAGE.		PAGE.
Hysteromyomectomy and Hystero-Salpingo-Öophorectomy by Continuous Incision from left to right or from right to left. By HOWARD A. KELLY, M. D.,	27	The Sterilization of Catgut by Cumol. By J. G. CLARK, M. D., and G. B. MILLER, M. D.,	46
The Treatment of large Vesico-vaginal Fistulæ. By HOWARD A. KELLY, M. D.,	29	Proceedings of Societies:	
Nephro-ureterectomy—Extirpation of the Kidney and Ureter simultaneously. By HOWARD A. KELLY, M. D.,	31	Hospital Medical Society, - - - - -	48
Ten Cases of Cancer of the Uterus operated upon by a more radical Method of performing Hysterectomy. By J. G. CLARK, M. D.,	37	The Treatment of Pyo-ureteritis and Pyo-nephrosis by Ureteral and Renal Catheters [Dr. KELLY].	
Sub-acute and Chronic Cystitis treated by the Vesical Balloon. By J. G. CLARK, M. D.,	44	Hospital Historical Club, - - - - -	50
		Women in Medicine [Dr. KELLY].	
		Notes on New Books, - - - - -	52
		Books Received, - - - - -	55

HYSTEROMYOMECTOMY AND HYSTERO-SALPINGO-ÖOPHORECTOMY BY CONTINUOUS INCISION FROM LEFT TO RIGHT OR FROM RIGHT TO LEFT.*

BY HOWARD A. KELLY, M. D., *Professor of Gynecology in the Johns Hopkins University.*

The field for exsective operations is growing daily more limited, and my sympathy with this conservative movement in gynecology is so strong that I am unwilling even to speak of the more radical methods to be dealt with in this paper without emphasizing the necessity of limiting them to extreme cases. I will therefore briefly review the recent conservative advances made before describing the radical plan of operating.

Radical extirpative procedures will be avoided in a large number of myomatous uteri if the surgeon will carefully study out the relations of the body of the uterus and of the uterine cavity to the tumors; he will then often find that the tumors are so disposed that he may enucleate them by one or more incisions, and save the uterine body intact. This may even be done with interstitial tumors as big as a man's head, and where the fundus is raised in the abdomen as high as the umbilicus. I have in one case taken out seven tumors by as many separate incisions. Cases so treated may be looked upon from a practical surgical standpoint as closely analogous to the long uterine wound closed in a Caesarean section.

* An address before Southern Surgical and Gynecological Association, Washington, D. C., November 12, 1895.

The radical method will again be avoided in a large number of the worst forms of inflammatory cases, those in which pus has formed, by my method of free incision in the vaginal fornix behind the cervix, followed by free drainage, without the removal of any organ. An abdominal incision may be required to guide the vaginal hand in breaking up all the pus pockets.

Hydrosalpinx and adherent tubes and ovaries may be treated by breaking up the adhesions, and by splitting open the dorsum of the tube, and dilating its lumen. In such bad inflammatory cases the operator should let the patient definitely understand that she takes some chances as to recovery under this plan of treatment, and may later have to submit after all to the radical operation.

The field left for the extirpation of uterus, tubes and ovaries, after making these important exceptions, is greatly limited. It includes hysteromyomectomy for uteri distorted by myomata, or enormous myomatous masses, where the question of conservation is as yet in abeyance. It also includes hystero-salpingo-öophorectomy for cancer affecting both ovaries, and ovarian cystomata affecting both sides, and old inflammatory cases in which tubes and ovaries are bound down in such dense adhesions that rejuvenation is impossible.

With these definitions I will now describe an operation which I practise at the Johns Hopkins Hospital, and which I have demonstrated in upwards of two hundred cases within the past two years. Visitors from the American Medical Association may remember some of my cases, operated on in the Hospital Amphitheatre, in May, 1895.

The great value of this operation is its rapidity, saving from 60 to 80 per cent. of the time consumed in the enucleation, and the method of dealing with certain serious complications.

The operation consists in the following steps:

1. Opening the abdomen.
2. Ligation of the ovarian vessels near the pelvic brim, either on the right or on the left side, clamping them towards the uterus, and cutting between.
3. Ligating the round ligament of the same side near the uterus, cutting it free, and connecting the two incisions, in order to open up the top of the broad ligament.
4. Incision through the vesico-uterine peritoneum from the severed round ligament across to its fellow, freeing the bladder, which is now pushed down with a sponge, so as to expose the supravaginal cervix.
5. Pulling the body of the uterus to the opposite side to expose the uterine artery low down on the side opened up. The vaginal portion of the cervix is located with thumb and forefinger, and the uterine artery, seen or felt, is tied just where it leaves the uterus. It is not always necessary to tie the veins.
6. The cervix is now cut completely across just above the vaginal vault, severing the body of the uterus from the cervical stump, which is left below to close the vault.
7. As the last fibres of the cervix are severed or pulled apart, while the body of the uterus is being drawn up and rolled out in the opposite direction, the other uterine artery comes into view and is caught with artery forceps about an inch above the cervical stump.
8. Rolling the uterine body still farther out, the right round ligament is clamped, and cut off, and lastly the ovarian vessels are clamped at the pelvic brim, and the removal of the whole mass, consisting of uterus, tubes and ovaries, is completed.
9. Ligatures are now applied in place of the forceps holding the uterine artery, round ligament, and ovarian vessels; if the surgeon prefers, these may be tied as they are exposed without using forceps.
10. After the enucleation the operation is now finished in the usual way, *a*) by closing the cervical tissue over the cervical canal, and then, *b*) by drawing the peritoneum of the anterior part of the pelvis (vesical peritoneum and anterior layers of broad ligaments) over the entire wound area, and attaching it to the posterior peritoneum by a continuous catgut suture.

The continuous transverse incision should always be started on the side where the ovarian vessels and the ovary and tube are most accessible. If the case is one of a fibroid uterus, and the tumors are developed under the pelvic peritoneum or in the broad ligament of one side, this side should be opened up last, from below upwards, when the tumors can be rolled up and out with surprising facility.

Displaced ureters will not be injured, for on the side on which the enucleation is started such a ureter is pushed down with the loose peritoneum as the uterus and tumors are pulled up and towards the opposite side; and on the other side, no matter how much the ureter is displaced out of the pelvis, as the tumors caught from below are rolled up and out, the ureter drops down with the peritoneum and cellular tissue to the pelvic floor, and the operator need not even see it or be aware of its displacement, to avoid the risk of injuring it.

If the ureter is found to be displaced only on one side, the operation should begin on the opposite side.

To escape the danger of tying the ureter on the side on which the uterine artery is caught after dividing the cervix, I am careful to put the forceps on the artery well above the cervical stump and to tie there.

The abdominal incision is always closed without drainage, by using a continuous catgut suture for the peritoneum, interrupted silver wire sutures for the fascia, a buried continuous catgut suture for the subcutaneous fat, and the subcuticular catgut suture for the skin.

The important points accomplished by this method of operating are *a*) the great saving of time, and *b*) the simple way in which certain serious complications are met.

a) Time saved.—According to other methods of operating, half an hour or an hour, or even more, may be consumed in enucleating the tumors and in getting ready to close up the pelvic and abdominal wounds, while by this method the enucleation is often effected in three or four minutes, and in difficult cases in from ten to fifteen minutes.

The experience of every surgeon will bear me out in insisting upon the importance of saving time at this particular stage of the operation, that is, the stage of enucleation, which is most likely, when prolonged, to produce shock, and to be accompanied by excessive loss of blood.

Furthermore, when the enucleation of the disease is completed, all important questions affecting the vital interests of the patient have been answered; adhesions have been severed, important vessels controlled, intestinal complications dealt with, and tumors developed in situations difficult of access have been removed. In other words, those factors in the case which often demand an alert judgment and the highest surgical skill have all been dealt with; the rest of the operation, closing the pelvic wound and the abdominal incision, follows a certain routine which may with safety be left in the hands of a well trained assistant.

b) Complications met.—I have insisted particularly upon the novel way in which serious complications are simplified by this plan of treatment, and I would refer chiefly to two kinds of complications:

First, fibroid tumors located under the peritoneum of the pelvic floor, and

Second, inflammatory masses situated behind the broad ligaments, with dense adhesions to the pelvic peritoneum, to the rectum, and often to the small intestines.

In the case of the sub-pelvic peritoneal fibroids, it is astonishing how difficult they are to get at from above, and how easily on the other hand they roll out when handled from beneath by this procedure.

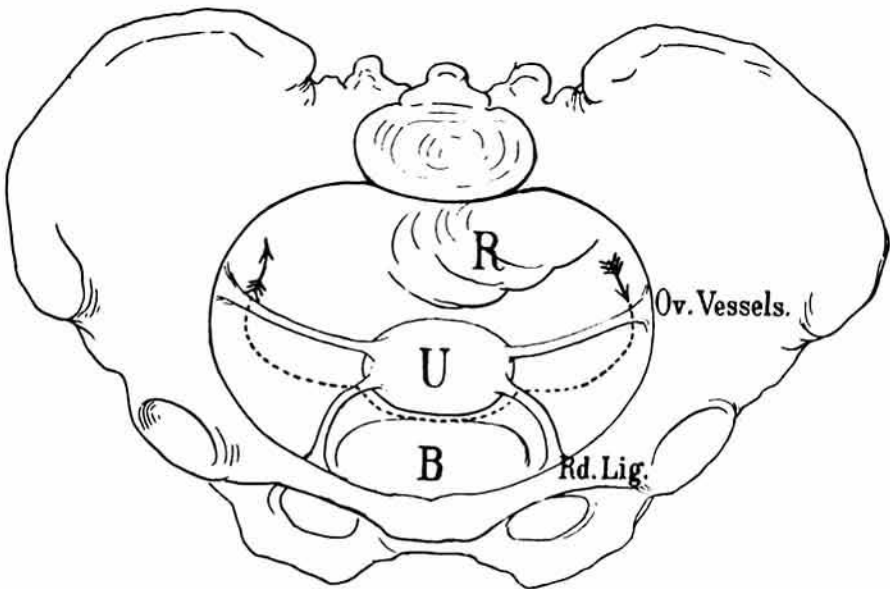


FIG. 1.

Showing line of incision through peritoneum from left to right, through left broad ligament, round ligament, utero-vesical peritoneum, right round ligament, and ending with right broad ligament near the pelvic brim.

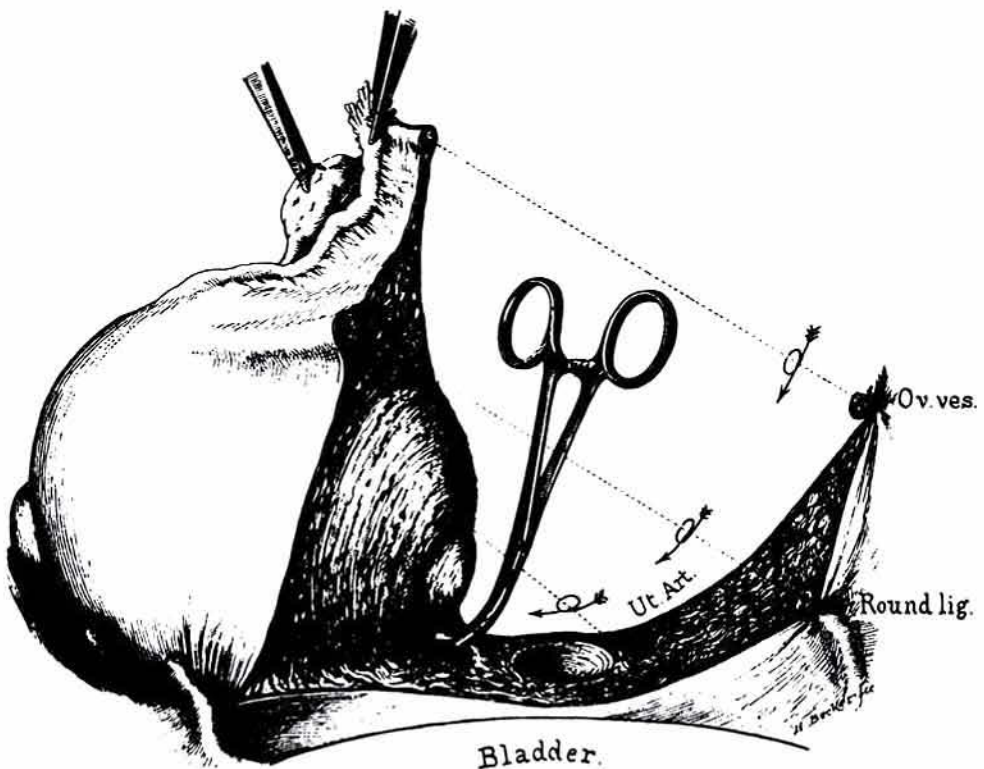


FIG. 2.

Left ovarian vessels tied, left round ligament tied, vesical peritoneum divided and pushed down and left uterine vessels ligated. Cervix amputated and uterus pulled up and out, exposing right uterine artery, which is clamped an inch above the cervical stump. The two following steps are clamping the right round ligament and right ovarian vessels, when the mass is removed.



HYSTERECTOMY SPUD. Used instead of a knife for amputating the uterus at the cervix. The curved blade enables the operator to work easily in a deep pelvis cupping out the stump.

I would say the same of the inflammatory cases. Matted masses adherent in all directions which resist enucleation from above are often removed with ease when rolled up from the pelvic floor from below. The adherent structures seem to be unrolled in a natural and easy way, in surprising contrast to the difficulties experienced, and the injuries inflicted, in gaining the slightest finger-hold in proceeding from above.

To recapitulate: Abdominal hysterectomy by the continuous incision down through one broad ligament across cervix and up through the other broad ligament, is contrasted with hysterectomy by an incision down to the cervix through one broad ligament, and then down through the other, followed by amputation of the cervix.

The special advantages offered by this method of operating are:

1. The saving of from 60 to 80 per cent. of the time in the enucleating stage of operation.
2. The ease with which intraligamentary myomata and myomata beneath the pelvic peritoneum may be enucleated.
3. The ease with which inflammatory masses posterior to the broad ligament may be enucleated by attacking them from below after dividing the cervix.
4. The control of a displaced ureter, on the side last opened up, keeping it out of the way of injury by the simple mechanism of the operation.