

CONGENITAL ABSENCE OF UTERUS AND VAGINA.  
PLASTIC OPERATION FOR ARTIFICIAL VAGINA, TAKING FLAPS FROM  
NYMPHÆ AND PERINEUM.

BY W. L. BURRAGE, M.D.,  
VISITING GYNECOLOGIST TO ST. ELIZABETH'S AND CARNEY HOSPITALS; SURGEON TO  
OUTPATIENTS, FREE HOSPITAL FOR WOMEN, BOSTON.

M. A., aged nineteen years and single, a native of Gloucester, Mass.,  
was sent to me by Dr. G. N. Jones, of that city, February 14, 1894.  
She gave the following history :

Her father was born in Sweden and her mother in Nova Scotia, the latter having died of cancer of the uterus six years before. With this exception the family history was negative. Of her three sisters, one was married and had a child; another, sixteen years old, had menstruated regularly for four years; and the third, then fourteen years old, had not at that time had her catamenia established, but has since menstruated regularly.

The patient had never been in rugged health. She had suffered with a purulent discharge from the left ear ever since one year of age, and she had measles and chickenpox at seven to eight years of age. She had been under medical treatment for the preceding four years for general weakness, headache, weak eyes (for which she had been wearing glasses with benefit), temporal headaches, sore-throat, loss of appetite, and shortness of breath. While under treatment she had improved, and at the time of my first consultation she had a fair appetite and digestion, and her chief complaints were a weak back and the fact that she did not menstruate. As she was engaged to be married, the last fact was of especial importance to her. There had been no menstrual molimen whatever.

Physical examination showed a well-developed, rather poorly nourished woman above the average in height, of light complexion, the hair of the head long and thick, voice feminine, breasts each having a well-developed gland with a few follicles showing in the areolæ about the inverted nipples, hips large, and pelvis of female type.

*Genital Organs.* An abundant growth of hair on the mons and the outer surface of the labia majora. Labia majora, labia minora, vestibule, and clitoris well developed. Meatus urinarius and urethra of large calibre, taking a sound fourteen millimetres in diameter without much stretching; natural diameter about eleven millimetres. Hymen absent. Where the introitus vaginæ is normally situated the mucous membrane was redundant and wrinkled, and in the centre was the opening of a small pocket four millimetres in diameter. This pocket had a depth of one and one-half centimetres, its long axis corresponding with the axis of the normal vagina, and it was apparently lined with mucous membrane. A small amount of milky-white secretion could be expressed from it. Orifices of vulvo-vaginal glands large and normally placed. In other words, with the single exception that the introitus vaginæ and hymen were absent, the external genitals were normal.

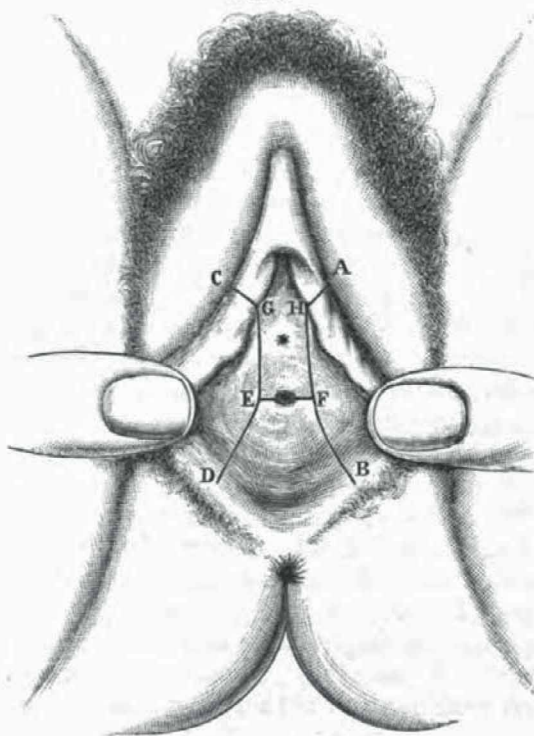
As a bimanual examination with a finger in the rectum failed to reveal the presence of the uterus or other internal organs of generation the patient was sent to St. Elizabeth's Hospital, where an ether examination was made on the following day. Two of my colleagues on the gynecological staff of the hospital kindly saw the case with me. We all examined bimanually with the forefinger in the rectum, also with the little finger in the bladder. Then with a sound in the bladder and a finger in the rectum and with the sound in the bladder and a hand on the abdomen. The abdominal walls were thin and lax, and the intestines undistended, and, the rectum and bladder being empty, all the conditions for practising the touch were most favorable. No uterus, ovaries, or tubes, or any thickened tissues that might represent any of these organs, or the occluded vagina, were to be felt in the pelvis. The bladder and rectum seemed to be of normal size, shape, and situation. The septum between the bladder and rectum was thin.

The patient was advised to consult an aurist for treatment of the chronic inflammation of her ear, and also to see the ophthalmologist again. The condition of her genital organs was explained to her and to her married sister, and they were advised to inform her *fiancé*. She was told that if she wished to undergo an operation that possibly a serviceable vagina could be made.

After giving the matter careful consideration she decided to have the operation performed, and accordingly entered the hospital for that purpose.

*Operation, March 28, 1894.* The object of the operation was to separate the bladder from the rectum by incising the cellular tissue between these organs, and then to cover the raw surfaces forming the walls of the cavity so made with mucous membrane or skin, utilizing three flaps; one taken from the fourchette and perineum and one from each of the labia minora.

FIG. 1.



AHF and CGE. Lines of incision for flaps from labia minora.  
ED and FB. Lines of incision for perineal flaps.  
EF. Line of incision for excavation for new vagina.

After ether had been administered and the usual antiseptic precautions observed, the vulvar hair was shaved and the rectum thoroughly irrigated with corrosive. An attempt has been made in Fig. 1 to show the relation of the parts. The orifice of the rudimentary vagina is shown on line EF. An incision was made along this line and prolonged at each end so that it measured about three centimetres in length, splitting the rudimentary vagina into halves. With a finger in the rectum and a sound in the urethra for guides, the recto-urethral septum was split by dissecting with the scissors and finger for a distance of five

centimetres. At that point the finger in the wound was apparently separated from the intestines by a sheet of peritoneum only, and, practising the bimanual touch again, it was impossible to discover the presence of any tissue that might represent the uterus, ovaries, or tubes.

In order to cover the raw surfaces formed by the dissection, flaps were formed as follows: the nymphæ were cut off at AH and CG, and then incisions through the mucous membrane made along the lines HFB and GED. The two lateral flaps formed in this way were dissected free, and by so doing the nymphæ were split from their posterior aspect and unfolded, as it were.

The posterior flap, represented by the surface enclosed in the letters DEFB, was formed by dissecting deeply the tissues of the fourchette and perineum, so that this flap could be dragged upward and inward to cover the posterior surface of the new vagina. The strip of mucous membrane on this posterior wall that had been half of the rudimentary vagina was dissected away, and the posterior flap anchored by suturing its tip at the uppermost part of the new vagina with a catgut stitch. In the same manner the two lateral flaps were disposed of by stitching their tips at the apex of the vagina. The little strip of mucous membrane on the anterior wall from the rudimentary vagina was utilized by stitching the lateral flaps to its edges. The operation was completed by sewing together the edges of the mucous membrane at the stumps of the nymphæ and at the places where the three flaps came into apposition with fine interrupted sutures of catgut.

At the close of the operation there was a small raw surface, about one centimetre in diameter, at the highest part of the wound, that it was impossible to cover. The vagina was packed lightly with iodoform-gauze and the patient put to bed.

The after-treatment consisted in keeping the vagina packed with iodoform-gauze. The left flap broke loose on the third day, but by carefully applied pressure it glued on again. A glass-tube that was introduced as a dilator was not well tolerated, so the house-surgeon manufactured a dilator out of a rubber finger-cot stuffed with cotton. This was worn constantly, being kept in place by a T-bandage. On May 1st the vagina measured two and one-half centimetres in diameter and four and one-half centimetres in depth. The patient left the hospital on May 3d, with instructions to wear the dilator for a month.

She was not seen again until two years later, February 29, 1896, when she appeared at my office with her husband. She reported that she had gained very much in health and had been perfectly well, with the exception of weakness of the back after exertion and of a recent attack of indigestion; that she had then been married two months and a half; that she had had sexual intercourse regularly since marriage, and that the intercourse was attended by sexual feelings and gratification. Her husband also said that, for his part, coition had been entirely satisfactory.

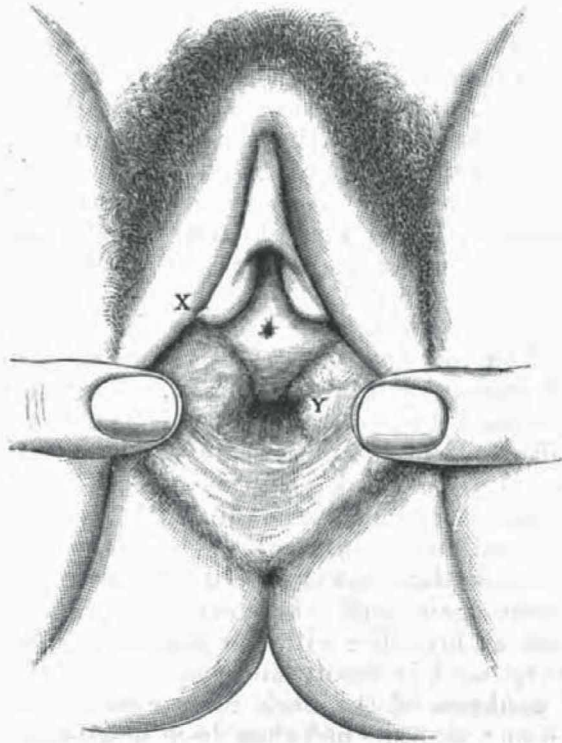
She now called my attention for the first time to a bunch in the right side of her abdomen, which she had first noticed, she said, several years ago—in fact, before the operation; but, as it had never given her any discomfort, she had not spoken of its presence. It had moved lower down in the abdomen since the operation, and since her marriage had increased in size. Examination showed a tumor the size and shape of a large kidney situated in the false pelvis on the right side, the hilus



being toward the vertebral column. Its upper border, with the patient on her back, was on a line drawn from the umbilicus to the right anterior superior spine of the ilium. It slipped from under the hand in the manner characteristic of movable kidney, its mobility being limited above just beyond the level of the umbilicus, on the left at the median line, and below at Poupart's ligament. Pressure on the tumor caused "a sickening sensation." Palpation in the right flank failed to detect the presence of the kidney in its normal situation. The urine was normal. It had been increased in amount, of late, she said. There had been no pain or dragging sensation in the region of the tumor.

The tumor was surely not in its present situation at the time of the ether examination two years before, or it would have been felt at once by the examining hand on the abdomen. Bimanual examination with a finger in the vagina and with a finger in the rectum showed that the tumor had no pelvic connections that could be felt, and confirmed the previous diagnosis of absence of the uterus.

FIG. 2.



X. Stump of right labium minus.

Y. Wrinkled and brown mucous membrane to the left of introitus vaginae.

The patient's general appearance bore out her statement regarding her health, for she had apparently gained in flesh and certainly looked the picture of health. Fig. 2 is a representation of the external genitals at this time. The letter X is on the stump of the left nympha, and Y is placed just to the left of the opening of the vagina. About the opening there were several areas of pigmented mucous membrane, or more properly skin, as representing the outer surface of the nymphæ. The vagina measured three centimetres in diameter when dilated and

five and one-half centimetres in depth. It was distensible, not sensitive, well lubricated, and when examined with the speculum appeared to be lined throughout with mucous membrane.

December 9, 1896, the patient wrote that she had adopted a four months old baby, and was very happy in its care.

The first operations for the formation of an artificial vagina were done by R. Fletcher in 1831<sup>1</sup> and Amussat in 1832,<sup>2</sup> and were performed for the purpose of allowing the escape of retained menses. The operations were blunt dissections in the recto-vesical septum, were performed in many stages lasting several days, and had for their object gradual drainage through a small opening. Emmet perfected the present accepted operation of rapid evacuation of the retained fluid by a dissection of the tissues between the bladder and rectum, making a free opening and then packing the wound with gauze or a glass-plug and allowing it to cicatrize. The manifest disadvantage of such an operation is that in the course of time the newly formed vagina becomes entirely occluded by cicatrization. That this is a fact is abundantly shown by the large number of reported cases.

Credé, in 1883,<sup>3</sup> formed a new vagina by using one large skin-flap from one of the labia majora. Baudry<sup>4</sup> followed Credé's method, but obtained a poor result due to sloughing of the flap. L. Picqué<sup>5</sup> created a new vagina in a case of infantile uterus and absent vagina by taking flaps from the anterior wall of the vestibule and from the perineum. He obtained a vagina five centimetres long two months after the operation. He later reported a similar case done by Villar, of Bordeaux. Von Swiecicki<sup>6</sup> reports a case of absence of the vagina resulting from gangrene following labor in which he performed a successful plastic operation by using rabbit's intestine. Kustner<sup>29</sup> proposed to divide the labia minora at their inner surfaces, unfold them as in my case by dissection, unite their edges, and push the bag so formed into the excavation for the vagina. Finding this procedure impracticable, he used grafts of human intestinal mucous membrane obtained from a recent case of intestinal resection for perforating wound of the abdomen, and obtained a good result.

Mackenrodt<sup>30</sup> has recently made use of grafts of vaginal mucous membrane obtained from a case of prolapse to cover the raw surfaces of an excavation for a new vagina.

Schwartz<sup>28</sup> made a vagina by the use of four strips of mucous membrane, two lateral, one anterior, and one posterior. He got union by first intention, and eighteen months after there was a cavity five centimetres deep.

The only other cases of plastic operation for artificial vagina that I have found in literature are one by Rosciszewski, and published in Krakow in 1894; the title is "Plastic Vagina by Means of Flaps of

the Labium Prudendi, in Stenosis of the Vagina ;" and lastly, operations very like mine, by Christian Fenger, of Chicago, in 1886,<sup>6</sup> and Roux<sup>22</sup> in 1891.

In Fenger's case the patient had been operated on a year previously by Byford, for retained menses, but the vagina having cicatrized she had a return of her symptoms. Fenger made two preliminary operations two weeks apart to dilate and keep open the vagina with a plug, and two and one-half months later he performed the plastic operation. The portions of the labia minora used measured each one square inch. The labia were cut off from above and the flaps twisted on their bases as well as being split and unfolded, as in my case. He found it unnecessary to take a flap from the perineum. The subsequent course was uninterruptedly aseptic, and the result was a vagina lined throughout with mucous membrane of some secretory power. Roux used two flaps taken from the nymphæ, unfolding them and stitching them in the excavation, and got a good vagina six to seven centimetres deep.

The advantages of a plastic operation for artificial vagina over the plug operation are obvious both in cases of congenital and acquired absence of the vagina. Where the labia minora are of sufficient size they seem to me to offer the most available means of covering the walls of a new vagina, as entailing less mutilation than would be the case with flaps taken from the labia majora or vestibule, and I should agree with Fenger that a bilateral operation is preferable to a unilateral one.

In considering the question of absence of the uterus it may be stated at the outset, without fear of contradiction, that complete absence of the uterus has been demonstrated by anatomical proof only in cases of acephalic monsters or fœtuses with spina bifida or other malformations incompatible with prolonged life. In all other cases a small bit of tissue, a knob of muscle or band of connective tissue, if nothing more, as representing rudiments of the uterus, has been shown to exist on the cadaver.

From a clinical point of view, a woman possessing such rudiments is as badly off as if she had no uterus at all. I maintain that a small piece of muscle without the shape of a uterus, or a band of connective tissue across the pelvis, cannot be called a uterus either in an anatomical or physiological sense, and such a state of affairs is of interest only from the standpoint of embryology ; therefore we are justified in speaking of women possessing such rudimentary structures as cases of absence of the uterus. The case just reported is an example of a not very rare class—*i. e.*, normal feminine habitus, well-formed hips, breasts, and external genitals, hair of the head long, normal pubic and axillary hair, and feminine voice, with absence of the uterus and more or less atresia of the vagina. These individuals are usually healthy unless the ovaries

are present and functionally active, in which case they suffer from menstrual pains, sometimes so severe as to necessitate oöphorectomy.

Absence of the uterus was first noted by the anatomist Realdus Columbus, in 1572.<sup>1</sup> According to Kussmaul, his observation was defective, and the complete absence of the uterus was not satisfactorily demonstrated. In the succeeding two hundred years the only observations on this subject were made by Morgagni, Morand, and Seron, and they were incomplete. In 1777 William Hill, of Hillsborough,<sup>2</sup> reported an incomplete case of absence of the uterus. He made an autopsy on a woman forty years old who had neither uterus, ovaries, tubes, broad ligaments, nor vagina, but in their place a "cylinder" three inches long and one inch thick. In 1781 Engel<sup>3</sup> published a dissertation on the total or partial absence of the uterus. He first called attention to the rectal touch and catheterism of the bladder as a means of diagnosis, besides studying the anatomy of the subject.

From the beginning of the nineteenth century the reports of cases of absence of the uterus were published with increasing frequency and with greater accuracy of observation. Kussmaul, of Heidelberg, was among the first to publish an extended treatise on the subject and to attempt to explain such anomalies from the standpoint of arrest of development. This treatise, <sup>10</sup>published in 1859, is today the standard work on the subject. Kussmaul investigated the question from an anatomical and embryological point of view, and concluded that absence of the uterus could not be demonstrated with surety on the living woman and that most of the reported cases were really cases of rudimentary uterus; that pathologically there was always some rudimentary tissue to represent the uterus. Many cases of absence of the uterus have been reported in medical literature since Kussmaul's time. The names of Le Fort,<sup>11</sup> who introduced Kussmaul's ideas into France, and L. Fürst,<sup>12</sup> who contributed much to the exact understanding of the embryonic period which corresponded to each of the anomalies, should be especially mentioned in this connection. One of the most recent and complete epitomes of the subject is the graduation thesis of Francis Rossignol,<sup>13</sup> published in 1890.

To get some idea of the frequency of this anomaly I have made a careful study of the literature, using the *Index Medicus*, the Gynecological Index in the early numbers of the American Gynecological Society's *Transactions*, and the *Index Catalogue* of the Surgeon-General's office.

Without aiming at absolute completeness, owing to the inaccessibility of some of the sources of information, I have been able to collect the references to 360 cases of absence of the uterus reported by 239 authors from earliest times up to the present. Roughly, we may say about 300 cases in the last century. Cases occur in the literature of all civilized



countries. I have examined a majority of the 239 references, and have found among them the records of only thirty-five autopsies where this condition was present. Of these, twenty-four were on the bodies of adults and two on girls ten and twelve years old respectively, the rest being on monstrosities and fetuses with absence of other organs, making prolonged life impossible. In all of the autopsies on the bodies of adults and girls there were noted in every case rudimentary tissues representing the uterus, generally one or two little knobs of tissue the size of hazelnuts or a thin band between the bladder and the rectum.

The ovaries were found to be present in all the cases but six, and five of these were reported in general terms without details, such as "Internal organs of generation wanting." The six cases referred to as having no ovaries were: 1. Case of William Hill, of Hillsborough,<sup>14</sup> already cited. 2. Busch<sup>15</sup> reported a case which Kussmaul thought might be an hermaphrodite. The statement was made that at the autopsy vagina, tubes, uterus, and ovaries were completely wanting. The patient was eighteen years old. 3. Otto<sup>16</sup> reported an autopsy on a twelve-year-old girl who died of a "blue sickness" as the result of grave cardiac malformations. The external genitals were normal, the vagina was very short and terminated in a cul-de-sac, and the internal genital organs were totally wanting. 4. Mary Putnam Jacobi<sup>17</sup> cites a case reported by Hanff where he performed an autopsy on a woman aged fifty-one years who had died of smallpox. The ovaries and tubes were entirely wanting and the uterus was rudimentary. The external genitals were small and undeveloped, like those of a ten-year-old girl. Sometimes the ovaries were found atrophied and sometimes misplaced, but always present except in the foregoing instances. 5 and 6. Lieutaud and Richerand<sup>17</sup> dissected subjects in whom neither the uterus nor its annexed organs were found.

The tubes were present in all cases except six, though often without any canal. The six cases were those of Otto, Busch, and Hanff, and one reported by Boyd.<sup>18</sup> He records the result of an autopsy on an inmate of a workhouse, aged seventy-two years. There was malposition of the kidneys, and the tubes and uterus were wanting, the vagina being represented by a cul-de-sac half an inch deep. The right ovary was normal and the left converted into a fibrous mass. The external genital organs were normal. Also cases reported by Blasius<sup>25</sup> and Blot.<sup>26</sup>

A very large proportion of the reports I have examined are of cases similar to mine—*i. e.*, adult women, feminine habitus, normal external genitals and breasts. A very few cases having abnormal external genitals and the male type of breast, with absence of pubic hair, are reported. The vagina was generally present as a short pouch, though often entirely wanting. Absence of the vagina alone, the uterus being present, is a much more common anomaly than absence of the uterus.

The literature is teeming with published cases of retained menses both from absent vagina and from imperforation of the lower part of the vagina, commonly spoken of as imperforate hymen. So, also, the other developmental defects—double vagina, double uterus, and bicorned uterus—are more common.

In a considerable number of the cases of absent uterus and vagina the urethra has been found to be of large calibre, and in several cases coitus has been practised through it, often without the knowledge of the patient that anything was wrong in this respect. Emmet's case<sup>19</sup> of this sort was one of the earliest and most widely quoted. Most writers hold that the large calibre of the urethra in these cases is due to attempts at coitus, but in view of the fact that there are on record many cases of absence of the vagina in unmarried women of good character where the urethra has been found large—*e. g.*, my case above reported—it seems that the explanation is to be sought rather in some developmental defect. Mary Putnam Jacobi<sup>20</sup> thinks that the large size of the canal extending from the bladder to the vestibule is due to the fact that it is constituted by a persistent embryonic organ, the urogenital sinus, and is not simply the urethra.

The anomaly of absence of the uterus is due to a lack of fusion and subsequent atrophy of the ducts of Müller, a process which ordinarily takes place at the end of the third month of foetal life. It is well established that these ducts, under normal conditions, fuse in their middle and lower course, the process proceeding from above downward to form the uterus and vagina, whereas above the separate non-fused ducts form the Fallopian tubes. The external genitals, the lower part of the vagina, as well as the urethra and vesical trigone, on the other hand, are formed from the urogenital sinus, and the genital tubercle, furrow, and fold. It is therefore plain why the external genitals are so often found in a normal condition in the same individual in whom the internal organs are wanting or rudimentary, since they are formed from a different set of embryonic tissues. We see also why the vagina is apt to be wanting when the uterus is wanting. A partial coalescence of the Müllerian ducts accounts for the reported cases of double vagina and double and bicorned uterus. The ovaries are in close relation to the kidneys in foetal life, the kidney being situated much lower down than in the adult. Cases are on record where the ovaries have been found malposed and in their foetal relation. I have found a considerable number of recorded cases where absence of the uterus was associated with misplaced kidneys. Werth has also noted this association of the two conditions.

The derivation of the hymen is still in dispute. It was formerly held to be formed from the lower end of the vagina, but the many cases of absence of the uterus and vagina where a well-formed hymen exists

would seem to disprove this view. So, also, the absence of smooth muscular fibres in the hymen would tend to show its anatomical dissimilarity to the vagina. Pozzi<sup>21</sup> holds that the hymen is developed entirely distinct from the vagina and is derived from the urogenital sinus. He accounts for the prolongation of the rugæ and pillars of the vagina on to its posterior aspect as a later developmental change. He thinks that complete atresia of the hymen is generally due to a terminal imperforation of the vagina. It is known that the hymen develops late in foetal life, the nineteenth week, and there seems every reason to believe that it is formed from the same embryonic structure as the vestibular vagina—*i. e.*, the urogenital sinus. Therefore, we should not expect to determine whether it would be likely to be present in any given case of absence of the vagina. As a matter of fact, it is reported as present in a majority of cases, as is also some sort of a vaginal canal. This canal must be thought of as a persistent urogenital sinus rather than a Müllerian vagina, because in the process of development the Müllerian ducts coalesce from above downward. The urogenital sinus develops from below—the urethra and rectum being set off from the vagina—and it is not difficult to understand how, in one case, the lower vagina fails to develop, giving rise to hæmatocolpus if the uterus is functionally active, or, in another case, the uterus and Müllerian vagina being absent, that the urogenital sinus forms a urethra of large calibre and a hymen.

It would seem as if inheritance had something to do with absence of the uterus. Squarey<sup>22</sup> reported the cases of three sisters who had never menstruated, three of whose aunts were sterile. Phillips<sup>23</sup> speaks of two sisters, both married, with congenital absence of the uterus. Nelson<sup>24</sup> reported absence of the uterus in three of a family of five sisters. All three had sexual desires. Of the two sisters with uteri, one had a family of four children, the other was seventeen years old and unmarried. Sexual appetite was present in most of the cases reported. Menstrual molimina sometimes and sometimes not, but generally present where the ovaries could be diagnosed.

It is seldom that a proper diagnosis can be made without an anæsthetic. The thinness and condition of laxity of the abdominal walls are important factors in determining the accuracy of the examination. In some of the reported cases the diagnosis was confirmed by operation, as in several where oöphorectomy was practised for severe menstrual pains. A diagnosis made in this way is not so likely to be accurate as one made post-mortem, when there is an abundance of time for examination. On account of the large urethra in these cases it is usually an easy matter to introduce a finger into the bladder, thus facilitating the diagnosis.

As to treatment: if there are no molimina, it is a question for the

patient to decide whether she will have an operation or not. It has been maintained by a majority of writers that it is unjustifiable to operate on the unfortunate woman who has no uterus and no vagina. Certainly in my case the patient and her husband were rendered happy by the result of an operation. If we are able to form a vagina that will not close by cicatrization, it seems to me that operation is much more justifiable than it is in cases where the only operative procedure is to make an opening and try to keep it from closing by a plug or packing.

Emmet<sup>21</sup> has reported two cases in which the patient's health became established following operation for artificial vagina, and he quotes Robert Barnes as having noted the same remarkable circumstance.

Where menstrual molimina are severe, oöphorectomy is undoubtedly indicated.

## BIBLIOGRAPHY.

1. *Lancet*, August 13, 1831.
2. *Gaz. médicale de Paris*, 1835 2 S., iii. 785.
3. *Archiv für Gynäkol.*, 1883, Bd. 22, H. 2, S. 229.
4. *Rev. de chirurgie*, Paris, November 10, 1889, ix. 948.
5. *Archiv de tocologie et de gynéc*, 1892, xix. 481-485.
6. *Trans. Amer. Surg. Assoc.*, 1887, v. 375-383.
7. *De re Anatomica*, Libri xv., 1572, 8, 495.
8. *Diss. de Utero deficiente*, 1777.
9. *Diss. de Utero deficiente*, Regiom., 1781.
10. *Von dem Mangel der Verkümmernng und Verdopplung der Gebärmutter*, 1859.
11. *Des Vices de Conformat. de l'Utér.*, etc., Paris. Thesis, 1863.
12. *Monatsschrift für Geburtshülfe*, xxix. and xxx. 1867.
13. *De l'Absence ou De l'état rudimentaire de l'utérus*, Paris, 1890.
14. *Loc. cit.*
15. *Rust's Magazine*, xii. 330.
16. *Seltene Beobachtungen zur Anat., Physiol. u. Patholog.*, 2 S., 1824.
17. *Amer. Journ. Obstet.*, xxii. 520.
18. *Medico-Chirurg. Trans.*, xxiv. 187; also *Lancet*, 1840-1841, 884.
19. *Vesico-vaginal Fistula from Parturition and Other Causes*, 229.
20. *Loc. cit.*, 512.
21. *Clinical and Operative Gynecol.*, ii. 466, 467.
22. *Obstet. Trans.*, London, xiv. 212.
23. *Amer. Med. Monthly*, 1861, xv. 426.
24. *Principles and Practice of Gynecology*, 1834, 189.
25. *Observationes Medicæ Rariores*, 1677.
26. *Compt. rend. Soc. de Biol.*, iii. 176. Paris, 1857.
27. *Dictionnaire des Sciences Médicales*.
28. *La Semaine Médicale*, 1892, 161.
29. *Verhandl. der D. Gesellsch. f. Gynäkol.*, 1893.
30. *La Semaine Médicale*, 1896, 28, 110.
31. *Bull. de la Société d'Anatomie de Bordeaux*, 1889.
32. *C. R. du Congr. franc. de Chir.*, 1891, 497.
33. *British Med. Journal*, 1870.