

INTESTINAL ANASTOMOSIS WITH SUTURING OF THE ENTIRE  
THICKNESS OF THE INTESTINAL WALL.<sup>1</sup>

METHOD AND INSTRUMENTS.

---

BY

OSCAR H. ALLIS, M.D.,  
Surgeon to the Presbyterian Hospital.

WITH ILLUSTRATIVE CASES BY  
R. P. McREYNOLDS, M.D.

---

(With eight illustrations.)

My first intestinal anastomosis was performed by means of the Murphy button. It was accomplished with so much ease that I could not restrain my feelings of complaisance that I had accomplished a great feat. Whatever be the fate of that ingenious contrivance, the world owes Dr. Murphy a grateful remembrance for the impetus he gave to a most interesting and important surgical procedure.

<sup>1</sup> Read before the Section on Gynecology, College of Physicians of Philadelphia, October 17, 1901.

My case was a gastro-enterostomy (Case 1), the button passed into the stomach, where it was found at the autopsy a year and a half after the operation.

In my second case I was unexpectedly obliged to make an end-to-end anastomosis (Case 2). I again resorted to the button, but the abnormal thickness of the intestinal walls, due to pathological conditions (see Case 2), rendered its application difficult. The immediate result was satisfactory. The movements of the bowels were for a time natural, but later on were effected at the site of the operation, and still later I cut down and removed the button, which had not moved.

Upon a subsequent trial I found the intestines greatly improved and well adapted to the "button," but this time, unfortunately, the instrument was out of order and could not be used. There was nothing left for me to do but make an approximation with

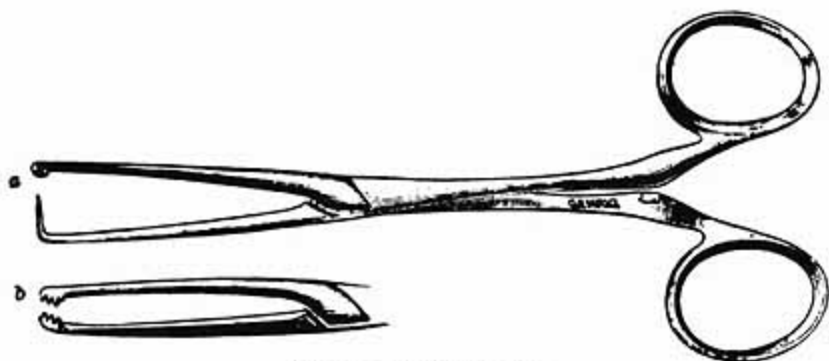


FIG. 1.—Two-thirds size.

such general instruments as were at hand, but chiefly was indebted to needle, suture, and my fingers.

My operation was performed in the following manner: If the reader will divest himself of his coat and place the cuffs parallel, he can look down into the sleeve ends as into a double-barrelled gun. The inner surfaces of the sleeves correspond to the mucous surfaces, and the outer surfaces to the serous surfaces of the gut ends. Now, if the reader will sew the two proximal edges of the coat sleeves together, by a suture that passes entirely through them, he will find that he can readily sew fully half their circumference together. If now he will *turn in* the remaining borders, he will find that he can readily complete the circuit by sewing the outer surfaces. It was precisely in this way that I finally successfully approximated the intestines in Case 2.

The fact that the mucous membrane could be safely included in a suture emboldened me to repeat the operation; and finding by experience that my fingers could not always accomplish my purpose, I have added to my case two instruments that I have found very convenient not only as special aids in anastomoses, but also in general surgical work.

The first may be called tenaculum forceps (Fig. 1, *a*). I use them very much as women use pins and basting thread to secure their work temporarily while they are sewing it more securely. It does not matter what stitch is used—the whip stitch, through-and-through stitch, or over-and-over.

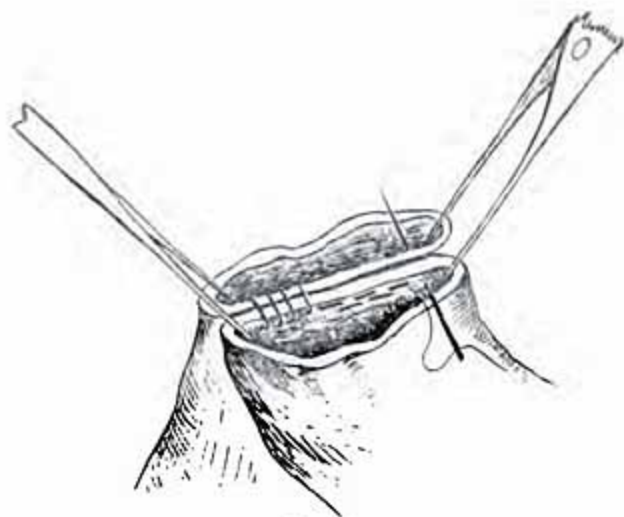

FIG. 2.

All that is essential is that the approximated bowels should be securely united. Having firmly approximated one half the circumference, I remove the forceps, and, turning the partly united structures half round, I seize the seam with my tenaculum forceps, and with a pair basting the work a little further on (Fig. 3), the through-and-through suturing can be continued almost entirely around the entire circumference. When near the end of the approximation I have found toothed forceps (Fig. 1, *b*), with serrations on the edge, convenient for turning in the mucous edges, adjusting the serous, and holding them approximated until sutured (Fig. 4). In the sewing of the serous surfaces any suture that one finds convenient will answer the purpose. The rule that the serous coat must only be pierced is no longer entertained; and the operator will act wisely if he

penetrates the thickness of the intestinal wall. Whatever suture he employs, if he takes them fairly near together he will find that they will be buried as he tightens them. In this way every possible intestinal anastomosis can be accomplished—viz., end-to-end, lateral, and insertion.

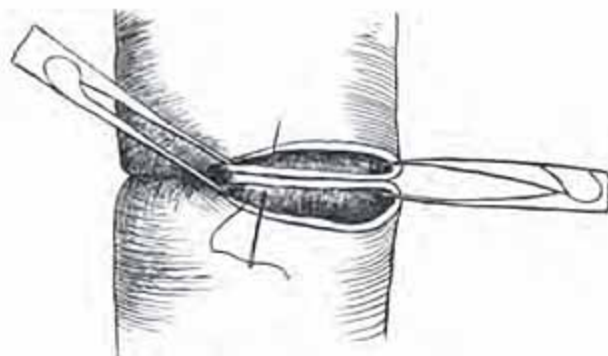


FIG. 3.

I have said nothing of the technique of the operation. This part has been so constantly before the profession that all are familiar with it.

A further remark about the instruments. I do not care to recommend these instruments simply as aids in intestinal work.




FIG. 4.

The *tenaculum* forceps are valuable in protecting the field of operation. In work upon the neck, or near any part where the hair cannot be removed, after the incision through the skin has been made these instruments can be made to catch the edge of aseptic towels to the edge of the wound and hold them secure un-



til the operation is completed; while the forceps with lateral serrations are often most convenient as hemostats, or as searchers for tendons which are retracted in wounds of the hands and feet.

I have not made upon the living subject an anastomosis be-

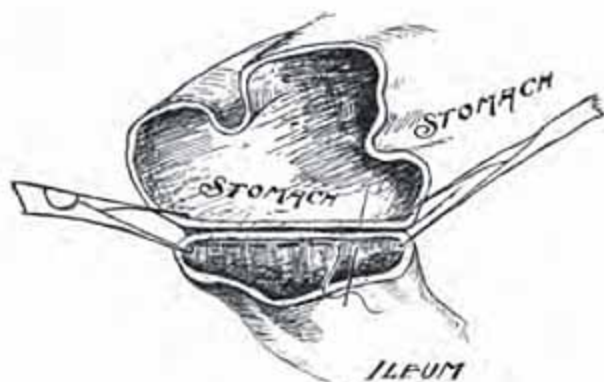


FIG. 5.

tween the stomach and bowel, using the instruments I have described. However, I think it can be easily done, and the accompanying drawings illustrate the manner in which I should do it.

#### CASES.

CASE I.—Thomas J., aged 46, admitted to the Presbyterian

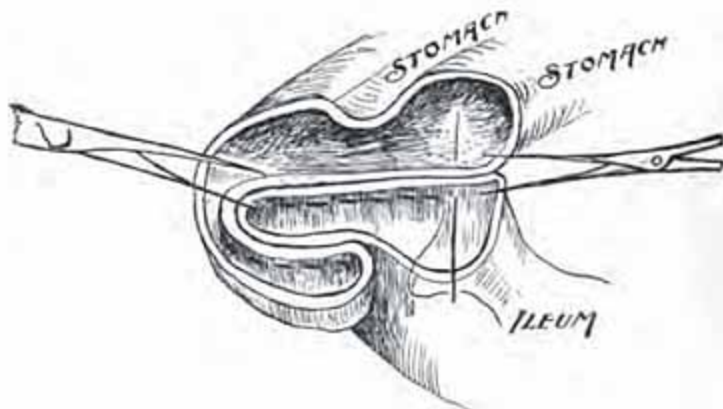


FIG. 6.

Hospital February 22, 1894. He was suffering from carcinoma of the pyloric orifice of the stomach. In order to relieve the obstruction a gastro-enterostomy was performed; the bowel was united to the stomach by means of the Murphy button.

He was discharged from the hospital on April 9, 1894. In

August, 1895, he was readmitted suffering from intestinal obstruction. A second operation was performed, but the cancerous mass was now so extensive that it was impossible to remove it, so the stomach was stitched to the abdominal wall and wound drained. He died some hours later. At the autopsy the Murphy button was found in the stomach.

CASE II.—Ellen C., aged 23, admitted to Presbyterian Hospital June 13, 1898. She gave the following history: Operated on for appendical abscess at the German Hospital in August, 1896. The operation was followed by a fecal fistula which discharged until November, 1897, when she was again operated upon at the German Hospital. The wound healed after this

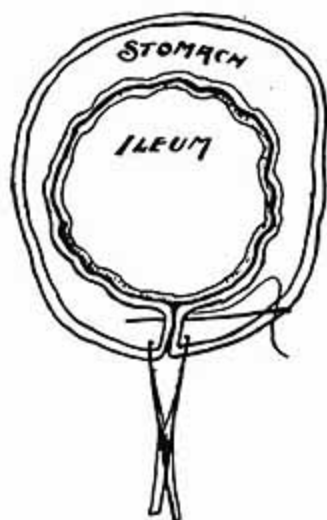


FIG. 7.

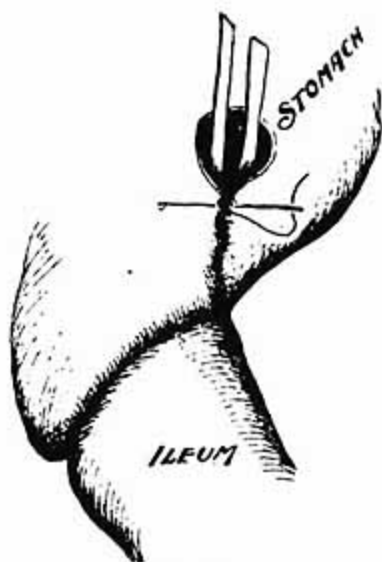


FIG. 8.

operation, but about one month later began to discharge again and has continued to do so ever since.

On June 16, 1898, she was etherized and Dr. Allis performed the following operation: An incision five inches long made along the line of the old scar, the fistulous track dissected out, peritoneal cavity opened, adhesions broken up, the perforated intestine resected, and an end-to-end anastomosis made with the Murphy button. The peritoneum along the line of the fistulous track was covered with many small, raised, round nodules which looked not unlike large miliary tubercles. One of these, containing a yellow, cheesy matter, was cut out and submitted to microscopical examination, but the pathologist pronounced it non-tu-

bercular. The abdominal wound was closed without drainage. Everything progressed favorably until July 1, when she began to have pain in the wound. A skiagraph showed the Murphy button to be in its original position. On July 5 the stitches in the abdominal wall were all removed and it was found that there was a sinus at the upper angle of the wound. Another skiagraph showed the button had not changed its position, so it was decided to cut down and remove it, which was done July 28. The wound was now packed with gauze and allowed to heal by granulation. A fecal fistula soon developed near the centre of the wound, which positively refused to heal, notwithstanding it was curetted out and thoroughly opened several times. On October 25, 1899, she was again etherized, a long incision made, peritoneal cavity opened, the numerous adhesions matting the intestines together broken up, about ten or twelve inches of diseased intestine resected, and an end-to-end anastomosis made in the manner described above by Dr. Allis, except that in this case common hemostatic forceps were used instead of the tenaculum forceps, which had not been invented at that time. She made an uneventful recovery and was discharged from the hospital December 15, completely cured. She has been recently heard from and still enjoys the best of health, having absolutely no trouble of any kind.

CASE III.—Mrs. K., aged 46, admitted to Presbyterian Hospital July 19, 1901, suffering from a strangulated inguinal hernia on right side. She was immediately etherized, an incision made over the mass, the hernial sac opened up, the gut found to be gangrenous; the abdominal incision was then lengthened upward, all of the gangrenous gut resected, an end-to-end anastomosis made in the manner described above. In this case the special forceps devised by Dr. Allis were used and greatly facilitated the operation, at the same time enabling the two ends to be more firmly and accurately united. The abdominal wound was left open, packed with gauze, and allowed to granulate. The woman was discharged from the hospital August 30, cured. There was not an unfavorable symptom following the operation, and, so far as we could tell, the bowel was completely restored to its normal condition.