


Charles P. Noble M.D.  
U. of Pennsylvania / Kensington Hospital  
Published in : Am J Obs Dis Women & Children  
Volume 45 1902



REMOVAL OF FIBROID TUMORS THROUGH THE VAGINA  
BY CONTINUED SPIRAL INCISION.

It occurred to me that the removal through the vagina of large fibroid tumors in the lower portion of the uterus might be facilitated by a slight modification of the incision of the tumor, instead of losing time in catching and recatching parts as they are cut away in the process of morcellation. I endeavored to devise a plan by which, once fastening a hook in the tumor, it might serve the purpose of traction for the entire operation without removal during its progress. The hook, therefore, is inserted into the lower portion of the tumor after splitting and separating the capsule, and the incision made in the spiral direction, cutting from right to left like a right-hand screw, thus making a thick rope of fibrous tissue two inches in diameter which when removed has a characteristic corkscrew appearance.

Fig. 5 shows the mass or tumor in this shape as drawn out of

the vagina. Fig. 6 represents the mass or tumor twisted into its original shape, but showing the spiral line of incision. The tumor was five inches in diameter at its greatest width and six inches in length, completely filling the bony pelvis. A portion

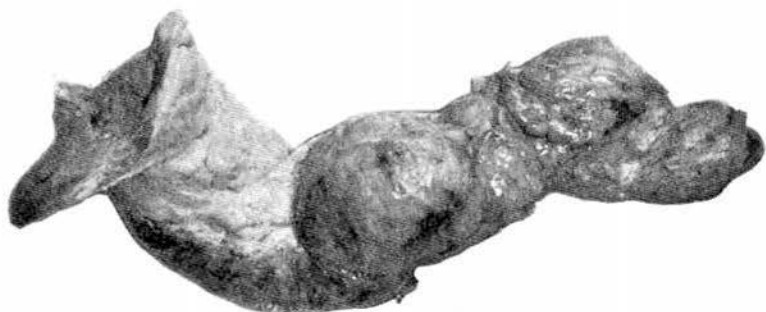

FIG. 5.—Characteristic corkscrew appearance of tumor.

of it extended into the vagina and caused superficial pressure necrosis of the vaginal mucosa.

The operation was done under nitrous oxide and oxygen gas and the tumor removed in six minutes, after which two large



FIG. 6.—Tumor twisted into its original shape, showing spiral incision.

vessels were ligated and the capsule sutured; then a perineorrhaphy was done with buried sutures, all within twenty minutes of anesthesia, showing a great saving of time in the operation and facilitating the execution of same.

It is important not to cut small strips or make the turns in the spiral line too close together, as there must be body enough in the parts removed to prevent breaking or tearing away. A rope of tissue two inches in diameter will be strong enough to stand considerable strain in solid or single-lobed tumors. The traction forceps should be held by an assistant. The index finger of the left hand is used to guide the point of the scissors, and to separate the capsule from the tumor as the cutting proceeds, using hawkbill scissors, as those with ordinary straight edges will retard the progress of the operation.

This method is suited only for large growths, as small ones can be turned out *en masse*, and is not recommended to take the place of all cases of morcellation, but will be found useful in isolated instances.

---

This method was popularized by A.F. Lash M.D. at the U. of Illinois-Chicago/Cook County Hospital in 1941.

Am J Obs Gyn 1941:42:453-459

He does not appear to have been aware of Noble's article.