

# The Journal of Obstetrics and Gynæcology of the British Empire

---

VOL. IX.

APRIL, 1906.

No. 4.

---

## On Paravaginal Section : with some illustrative cases.\*

By Sir WILLIAM SINCLAIR, M.D., *Professor of Obstetrics and Gynæcology, Victoria University of Manchester.*

PARAVAGINAL section, as an operation, comes into comparison with ordinary vaginal hysterectomy and abdominal hysterectomy. Between the ordinary vaginal operation and the paravaginal method there cannot, however, be any considerable rivalry. When the uterus can be removed *per vaginam* without unusual difficulty, no operator would think of complicating the proceedings by introducing the paravaginal incision. But, as will be shown in the following pages, there exists a class of non-malignant cases in which the vagina is ill-developed or senile, and the disease has produced a considerable mass of uterine tumour too large to be manipulated by the ordinary vaginal method. In such cases the paravaginal incision affords an easy and comparatively safe means of completing the hysterectomy and of avoiding the complicated and dangerous alternative offered by abdominal section.

The paravaginal operation was first performed by Schuchardt of Stettin, about ten or twelve years ago. The method was evolved in the endeavour to extend the percentage of operability in cancer of the uterus, to obtain better remote results, and at the same time to avoid the dangers inherent in those ghastly dissections, styled abdominal hysterectomy, which have since become the correct fashion and the criterion of an advanced position in scientific gynæcological surgery in some parts of Europe and America.

The best description of Schuchardt's operation, including an exposition of his aims and an account of his results is to be found in his contribution to the *Monatsschrift für Geburtshülfe und Gynäkologie*

\* Amplified from a paper read before the North of England Obstetrical and Gynæcological Society, December 15th, 1905.

of June, 1901, "Ueber die paravaginale Methode der Exstirpation uteri und ihre Enderfolge beim Uteruskrebs."

In adopting and improving his method of operation Schuchardt had exclusively in view the surgical treatment of malignant disease of the uterus when the disease was so far advanced as to make the ordinary vaginal operation extremely difficult or impossible. His operation, then, was offered as an alternative to abdominal hysterectomy for cancer of the uterus. It would, therefore, be hardly relevant to the present purpose to trace the history of the various operations and to try to appraise their value. They are of interest in the present connexion only as showing the efforts which were made all over the civilized world to evolve as safe and easy an operation as could reasonably be considered effectual without alighting upon the method of paravaginal section. Yet from incision of the perineum down to the sphincter and continued along the vagina in the middle line as deep and as far up as could be effected without injury to the rectum, which we all occasionally practised, to the method of Schuchardt, was not by any means a great leap in the process of evolution.

An historical account of the sequence and relations of the various methods of removing the cancerous uterus will be found in an article which I contributed to the *Practitioner* of July, 1902, entitled "Operations for Cancer of the Uterus." It may be sufficient here, considering the practical conclusion to which I desire to lead up, to summarize very briefly the chief points in the rather too detailed statement of that article.

It was in 1878 that Freund, of Strassburg, introduced his abdominal operation for cancer of the uterus, and in the same year Czerny, of Heidelberg, called attention to the vaginal method of extirpation. Both operations were revivals of methods tried earlier in the century when the time was not yet ripe. A comparison of the published results obtained by the two methods showed that at one period Freund's operation had a mortality of about 75 per cent. and Czerny's of about 30 per cent. Freund's operation was then permitted to fall into desuetude for many years. Vaginal hysterectomy, improved in details, showed more and more favourable immediate results, the mortality falling to 10 per cent. or less. So it held the field for many years, in spite of the disfavour of some influential teachers of gynaecology, especially in Germany and Great Britain.

Among the curiosities in the history of gynaecological surgery must remain the sacral method of operating for the extirpation of the cancerous uterus. It was, like Schuchardt's operation, a result

of the efforts which were so long continued to extend the percentage of operability, that is to say, to deal with cases in which the disease was so far advanced as to make the question of any radical operation very doubtful. It seems strange, on looking back, that the inventors of the disastrous sacral method missed the comparatively safe and easy paravaginal route to the parametrium and broad ligaments. Students of the history of gynaecology who read English works only may be referred to the article on "Malignant Diseases of the Uterus" in the first edition of Allbutt and Playfair's "System of Gynaecology," for a brief account of the short-lived sacral method.

When gynaecologists throughout Europe and America had been for years vying with one another in record-breaking reductions of the mortality from vaginal hysterectomy, voices began to be raised claiming attention to the distressing remote results of the operation. The general experience, apart from published results, must have supported the contention that in the vast majority of cases the disease recurred early, in the cicatrix or by lymphatic invasion, and that any prolonged immunity from the disease was the exception, not the rule. In spite of the continued advocacy of the older operators, such as Fritsch, who claimed that better results had been obtained from vaginal hysterectomy than from any other operation for cancer, a reaction against vaginal extirpation, partial or complete, rapidly set in, and abdominal hysterectomy became almost a fashion.

The assumption on which the abdominal route was advocated appeared to be that recurrence was mainly due to the incompleteness of the operative proceedings, not to the nature of the disease. The practice of the extended operation, with resection of the ureters if thought necessary, and dissecting out of enlarged lymphatic glands, appears to have been founded on a rather mechanical theory of the disease. It amounted to this, that if the operator could only extend the operation-field to apparently healthy tissue and eradicate all the lymphatic system which appeared to have undergone the coarser anatomical changes, the best possible remote results must be obtained. But experience has not justified the theory or the practice. The immediate results have been in the admitted experience of many operators simply appalling, and even those who claim the greatest success are receding from their original position and limiting in various ways the area and the details of their dissections. Few operators will now be heard supporting the opinion expressed at a Congress of French surgeons held in 1899: "*La mortalité opératoire n'est plus un argument capable d'arrêter nos efforts.*" The efforts of the minority who treat their *matériel* in this spirit have unfortunately

continued, but the experience of most gynæcological surgeons appears to have led to a pause for reflection, and a consequent modification of their practice. Resection with re-implantation of ureters has ceased to be recorded, and the whole *technique* appears to have become simplified. The present state of opinion and practice, in Germany at least, is well shown in an article by Dr. R. Schindler, of Graz, entitled "Statistische und anatomische Ergebnisse bei der Freund-Wertheimschen Radikaloperation des Uterus-Karzinom," just completed (March, 1906) in the *Monatsschrift für Geburtshülfe und Gynäkologie*. The doubt and hesitation which the immediate mortality produced were further accentuated and increased when sufficient time had elapsed to permit of an appraisal of the remote results. It has now to be admitted by most of the original supporters of the extended abdominal operation that the remote results are hardly, if at all, better than those obtained by the vastly less dangerous radical vaginal method. There are, no doubt, extravagant claims put forward by some late converts to abdominal hysterectomy. They rise in their zeal beyond the restraints of arithmetic; when they cannot record they utter predictions. Whether these will be justified remains to be proved; past experience would lead us to wonder at their confidence and to harbour doubts concerning their judgement.

This is perhaps the most suitable place to introduce a summary comparative statement of the results obtained by the operations.

*Primary Results of Vaginal and of Abdominal Extirpation of the Cancerous Uterus.*

Although the mortality of vaginal extirpation after its reintroduction into operative gynæcology by Czerny was high at first, it rapidly sank to a marvellously low figure. In 1895 Hirschmann collected from the practice of seventeen operators 1,241 cases with a mortality of 8·8 per cent. Schuchardt's mortality was high 12·2 per cent., probably because he was too eager to extend the percentage of operability, and did not reject too advanced cases. Individual operators have reported results varying to a considerable extent: *e.g.*, Leopold had 5·7 per cent.; Hofmeier, 10·8 per cent.; Winter, 7·5 per cent.; Fritsch in his last series 6·5 per cent.; Amann, 4 per cent.; Richelot, 6·8 per cent.; Küstner, 1·8 per cent. Olshausen had a mortality over all his cases of vaginal extirpation for cancer of 8 per cent., but he was able to report a whole series of 100 operations with only one death resulting or following.

Considering the character of the field of operation in cancerous

uterus, it is not surprising to find that in the great majority of cases the fatal result was owing to septic infection. It may be assumed that the strictest antiseptic precautions were always taken. Winter reports 74 deaths from infection out of a total of 116 fatal cases. Zweifel attributes 81·8 per cent. of his fatal cases to septic processes of one kind or another.

Keeping the recommendation of paravaginal section in suitable non-malignant cases in mind it is satisfactory to examine the results of total vaginal extirpation on account of myoma, endometritis, prolapse and other conditions. Leopold's mortality was 2·7 per cent.; Richelot's, 2·6 per cent.; Hofmeier's, 0 per cent.; Olshausen's, 0 per cent.

When we come to compare with these facts the immediate results obtained by the extended abdominal operation we are met with some difficulties which may be pardonably evaded in a digression such as an appeal to figures under the present circumstances must in some measure be considered. Those who have read in detail the reports published under the direction of some operators will readily understand the difficulty. It is, however, perhaps compulsory to give the arithmetic of a few pioneers to which the objections do not apply. Freund had 3 deaths in 15 cases = 20 per cent. Wertheim lost 12 in his first series of 30 cases = 40 per cent.; but, in a total of 120 cases his mortality amounted to *only* 20 per cent. Mackenrodt gives two series of cases: in the first the mortality was 26·6 per cent., in the second series 11·7 per cent., the favourable result being attributed to the adoption of the method of drainage of Mikulicz. Döderlein and Krönig think we shall not be far wrong in setting down the present mortality from the extended abdominal operation in cases of cancer as 15 per cent. So here we have an arithmetical expression of the best results that have been obtained in the best appointed public gynæcological institutions in Germany, France and Italy, after ten years of experimental operating by the abdominal method.

With the same objects in view which had been sought through the revival and extension of Freund's operation, the enlargement of the percentage of operability for cancer and improvement in the remote results, Schuchardt worked out his operation by means of an organic modification of the vaginal method. He was influenced also by the desire to diminish the shocking mortality of the abdominal operation. In the attainment of these objects he certainly succeeded. Schauta, of Vienna, the birth-place of the extended abdominal hysterectomy, was so discouraged by his experience of Wertheim's operation that he

arrived at the conclusion that better results, immediate and remote, were to be obtained by the vaginal route and by a careful selection of cases presenting themselves for treatment. So he turned to the paravaginal operation, and after performing it 30 times, he published a report with commentary.\* Schauta had an operation mortality of about 11 per cent., but some of his cases were too far advanced, with bladder and ureters already involved. He maintains that in the paravaginal operation we have a method of procedure by which we are enabled to deal with infiltration of the parametrium as widely as by any operation yet proposed.

It has been said that Schuchardt attained the three objects which he had in view: he extended the operability to 61 per cent.; he obtained 40 per cent. of cures according to the conventional standard of immunity for five years; and his immediate operation mortality at the time of his last published report was 12·2 per cent. He might well, therefore, claim for his operation advantages such as those admitted by Schauta. He appears to me to have made good his case in favour of the operation as employed for fairly advanced cases of cancer of the cervix; as we shall see in the sequel its admitted drawbacks disappear and its advantages become strikingly apparent when the operation is applied to cancer of the body of the uterus and to certain conditions of the uterus and vagina occurring in elderly virgins and in nulliparous women generally.

It may be claimed for the paravaginal operation that it is easy to perform; the surgeon can count with absolute certainty on being able to complete the operation; accidents to the bowels, bladder and ureters, can be always avoided with ordinary care; hæmorrhage can be controlled in the early stage of the operation by pressure-forceps, and post-operation hæmorrhage from the broad ligaments, vagina, and paravaginal wound can be entirely prevented; by properly applied suturing and pressure with or without pelvic drainage the sides of the extensive wound are kept together and healing is obtained *per primam*: and owing to the avoidance of "accidents" and the reduction of manipulations to the minimum, the paravaginal operation is rendered the safest of all the methods of hysterectomy when the vagina is narrow or the parametrium is involved. These claims can be made good even when the operation is employed in the treatment of cancer, but when we widen the indications and apply it to cases, for example, of fibromyoma with adnexal complications, to conditions resulting from malformation in ill-developed uterus with very

\* "Die Operation des Gebärmutterkrebses mittels des Schuchardtschen Paravaginalschnittes." *Monatsschrift f. Geb. u. Gyn.*, Bd. xv., Heft. 2 (Feb., 1902).

PLATE I.

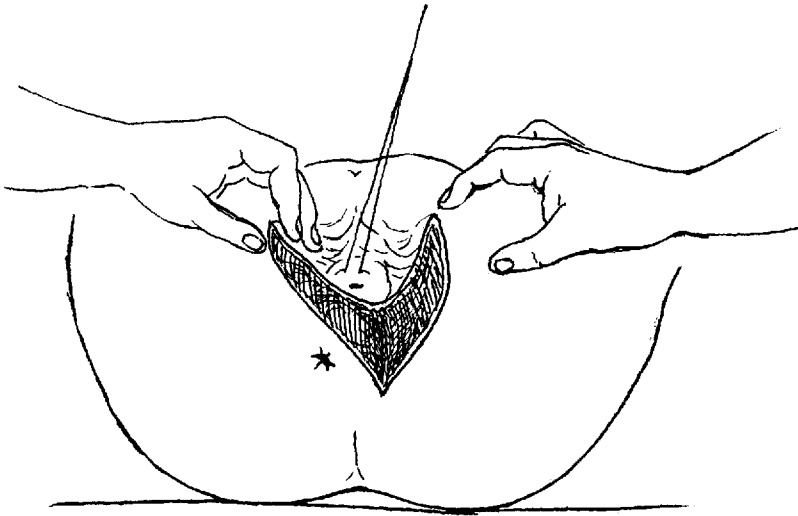


Fig. 1.

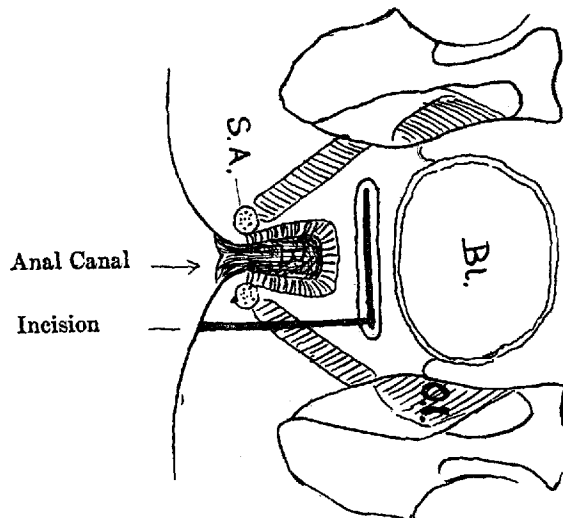


Fig. 2.



narrow vagina, we can foresee a revolution in the ease and safety with which hysterectomy can be performed. All the objections raised against paravaginal section, as applied to cancer of the cervix uteri, disappear when the operation is adopted for the extirpation of the non-malignant uterus and even in cancer of the body of the uterus in nulliparous patients.

THE OPERATION OF PARAVAGINAL SECTION FROM THE POINT OF VIEW  
OF OPERATIVE GYNÆCOLOGY.

The object of the incision is to obtain free access to the diseased organs consistently with certain surgical principles. If care be taken not to injure the sphincter ani and the rectum, almost every other structure may be cut through in order to gain a free and extensive field for manipulation of the affected parts. The left labium is cut through and with it the whole of the vaginal tube and vault; the paravaginal and pararectal tissues are laid open; the levator ani and coccygeus muscles are entirely or partially divided as well as the cellular tissue of the ischio-rectal fossa. The first incision through the labium is made externally through the skin and subcutaneous structures of the perineum round towards the coccyx below the level of the anus, so as to get the widest gaping of the wound and consequently a full view of the parts situated higher up.

The second part of the operation consists in making a circular incision round the vault of the vagina, so as to separate the portio vaginalis uteri and gain access to the broad ligaments. The third stage is the process of separation of the diseased uterus by ligation of the broad ligaments, which must vary to some extent according to the complications of the individual case.

In performing the operation it is best to have the aid of two assistants who are familiar with the steps in the surgical proceedings. Suitable specula are used to expose the parts, and the vaginal portion is steadied as required by the assistant on the left of the operator. The operator seizes the perineum and introitus in the middle line with the thumb and forefinger of the left hand: the first assistant standing on his right side takes hold of the left labium about the middle and helps to put the parts slightly on the stretch. The operator then makes rapidly and firmly the incision through the labium between the two sets of fingers and runs it outwards and downwards in a curve round but well free of the anus till it reaches the coccygeal region. The incision is then carried upwards along the whole length of the vagina to near the uterus on the left side of the posterior fornix. The hæmorrhage is now so profuse as a rule



that it is best to stop cutting and seize bleeding points with pressure forceps. With increasing experience the tendency appears to be to endeavour to arrest the hæmorrhage completely at this point before proceeding further. Then, by small incisions and blunt dissection with the finger or the handle of the scalpel into the ischio-rectal fossa, the first stage of the operation is complete.

The second incision, that round the portio vaginalis, is now made. Its distance from the os uteri must vary according to the nature of the disease of the uterus, especially the size of the mass to be brought through the wound. The remaining details of this part of the operation are just those of the corresponding stage of ordinary vaginal hysterectomy, the difference being the remarkable facility with which all parts, including the parametrium of both sides, can be reached and manipulated. It is my routine practice as soon as the peritoneum is opened, first in the vesico-uterine fold, and then in the pouch of Douglas, to push through specially prepared sponges held by silver wire, so that when the uterus is separated and withdrawn the bowels are held up out of sight or in any case out of the reach of accident.

The closing of the wound is greatly facilitated by the previous application of special forceps to the angles of the vagina formed at the junction of the paravaginal and the circular wounds. The forceps should be applied at the moment the circular wound is completed: otherwise it is sometimes difficult to identify the parts owing to the extraordinary retraction which usually occurs at once.

When, as the first step in closing, those points in the vaginal wall are brought into prominence by a long silk suture which is left untied for the present, the extent and relations of the wound become apparent, and the process of closure is rendered comparatively easy. The method of proceeding in the closure of the wound from this stage onwards is as follows: the chasm in the pelvic floor is closed by inserting fine silk sutures, which enter the vaginal wall in front and pass backwards through the cellular tissue and peritoneum; they then enter the peritoneum of the pouch of Douglas and pass forwards through cellular tissue and posterior vaginal wall. The suture which includes a portion of the cut broad ligament on the left side requires special care. As the sponges are drawn out between the as yet untied sutures, the "thimble" drainage tube is inserted, preferably well towards the left side. The sutures of the pelvic floor are now tied; and that portion of the operation is complete. The vaginal portion and the external portion of the paravaginal wound are now closed successively with fine silk sutures, care being taken to leave no channel undermining the superficial portions of the wound at any

point. The pressure of the thimble drainage tube helps to seal the upper end of the paravaginal wound, thus preventing the formation of a sinus.

The routine practice is finally to irrigate the whole field of operation by means of normal saline solution passed through the drainage tube until oozing has ceased. The vagina is then packed with suitably prepared gauze, the external wound rubbed over with iodoform and the external dressings applied. Special care is taken with the suturing of the external portion of the wound so as to prevent infection by urine, fæces, or discharges. The wound almost invariably heals by first intention. Before many weeks are over the site of the external wound is perfectly smooth (see Plate V.), and later, it sometimes requires careful inspection to detect the traces of the operation.

#### THE OPERATION FROM THE ANATOMIST'S POINT OF VIEW.

My colleague, Professor A. H. Young, has very kindly given me assistance in placing the details of the anatomy of the parts before the reader, for which I am most grateful. In March of last year he afforded me the opportunity of performing the operation upon the cadaver, and Dr. J. D. Lickley, senior demonstrator of anatomy, was obliging enough to assist me and superintend my efforts, and then to write out his impressions from the anatomist's point of view. Professor Young afterwards dissected the parts and placed his description of the wound at my disposal.

#### *Professor Young's Description.*

"Patient placed in the lithotomy position; an incision was then made from the posterior part of the lateral margin of the vaginal orifice obliquely downwards and outwards to the ischio-rectal fossa. The incision from the vaginal orifice commenced about one inch to the left of the posterior mesial line of the orifice and continued obliquely downwards and to the left to end in the ischio-rectal fossa nearly midway between the anus and the tuber ischii, or perhaps a little nearer the anus, skirting and almost parallel with the left lateral margin of the anal orifice.

The incision was a clean, decided cut, and divided the skin, the fat, and superficial fascia, the sphincter vaginæ, bulbo-cavernosus, the transversus perinei, and the lower part of the triangular ligament. Further, it divided the superficial perineal vessels and nerves, and the anterior branches of the inferior hæmorrhoidal vessels and nerves. At the beginning of the incision it was close to the bulb of

the vestibule, but this was not injured, and the gland of Bartholin was also uninjured.

In the ischio-rectal fossa the incision was fairly deep, and divided the levator ani. If the incision had been directed more obliquely to end a little further away from the anus, the levator ani would have remained uninjured.

A second incision extended along the whole length of the posterior lateral part of the vaginal wall. It commenced on the inner aspect of the vagina about the level of the os uteri, and terminated below at the upper end of the first incision. This second incision did little more than cut through the vaginal mucous membrane and sub-mucous tissue, and no special blood-vessels were involved."

It would be superfluous for the gynæcologist to remark on the enhanced value bestowed upon his account of the surgical details by the exact description given by the Professor of Anatomy. One inference suggested incidentally in the anatomical description, and supported by further experience, is that in certain comparatively simple cases the dissection need not extend so high up or go so deep into the pelvis as has hitherto been the practice, and that sufficient room for inspection and manipulation may be obtained without carrying the external wound so near to the coccyx.

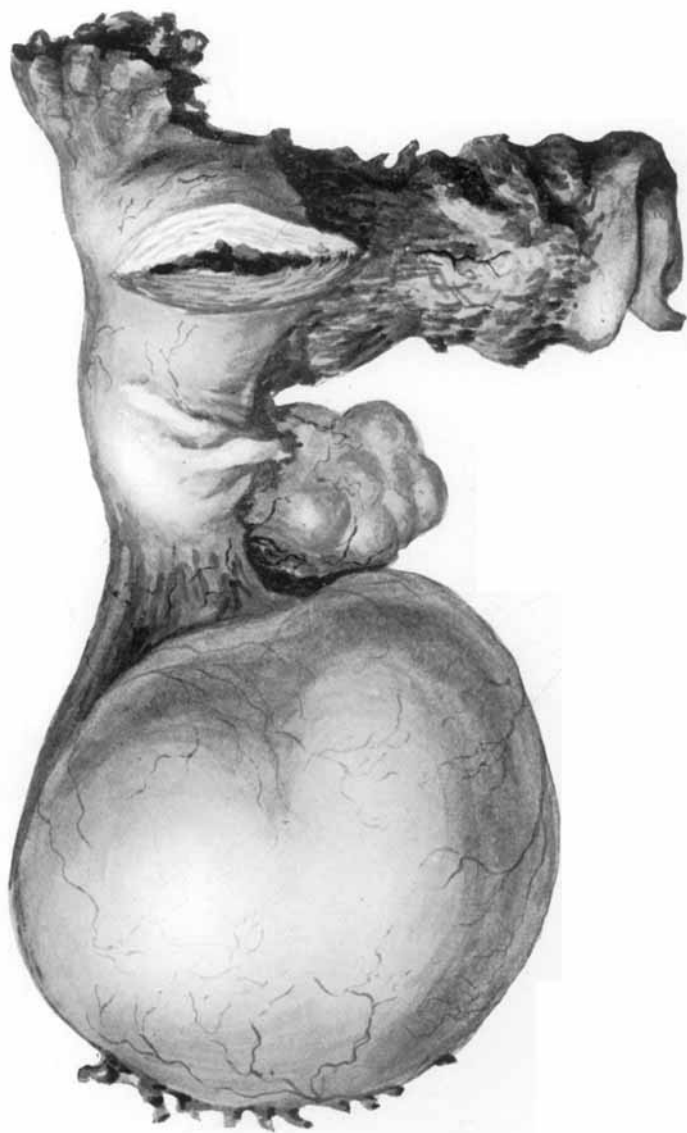#### THE OPERATION IN NON-MALIGNANT DISEASES.

The wave of pessimism which has been passing over Gynæcology in relation to the results of operations undertaken in the hope of curing cancer of the uterus need not disturb our judgement when we come to estimate the value of the paravaginal operation in non-malignant cases or in cancer of the corpus uteri. To call attention to the advantages of this extension of the operation is the main object with which this article has been undertaken. Cancer of the cervix uteri is an inevitably fatal disease if let alone. Therefore, the hope of conferring great benefit justifies an extensive operation; but diseases which cause suffering and chronic bad health without seriously threatening to become fatal, demand a comparatively safe and easy method of operative treatment. It is in relation to this class of case that it may be confidently claimed for the paravaginal operation that it offers unique advantages and promises to mark a distinct step in the evolution of gynæcological surgery. But this claim can best be established by giving the details of individual illustrative cases:—

#### CASE I. ATRESIA CERVICIS UTERI.

B.H., aged 31 years, unmarried (patient of Dr. Mowat, Bolton), was admitted to the Southern Hospital, Manchester, on May 11th,

PLATE II.



1904, complaining of periodic pain in the lower part of the abdomen. The patient had never menstruated, but at the age of 15 she began to suffer from attacks of pelvic pain once a month. The duration of these attacks was about seven days, and the interval between the end of one attack and the beginning of the next was about three weeks. The patient had to go to bed during the continuance of her pain; during the intervals she worked in the mill. In the year 1902 she underwent an operation in a local hospital. She thinks it was stated that both her ovaries were removed. After this she was free from pain for six weeks, but the attacks then returned and continued exactly as before. Her life now became a burden to her, and her health was becoming seriously undermined. She looked pale, worn, and much older than her years. On examination under anæsthesia the external genitals and vagina were found to be normal, but the cervix was small and elongated. The body of the uterus was short but thick, and a very firm, rounded tumour, the size of a small orange, occupied the pouch of Douglas. A probe passed into the cervical canal was absolutely arrested less than one inch from the external os. The scar of the previous operation was visible between the pubes and the umbilicus. The diagnosis was *atresia cervicis uteri* with hæmatosalpinx. It was decided to remove the uterus and tumour by the paravaginal method.

As the vagina was very narrow it was freely incised on the left side, the incision extending well into the ischio-rectal fossa and up to the cervix. The cervix was freed and the left Fallopian tube apparently distended with blood, was brought down. The left broad ligament was then completely divided. With some difficulty the cystic swelling on the right was delivered together with an ovary, and the right broad ligament was divided, setting free the uterine tumour and appendages. The left ovary was found to be absent. The pelvis was drained by means of a glass thimble-tube, and the paravaginal incision was closed. The patient made a good recovery and naturally experienced complete relief.

The specimen (Museum number 6869) consists of the uterus, together with the right ovary and tube, and a parovarian cyst. The tube is seen to be stretched over the upper surface of the cyst, and its proximal portion is filled with black treacly blood. The right ovary is scarred and nodular. The left ovary is absent, having been removed at the previous operation. The distal end of the left tube is also absent. The stump of the left tube contains some of the old treacly blood by which it had been distended. The small uterus shows traces of the blood by which its small cavity was also distended.

There is no communication between the cavity in the uterine body and the canal in the lower part of the cervix. A probe passed in at the external os is completely arrested after passing  $\frac{3}{4}$  of an inch. Between the cul-de-sac of the cervix and the cavity of the body there is a solid plug of uterine tissue.

#### CASE II.—ATRESIA OF THE CERVIX UTERI.

M.P., aged 26, single, a patient of Dr. Waddell's, of Rusholme, Manchester, began with her present illness in July, 1901. She had pelvic pain which came on gradually, but she did not take to bed until August. She again became ill in September and November, 1901. In January, 1902, she had a sudden attack of pelvic pain with sickness and temporary intestinal obstruction and other symptoms of peritonitis. The patient has been ill at times for several years, the chief symptom having always been pain in the pelvis. She had never menstruated. A "show" occurred twice many years ago, probably traumatic from examination manipulation. Owing to severe attacks of pain she consulted a gynaecologist in another part of England, in June, 1898. An operation was recommended and was carried out in June, 1898. She was nearly six weeks in a "Home." After this, she remained well for nearly three years.

Her father is living; he is not known to have any constitutional ailment; his age is about 50. Her mother is living and in good health; her age is about 50. She has two sisters: one of them is married and has three children; the other one is single, aged 25 and in good health. Except that tubercular disease of the adnexa was suspected, no details have been obtained of the operation above referred to.

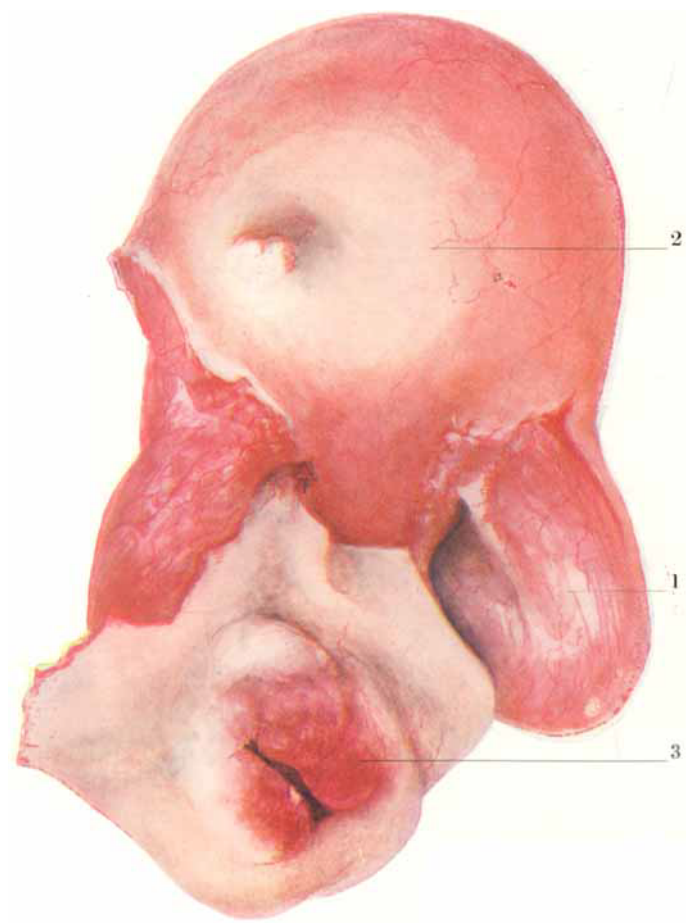
On external manipulation, nothing abnormal was observed.

On examination *per vaginam*, there was found to be enlargement of the body of the uterus, with obscure thickening in the broad ligaments, especially in the left upper portion. Neither sound nor probe could be passed even under anæsthesia. The cervical canal was of average length. Other organs and functions normal.

Medical treatment, including minor manipulations, pessaries, abdominal applications and appliances, was tried, but with no improvement. The final diagnosis was atresia of the uterus with hæmatometra.

OPERATION. Paravaginal section was performed on March 27th, 1902, Dr. Kilner Clark, of Huddersfield, assisting. The vaginal incision was easily made and there was not much hæmorrhage. The uterus was readily detached after ligation of the broad ligaments.

PLATE III.





There were some adhesions at the left cornu and there was some distension of the stump. The right ovary and tube were small, and were removed with the tumour. The cavity was drained as usual and the incision entirely closed.

*Examination of specimen.* On incising the anterior wall of the uterus blood squirted on to the window several feet away, the tension being enormous. The stump of the left tube was distended with black treacly blood.

*After history.* Recovery was very smooth, there being no incident worth recording.

The patient was seen occasionally for two or three years; she remained in perfect health.

The sudden illness in January, 1902, appears to have been caused by extravasation from the stump of the left tube.

#### CASE III.—MULTIPLE FIBROMYOMATA OF THE UTERUS AND RETRO-FLEXION.

A.D., of Alsager, single, aged 40, a patient of Dr. Crutchley's, was admitted into the Southern Hospital on the 10th January, 1903. The symptoms were an excessive and almost constant loss of blood, which had been going on for the last 12 months, and pain in the hypogastric region. The flow had never stopped for more than a week since it began. Menstruation began at 11 years and was regular until a few years ago. The quantity has increased during the last three years, though the interval has not been shortened. There has been dysmenorrhœa for several years.

The patient has a yellow cast of skin and has lost flesh. The previous health has in other respects been good.

*January 10th.* Examination: No tumour in abdomen. Resistance on pressure from hypogastrium along pelvic axis. P.V.: Vagina narrow; uterus low in pelvis, giving impression of retroflexion with complications. No note concerning heart examination.

In the hope of improving her condition the patient was kept in bed and treated for nearly three weeks for the anæmia and hæmorrhage.

*January 28.* Hysterectomy was performed by paravaginal section. The uterus was retroflexed but not adherent. The right tube and ovary were bound together by adhesions, the tube being slightly distended with clear fluid. The left tube and ovary were not removed.

The patient had an unusual amount of distress from the anæsthetic, but otherwise there were no symptoms worthy of detailed

record. The highest temperature was that recorded at the end of 36 hours, and was 100°. The patient sat up for the first time on February 15th, and she was discharged well on February 21st.

The examination of the uterus after operation showed that it contained nodules of fibroid tumour both externally and projecting into the cavity of the body. The condition of the tube and ovary removed appeared to be due to regurgitation of blood through the tube (*hæmatosalpinx*) and the consequent changes in the parts affected.

CASE IV.—FIBROMYOMA OF THE UTERUS UNDERGOING NECROSIS;  
SARCOMA OF THE POSTERIOR WALL.

E.G., aged 54 years, single, residing at Bradford, near Manchester, was admitted May 12th, 1904.

Menstruation began at 15 years, and was normal; there was never dysmenorrhœa. The menopause occurred at 49. The present illness began suddenly about six weeks ago with uterine hæmorrhage, which was profuse at first and then gradually diminished and ceased in four days. It came on again last week, and was accompanied with pain in the lower part of the abdomen.

The general health has been fairly good.

*May 5th, 1904.* Examination showed the vagina to be senile and its mucous membrane inflamed. The body of the uterus was enlarged, the sound passing  $3\frac{1}{2}$  inches. On the withdrawal of the sound a foul discharge followed by hæmorrhage took place. The patient was repeatedly examined during the next ten days. The question lay between cancer and fibromyoma undergoing degeneration.

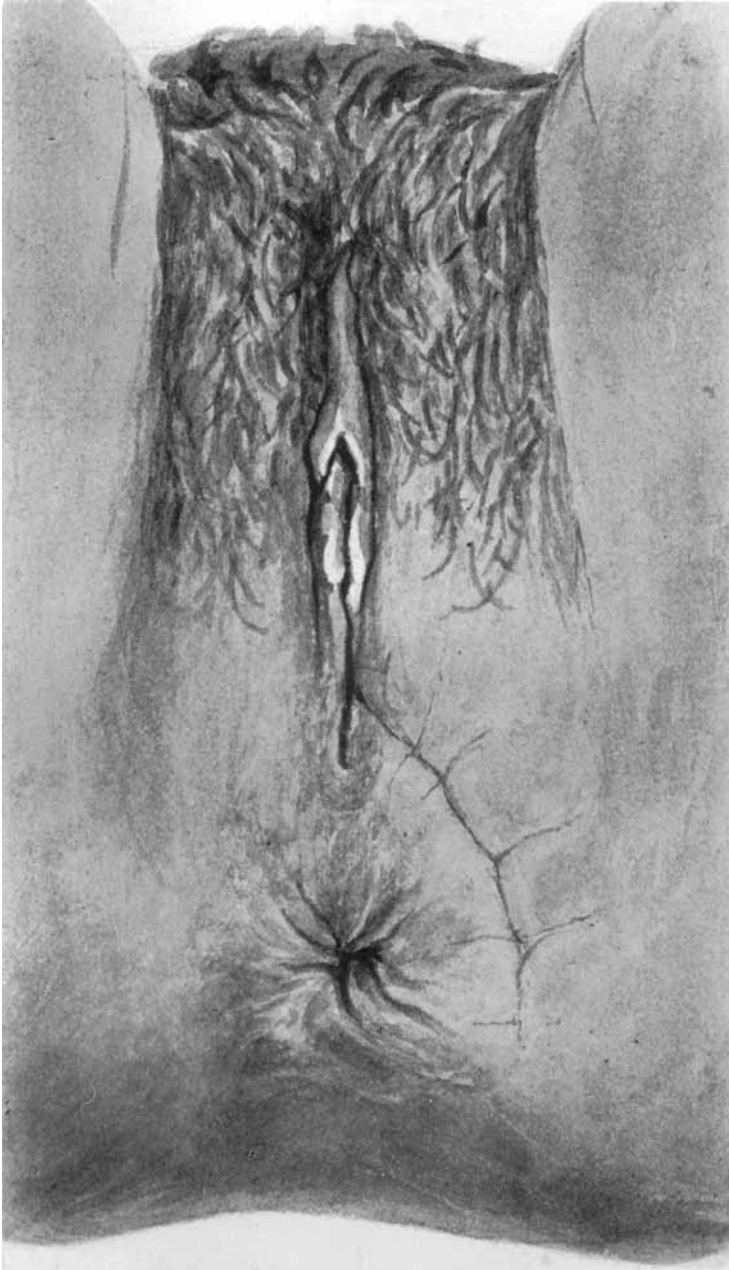
*Operation.* On May 25th the uterus was extirpated by paravaginal section. The usual incision was made from the posterior end of the vaginal canal to midway between the anus and the tuber ischii: the tissues having been separated the posterior-vaginal wall was cut through. A thick rubber tube had first been placed in the rectum as a guide to the relations of the parts. The uterus was separated from the bladder and then posteriorly, and the broad ligaments were ligatured and severed. The hæmorrhage was somewhat severe. The wound was closed and a glass "thimble" drainage tube inserted in the roof of the vagina. The final steps were as usual.

*Examination of parts removed.* There were three small sessile fibroids on the posterior wall of the uterus. The organ was opened along its anterior aspect and the cavity of the body was found to be filled with a broken-down mass resembling a sloughing fibroid or carcinoma. An incision into the posterior wall exposed a yellowish-

PLATE IV.

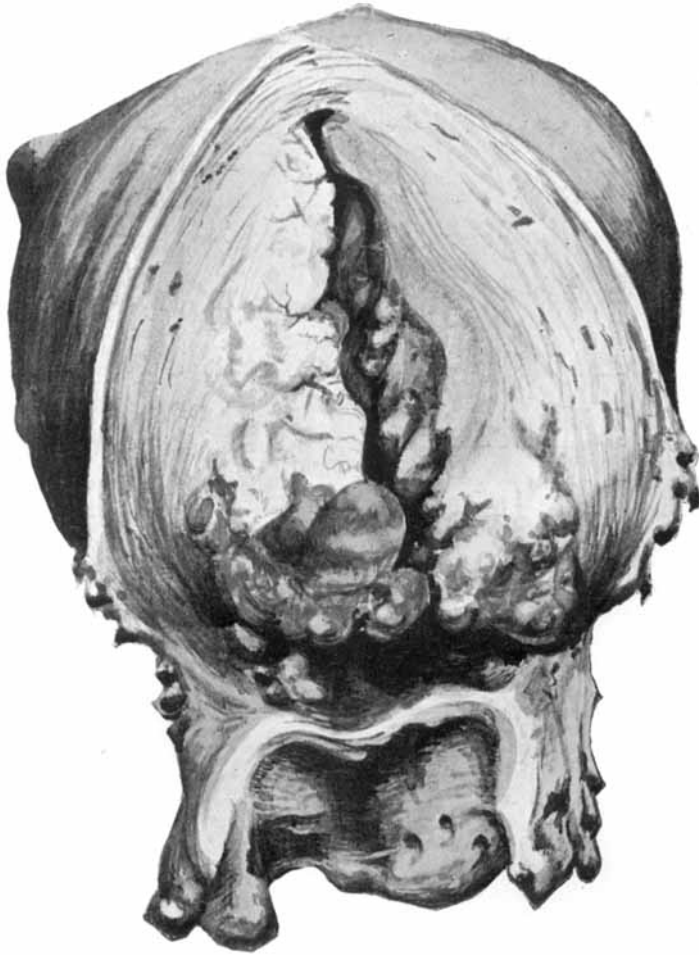

PLATE V.



white new-growth, supposed to be carcinomatous. Later examination proved the tumour to be sarcomatous.

*May 27th, 1904.* Wound dressed, gauze packing removed and wound irrigated through tube with boric acid solution.

*May 28th, 1904.* Wound dressed, packing and tube removed, flushing with boric solution and repacking.

*May 30th, 1904.* Packing removed and vagina flushed out with boric acid solution. Offensive discharge and small slough in ischio-rectal fossa. One stitch removed.

*May 31st, 1904.* Dressed, packed lightly, slough separated. No further details need be given. The patient was well enough to be discharged from the hospital on July 2nd, 1904.

This case illustrates the troubles which occasionally arise from the wound in course of convalescence, especially when the patient is elderly and in poor health. The paravaginal wound took a considerable time to heal, in the vaginal portion it healed partly by granulation.

When seen in July, 1905, the patient was perfectly well.

#### CASE V.—MULTIPLE FIBROMYOMATA OF THE UTERUS.

J.F.W., æt. 51, single, a patient of Dr. Stewart, Bacup, was operated upon in January, 1906. In this case there was a long history of uterine hæmorrhage and of repeated attempts to stop it and relieve the symptoms, with only temporary success. In the early part of 1903, after a hæmorrhage lasting seven weeks, the curette was used after dilatation by laminaria tents and zinc chloride was applied. From examination of the *débris* removed the diagnosis was then adenoma malignum, but it was resolved to wait and watch. All manipulations were extremely difficult and painful on account of a sort of malformation of the vagina consisting of a narrowing high up, less than an inch below the vaginal portion of the uterus. Owing to recurrence of symptoms the patient came under treatment again in November, 1904, and the same proceedings were repeated. The preliminaries of dilatation of a very hard cervix had to be carried out under anæsthesia owing to the difficulty presented by the vaginal diaphragm.

The curette brought away material similar to that obtained a year and a half before. The treatment was repeated, and owing to our unwillingness to proceed to extremes the same temporizing plan was again adopted.

At an interview with the patient on one of the first days of January this year (1906) it was ascertained that after many months

of "amenorrhœa" the symptoms had recurred. There had been three attacks of hæmorrhage within the last six weeks of 1905. On examination under anæsthesia, the uterus was found to measure five inches in length with wide cavity. Shape irregular, non-symmetrical.

The patient looked very ill, and she was advised to have the uterus removed. This advice was accepted, and accordingly in January, 1906, hysterectomy by paravaginal incision was performed. There is nothing further to record. The operation was easy, a thimble drainage tube was inserted. After the usual flushings it was removed in three days. Only external sutures were removed until complete healing had taken place in the paravaginal portion of the wound and in the vaginal cul-de-sac.

Examination of the uterus after removal showed that the bulk was made up of multiple fibroids. The mucosa of the body was velvety, and portions of it along with the irregular nodules removed by curetting immediately before the operation were sent to be prepared for histological examination. The naked-eye appearance suggested adenoma.

The patient went home well and much improved in appearance just four weeks after the operation.

CASE VI.—MALIGNANT DISEASE OF CERVIX UTERI; PYOMETRA;  
NECROSING FIBROMYOMA.

E.A.S., æt. 55 years; widow for several years; married 30 years ago; one child living, æt. 24 years; 3 miscarriages. Resident in a town in the Midlands. Health has always been good upon the whole. From the history, menstruation has been within the limit of health. Nothing abnormal about labour and childbed. History of abortions not very clear; no cause to be inferred.

From story of heredity only a certain want of vitality appears to be indicated.

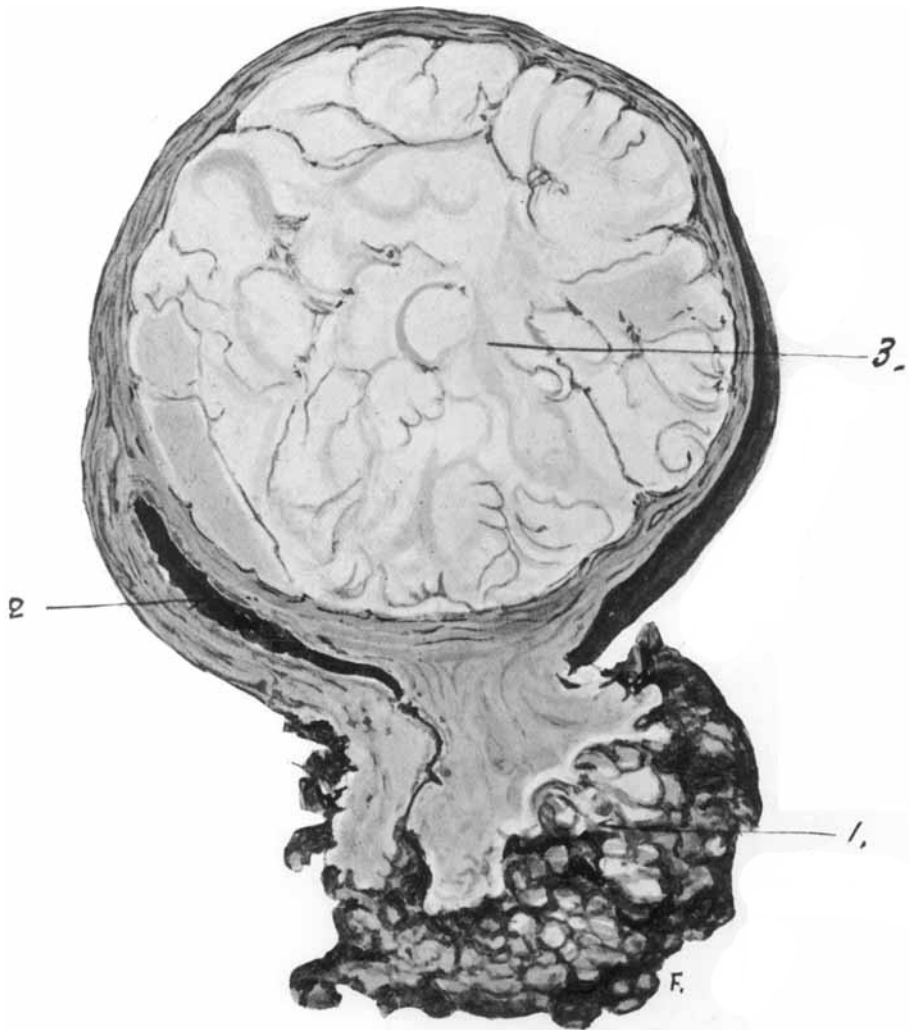
Menopause at or about 47—recollection not quite exact as to time. First symptom, occurring in July, 1905, was an attack of hæmorrhage from the uterus, which continued three days. The hæmorrhage recurred at the end of the same month, and continued for three weeks. There was no pain then. The bleeding came on again in the beginning of October. Since then it has been intermittent with a "nasty" discharge in the intervals.

In July, last year, she consulted a specialist in diseases of women, and her friends were then informed that her ailment was too far advanced for operation.

When I had an interview with Mrs. S., early in January, this year,



PLATE VI.





I found that the portio vaginalis uteri was nearly destroyed by epithelioma; the left parametrium was involved to a considerable extent, and examination per rectum revealed invasion of the left sacro-uterine fold. Otherwise, the uterus was so free towards the bladder and on the right side that I concluded that the case was not unsuitable for the paravaginal operation. There remained a certain undiagnosed element: the uterus was very large, there was a considerable amount of constant pain which did not appear to be accounted for by the amount of infiltration in the parametrium or elsewhere; and the patient's general state of health appeared deteriorated out of all proportion to the physical condition discovered locally. Heart, lungs, liver and kidneys appeared to be performing their functions normally, and the evidence pointed to careful habits of life. Considering all the circumstances it seemed best to advise the patient to submit to operation.

Admitted to nursing home January 27th, 1906.

Operation, February 1st. *Paravaginal hysterectomy.*

As unusual difficulties were anticipated I fortunately obtained the assistance of both Dr. Arnold Lea and Dr. W. E. Fothergill.

The left parametrium gave some trouble, but the ligatures could be placed well outside the area of infiltration. The left sacro-uterine fold had to be traced very far back, quite beyond the range of the practicable in ordinary vaginal hysterectomy, but the healthy tissue was reached and ligatures were put on by means of Hagedorn needles. The rest of the operation was performed without departure from the routine proceedings, except that the uterus was found to be very greatly enlarged, and there was a gush of foul pus whilst it was being dragged out. During the healing of the wound there was a little sloughing of the fat and subcutaneous tissues just at the outer extremity of the paravaginal wound near the anus. The healing of the vagina was throughout quite normal.

Examination of the parts removed showed the presence of pus in a considerable cavity formed by the body of the uterus—pyometra,—and a fibroid tumour within the uterine wall undergoing a process of degeneration (see Plate VI.).

The patient is now (March 1) completely convalescent. She is putting on flesh; she has some colour in her cheeks, and she has acquired an expression of animation and energy which was painfully lacking before the operation.

Examination of the vaginal cul-de-sac proves that healing is everywhere perfect, and there is absolutely no sign of exudation in the region of the left parametrium and sacro-uterine ligament.

This case is given here as an example of a class. It is the sort of advanced case in which Schuchardt performed the paravaginal operation as the safe alternative to the abdominal hysterectomy of Wertheim and others.

#### CONCLUSION.

That the operation of paravaginal section will make its way in this country into a recognised position, especially in the treatment of such cases as those given here as illustrations, may be confidently anticipated. When the operation becomes generally adopted the usual modifications of the various operators will no doubt claim attention, and improvements not now imagined will be introduced. Meanwhile we should make a beginning.

From private correspondence with German teachers and operators I infer that Schuchardt's operation is gaining a recognized position. Professor A. Martin, of Greifswald, informs me that he is performing the operation with increasing frequency, and I have observed that one of his pupils has published a thesis on the subject.\*

In the work of Döderlein and Krönig,† to which I have already referred, there is (p. 489) an excellent and concise description of the operation and a generous recognition of its value:—

In order to obtain better access to the field of operation, "Schuchardt worked out an operation of his own which has been proved to possess extraordinary advantages in the extirpation of carcinoma, even in advanced cases, and also in cases where there exist other indications for the total vaginal extirpation of the uterus. The object was attained with the help of the so-called 'paravaginal incision.' Lateral incisions of the vulva and vagina with the object of obtaining access in cases of narrow and rigid vagina had been formerly proposed and even practised. But special attention must be called to the fact that Schuchardt's incision differs essentially from these lateral incisions, and that it increases to a quite unexpected extent the facilities of access to the uterus and its vicinity."

Schuchardt, some years before his sadly premature death, was able to quote many of his German colleagues who had taken up the operation and had spoken and written in support of its adoption in certain suitable cases.

\* HAASE. *Kasuistik des Schuchardtschnittes*. Dissert. Greifswald, 1904

† *Operative Gynäkologie*. Leipzig, 1905.

In striking contrast with these facts is the reception which the operation has met with in Great Britain and America. Whether this is due to the passive resistance which we offer to the immigration of new ideas generally—our backwardness which we euphemistically designate our conservatism,—or whether the subject has unaccountably been overlooked, it is impossible to say with confidence. In an English work, entitled “Diseases of Women,” which has deservedly gone through several editions, the most recent dated 1903, there is no mention of Schuchardt or paravaginal section; and a weighty American volume on the “Practice of Gynecology,” with ten thousand illustrations, published last year, is equally devoid of any reference to Schuchardt’s operation.

Holding as I do the firm conviction that the introduction of the paravaginal operation was a distinctly beneficial addition to the resources of operative gynæcology, unique in its usefulness in the class of cases by which its benefits are here illustrated, I anticipate that its general adoption will arrive sooner or later, and I look forward to the satisfaction of reading the records of much good work by colleagues in Great Britain and the British Empire.

#### DESCRIPTION OF PLATES.

##### PLATE I.

Fig. 1. Diagram of incision not quite complete. From *Monatsschrift für Geburtshülfe und Gynäkologie*, by kind permission of Prof. A. Martin. Modified by Dr. W. E. Fothergill.

Fig. 2. Diagram showing the incision and its relations—schematic. From *Monatsschrift für Geburtshülfe und Gynäkologie*. Modified by Dr. W. E. Fothergill to show line of incision farther away from anus.

##### PLATE II.

Specimen from Case I., showing a cyst of the broad ligament, with atresia of the cervix uteri and the uterine cavity full of old blood-clot.

[From a coloured drawing by Dr. W. E. Fothergill.

##### PLATE III.

Uterus from Case III., with fibroid and retroflexion of the body and enlargement and erosion of the posterior lip of the neck; (1) distended tube adherent to ovary; (2) posterior surface of fibro-myomatous uterus; (3) posterior lip of cervix enlarged and eroded.

[From a drawing by Dr. R. S. Nichol.

## PLATE IV.

Uterus from Case IV., with sloughing polypoidal growth and sloughing mucous membrane of body of uterus. There are several small polypoidal fibroids on posterior part of fundus.

*[From a coloured drawing by Dr. W. E. Fothergill.]*

## PLATE V.

Showing the external wound after removal of the sutures in Case IV.

*[From a coloured drawing by Dr. W. E. Fothergill.]*

## PLATE VI.

Specimen from Case VI., showing (1) malignant disease of cervix; (2), pyometra; and (3) necrosing fibro-myoma.

*[From a drawing by Dr. W. E. Fothergill.]*