Migratory Adenomyomata of the Uterus.

By Archibald Leitch,
Pathologist to the Cancer Hospital, London.

Adenomyomata of the uterus are not uncommon though they have only been recognized in this country for the last ten years. It is sometimes possible to diagnose the condition clinically, but generally they are indistinguishable from ordinary fibroids or cases of fibrosis uteri, even on macroscopic examination, and the true nature is only detected on histological examination. In the commonest, or diffuse, condition there is a general thickening of the uterine wall with no sharp demarcation of the endometrial layer. Microscopically we find gland tubules, for the most part embedded in a loose cellular matrix, surrounded by the fibromuscular tissue which has undergone hyperplasia, and in most cases it is easy to demonstrate the connection between these islets and the endometrium. Generally the invasion of endometrium takes place over a wide area but sometimes the position of entry is more restricted and the connection between the two is difficult to establish. Of course a single deep prolongation of endometrium into the muscle, which is not uncommon (see fig. 1), is not sufficient to justify the name of adenomyoma, but such penetrations, both in the body and in the cervix, show us how these growths start and also demonstrate the liability of endometrial tubules to proliferate along chinks in the musculature. The outstanding feature of the adenomyoma is the infiltrative nature of the essential constituents, not a destructive infiltration or lymphatic permeation such as we get in carcinoma but a "worming" of endometrial tubules amongst the loose tissue between muscle bundles. The fibromyomatous constituents are probably due to the irritation produced by the infiltrating gland tubules, and this connective tissue reaction may be out of all proportion to the amount of glandular epithelium. The frequent formation of small cysts is probably due to the contraction of the connective tissue, and such contraction, as perhaps also the endeavours of the uterine muscle to expel the growth, would account for the separation of the tumour from its endometrial connection. We sometimes find intramural adenomyomata in which it is impossible to demonstrate any endometrial connection. They may be extruded into the uterine cavity, or they may become serous-covered pedunculated tumours when they reach a free surface. These we may call "*migratory adenomyomata.*" Finally they may make their way into the broad ligaments or even

into the rectovaginal septum. All these tumours have a histological similarity, and the recognition of the migratory characteristic will serve to account for the presence of adenomyomata outside and apparently unconnected with the uterus. I recently examined a specimen of an adenomyoma situated at the base of the right broad ligament which was still connected to the posterior wall of the uterus low down by a thin pedicle (fig. 2). This connection might quite well have been missed, or it might have been broken off naturally in the course of time, as I believe often happens with these extramural adenomyomata, and the association with the uterus would have been lost. It is this want of demonstrable connection with the uterus that has kept alive the theory of origin from aberrant remains of the Müllerian or Wolffian ducts. It would be idle to deny the occurrence of such embryonic rests, but that they have a greater liability to give rise to tumour formations than normally situated tissues, as Cohnheim held, is a hypothesis which is now discounted. The cells composing them manifestly age just the same as normal cells and the embryonic potentialities for growth depart with their youth.

Adenomyoma—or adenomyositis, as some prefer to call it—of the rectovaginal septum has attracted some attention during the last six years. Cases of this very interesting condition have been reported by several gynæcologists. One observer, Sitzenfrey, in 1909, reported no less than four cases in his own experience occurring within quite a short space of time. When Dr. Cuthbert Lockyer called attention to such a case before this Society last year several other members recalled similar cases. Cullen has recently cited two cases where the condition was not so far advanced. Apart from the adenomyoma at the base of the broad ligament which I have mentioned I have had two cases of septal adenomyoma within a year. They are not therefore uncommon, and their clinical recognition is of much importance. All the authors hitherto have attributed their origin to Müllerian or Wolffian duct remnants, or to serous inclusions. The latter seems to be the favourite theory. Here the supposition is that the endothelial cells metamorphose into columnar epithelial cells, and not only so but they imitate the tubules of the endometrium in a most perfect way. In the two cases that I have seen the septal tumours became excessively painful during menstruation. It stands to reason that if we can imagine a metaplasia of endothelium into glandular epithelium we can persuade ourselves that the cellular stroma in which the tubules are sometimes imbedded, is, though histologically identical with the endometrial stroma, really a chronic inflammatory process. It is clear that the possible endometrial origin has not been rejected without a thought, for in those cases that were fairly carefully investigated the tubules were traceable into the rectal wall and also

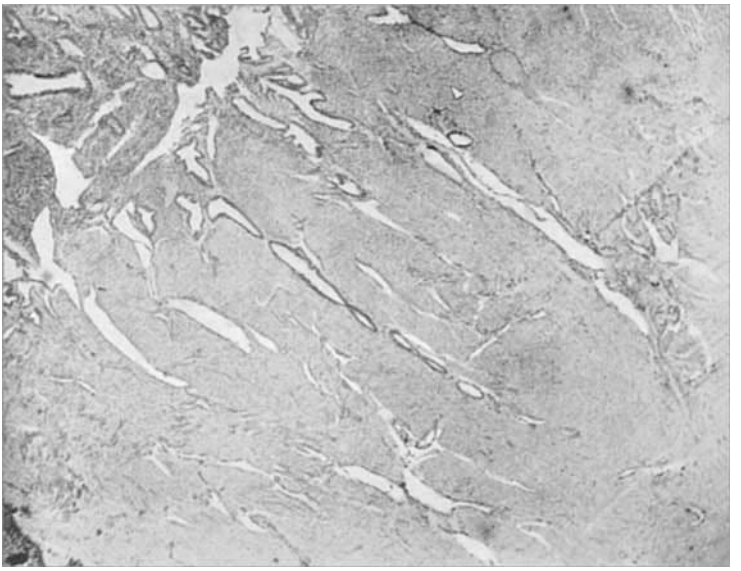

Fig. 1. Micro-photograph showing, in top left-hand corner, normal endometrium, and an endometrial tubule penetrating deep into the uterine wall.

Fig. 2. Micro-photograph of section from an adenomyoma situated at the base of the left broad ligament.

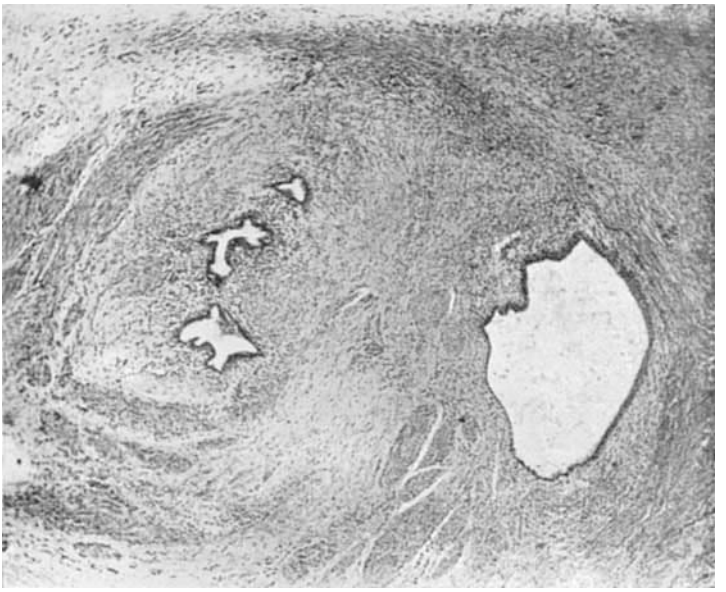

Fig. 3. Micro-photograph of section across the left sacro-uterine ligament in a case of adenomyoma of the recto-vaginal septum.

Fig. 4. Section of wall of sigmoid colon (internal half) in a case of infiltrating adenomyoma of the uterus. The section shows tubules in the circular muscle coat surrounded by cytogenous stroma and also dilated tubules in the submucous layer.

into the uterus, but they were not found to join the endometrium, at least in the sections examined. It was certain they did not arise from the rectal epithelium: hence the suggested origin from "rests" or from the peritoneum of Douglas's pouch. In one of my cases the lower part of the uterus was very hard and thickened and there was a continuation of this hardness along the tissue of the left sacro-uterine ligament, but it stopped short of the rectal wall. The uterus and the backward prolongation were removed under the belief that the condition was a carcinoma of the endocervix infiltrating the sacro-uterine ligament. I do not think carcinoma of the uterus spreads in that direction, and before the specimen was cut I suggested adenomyoma. So it proved. The cervical endometrium had invaded the musculature of the cervix very deeply: right throughout it there were small tense cysts. Unfortunately a continuous section was not taken right into the sacro-uterine prolongation and so I cannot be quite certain of the continuity of the process, but a transverse section across the latter portion showed the typical appearance of adenomyoma (fig. 3) with tubules imbedded in cellular stroma. The other case showed actual invasion of the rectum. Here there were sections of gland tubules found in the submucosal layer of the rectum, in the mixed structure composed of rectal muscle and abundant fibrous tissue of the tumour proper, in the vagina beneath the epithelium, in the substance of the cervix, and scattered here and there right up to a much hypertrophied and cystic endometrium at the level of the internal os. To the naked eye it was evident that the cysts extended through three-quarters of the thickness of the wall. It is rather surprising to find that the tubules are exceedingly sparse, the bulk of the tumour in the septum being composed of dense fibrous tissue. In the attempt to trace the origin of the tubules it was found that they had wandered by a very devious route from the endometrium to the rectovaginal septum, and a single large section would probably have failed to show the connection between them.

But the most interesting case, on which I rely to show both the infiltrating and migratory properties of adenomyoma of the uterus, occurred two years ago. The particulars of the case are as follows: The patient was a lady of 33 under the care of my colleague Mr. Cecil Rowntree. She complained of epigastric pain brought on by any slight exertion. She had long been of a very constipated habit and had been employing rectal irrigation for four months. The menstrual history was unimportant. She complained of pain in the back and had been losing flesh. Enemata were returned in two or three distinct portions. X-ray examination showed marked visceroptosis. Her symptoms were held to point to ptosis of the sigmoid colon, and in July 1912, laparotomy was performed under this diagnosis. Mr. Rowntree found a very long sigmoid loop

lying in Douglas's pouch, the left ovary enlarged and prolapsed, and adhesions between the left broad ligament and the meso-sigmoid. The broad ligament was divided and the ovary removed. The sigmoid loop was pulled up out of the pouch of Douglas without difficulty. On replacing it there was noticed on its antimesenteric border a small puckered area, half an inch in diameter, at the midpoint (the most dependent part) of the loop. Underneath this area there was a very hard nodule in the bowel wall of the size of a Barcelona nut. It seemed from its appearance and the sensation it gave to the finger to be perfectly typical of carcinoma, and such was the opinion of Mr. W. Ernest Miles, who happened to be in the nursing home at the time. Inspection of the posterior wall of the uterus showed a localised thickening or placque of growth under the peritoneum at the junction of the cervix and corpus. On allowing the sigmoid to take up its previous position it was found that the two came into contact. The placque, flat, circular, hardly raised from the surface, a few millimetres in thickness, was considered to be an implantation of cancer from the sigmoid. Under such circumstances a radical operation had to be postponed until the patient's relatives were informed. The uterine placque was removed, and when I examined it I found it to be an adenomyoma. Permission was given for a local resection of the sigmoid growth, but at the operation before proceeding with the resection Mr. Rowntree opened into the bowel beyond the margins of the growth and found that the epithelial layer was quite intact. A small portion of bowel was therefore removed and end-to-end anastomosis performed. The specimen showed a small puckered area on the serous surface with slight hæmorrhage: cutting through this we found a white fibrous growth with rather indefinite margins apparently extending right up to the mucous layer but not involving it. On microscopic examination it is evident (fig. 4) that the outermost part is composed of fibrous tissue in which are found gland tubules surrounded for the most part by a small amount of cellular stroma. These tubules spread out into the muscular coat, which is much distorted: they reach right up to the submucous coat, and some sections show them actually in the mucous layer, from the tubules of which they can be distinguished by the absence of goblet cells and mucinous material. The raggedness of the little puckered area on the serous coat and the presence of hæmorrhagic areas in that situation show that it has lately been adherent to something else and that the adhesion has been broken. The sequence of events almost certainly is as follows: An adenomyoma having started from the endometrium migrated, or was extruded, through the wall posteriorly: owing to hæmorrhage occurring during a menstrual period the serous surface was broken: the loaded and dependent sigmoid colon

became adherent to this : the glandular constituents infiltrated the wall of the sigmoid : the adhesion became attenuated by movements of the intestine and at operation the slender adhesion was broken leaving a discoid portion in the uterus and an abraded area in the colon. Supposing a greater length of time had elapsed the scar on the sigmoid might have healed over and the evidence of connection between the two would have been quite lost. As it is, it serves to show how the tumours infiltrate and migrate, and we need not invoke the theory of rest-cell origin to explain the occurrence of such tumours in situations at a distance from the endometrium.