

## A METHOD FOR REDUCING THE SIZE OF THE UTERUS IN VAGINAL HYSTERECTOMY\*

A. F. LASH, M.D., PH.D., CHICAGO, ILL.

*(From the Department of Obstetrics and Gynecology, University of Illinois, College of Medicine and The Cook County Hospital)*

VAGINAL hysterectomy may be performed by any one of many techniques. A large uterus is usually reduced in size by splitting in two or by morcellation and then removing it piecemeal. In the course of these procedures, it was found that amputating the cervix facilitated the turning of the corpus. Also in a large corpus (i.e., multiple fibroids), it was found that a good part of the corpus could be coned out with the cervix. However, there was the danger of opening an infected cervix or opening the uterine cavity in which a carcinoma might be present. Since carcinoma of the corpus or isthmus of the uterus may be associated with fibroids (0.5 to 4.4 per cent, according to different observers; 10 per cent over the age of 50 according to Bland-Sutton), I developed a procedure to decrease the size of the uterus without opening the cervical canal or the cavity of the corpus. The new procedure is helpful not only for a large uterus but also for carcinoma of the corpus or isthmus associated with fibroids and in unsuspected chronic pyometra secondary to stricture of the cervix.

In a consideration of the technique of vaginal hysterectomy, it is of interest to relate its historical development. No mention of vaginal hysterectomy was made in

\*Presented at a meeting of the Chicago Gynecological Society, March 21, 1941.

ancient gynecology until the time of Soranus who practiced in Rome from A.D. 98 to 138. He suggested that if part or all of the uterus became black, because it remained prolapsed for a considerable time, it should be resected partially or entirely. Paulus Aegineta (A.D. 625 to 696), who appeared to be the first professional man midwife, advocated the operation for irreducible inversion. The next reference to the operation was for ulcerated prolapse by Albucasis the Arabian (1073 to 1106). No details of the procedures were given. There is no mention of it during the Renaissance.

In the modern period, Andreas A. Cruce, of Granada, performed a hysterectomy in 1560 with a cautery iron for a carcinoma in a prolapsed uterus. This method was used for the treatment of carcinoma of the cervix for quite some time. In 1813 C. J. M. Langenbeck performed a vaginal hysterectomy by enucleating a carcinomatous prolapsed uterus without opening the peritoneum. Langenbeck published the first monograph on the subject in 1818. Following this work came Sauter's description of dividing the broad ligaments and performing a vaginal hysterectomy in 1822. Blundell in 1828 and Recamier in 1829 published their experiences. J. C. Warren in 1829 apparently did the first vaginal hysterectomy in America. Many failures followed, probably due to imperfect asepsis and lack of anesthetics. Only few cases were found in the literature until W. A. Freund in 1878 described his technique for vaginal hysterectomy. Freund's technique is still practiced today and has served as the basis for all modifications of vaginal hysterectomy. Czerny, Liebman, Hegar, Kaltenbach, and Martin played an important part in developing the earlier technique. In the present century Kelly, Schuchardt, Schauta, Adler, and their followers are the main exponents. Doyen (1859-1916) who performed the operation by the use of clamps said, "No man can call himself a gynecologist until he can perform a vaginal hysterectomy," and "that the gynecologist shall be capable of applying as faultless a technique per vaginam as he would if performing per abdomen." Today Kennedy, of Philadelphia, still champions the clamp method advocated by Price.

#### AUTHOR'S TECHNIQUE OF VAGINAL HYSTERECTOMY

1. Usual preoperative preparation of 1 per cent iodine douche and soapsuds enema night before and morning of operation.
2. Morphine ( $\frac{1}{6}$  gr.) and scopolamine ( $\frac{1}{150}$  gr.) one and one-half hours and three-quarters of an hour before operation if no change in pulse (above 120) and respiration (below 12).
3. Anesthesia: ether, ethylene, cyclopropane or local (pudendal block and infiltration 1 per cent novocaine).
4. Lithotomy position; vaginal preparation of soap and water wash, iodination and catheterization. Buttocks four to six inches over edge of table.
5. Weighted speculum inserted into the vagina. Cervix grasped with two vulsella and firmly pulled down. Lateral retraction. 2.0 c.c. of pituitrin (S) injected into the cervix.
6. Circular incision around portio guided by estimate of position of bladder and depth of posterior cul-de-sac. Vaginal wall wiped back with gauze exposing anterior and posterior peritoneal reflections.
7. Posterior peritoneal sac is opened between uterosacral ligaments and sutured to the vaginal wall with three fine (0) catgut sutures which are kept long on a Kocher forceps (Fig. 1).
8. Each uterosacral and part of the paracervical ligaments are clamped, cut, and ligated (No. 2 chromic catgut), and then sutured into the adjacent vaginal wall (Fig. 2).
9. Anterior peritoneal sac is opened between bladder pillars and the edge is sutured to the vaginal wall with three fine (0) catgut sutures

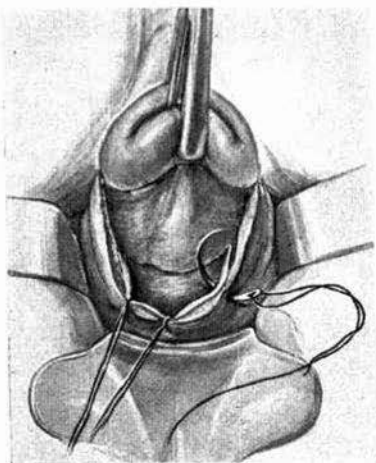


Fig. 1.

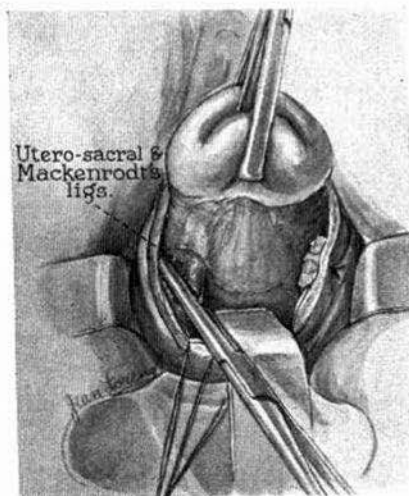


Fig. 2.

Fig. 1.—Modified vaginal hysterectomy: Posterior cul-de-sac has been opened and the posterior peritoneum is sutured to the posterior vaginal wall. The same procedure is carried out anteriorly, so that the anterior peritoneum is sutured to the anterior vaginal wall.

Fig. 2.—Modified vaginal hysterectomy: The uterosacral and the base of the Mackenrodt's ligaments are clamped, cut, and sutured to the lateral wall of the vaginal vault on each side.

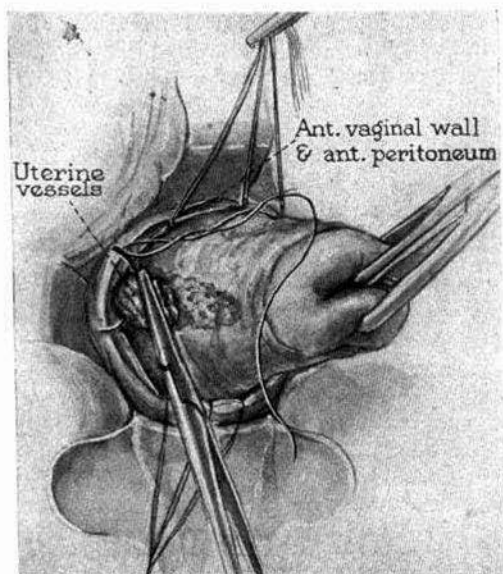


Fig. 3.—Modified vaginal hysterectomy: The bladder is retracted as well as the posterior peritoneum. The uterine vessels are clamped, cut, and ligated.



which are held long by a Kocher forceps. A long narrow retractor raises the bladder.

10. The uterine vessels are visualized, clamped, cut, and ligated on each side (No. 1 or 2 chromic catgut). A long narrow retractor is inserted into the posterior cul-de-sac (Fig. 3).

11. An incision is started in the uterine wall just medially to the right uterine vessels and continued toward the left side and carried around. As the cervix is pulled down, the myometrium is cut so that the whole endometrial cavity with a thick layer of myometrium is removed with the cervix. Only the tubal lumina are traversed (Fig. 4).

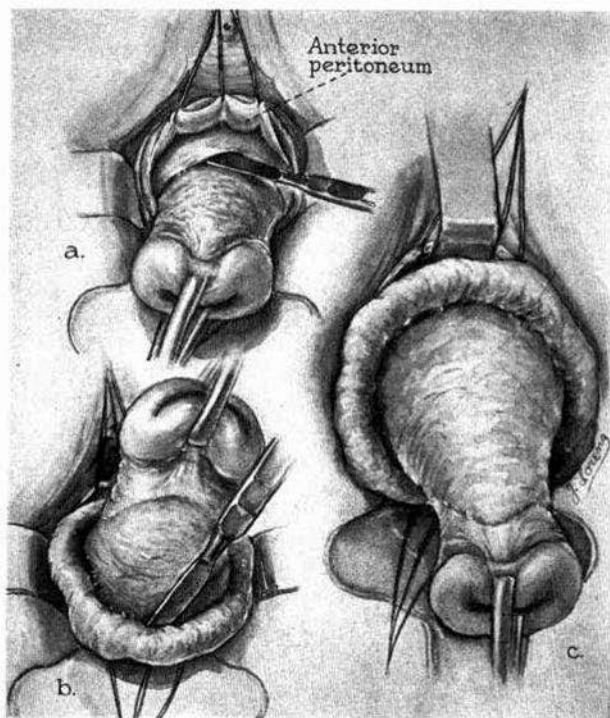


Fig. 4.—Modified vaginal hysterectomy: (a) The incision is now started medially to the point where the vessels have been ligated and encircles the cervix. (b) The cervix is pulled firmly downward and then upward as the major portion of the myometrium is shelled-out, leaving a capsule. (c) The major portion of the myometrium with its unopened endometrial cavity comes away.

12. The fundus is brought forward through the anterior cul-de-sac (Fig. 5), or if there are many fibroids, morecellation may be necessary. The round ligaments, tubes, and uteroovarian ligaments on both sides are clamped, cut and ligated with long No. 2 chromic catgut sutures which are held. The fundus is thus removed. The adnexa are inspected for possible pathology. The uterine and cervical cavities are opened by an interne or an unscrubbed nurse to allow the operator to inspect

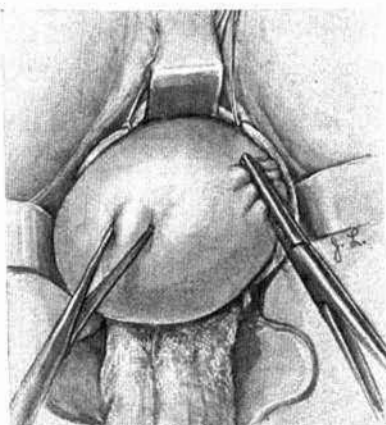


Fig. 5.—Modified vaginal hysterectomy: The remaining capsule of myometrium is brought forward exposing the tube, the round and uteroovarian ligaments, which are clamped on each side; the fundal capsule is removed; the tubes and ovaries are inspected. The uterine and cervical cavities are exposed by another person and the operator then inspects the cavities for carcinoma as the specimen is held up for his observation. If no carcinoma is found, the ligament stumps are ligated.

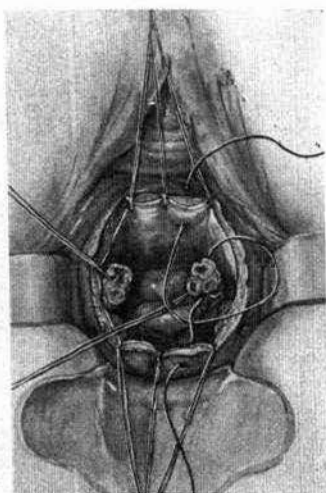


Fig. 6.

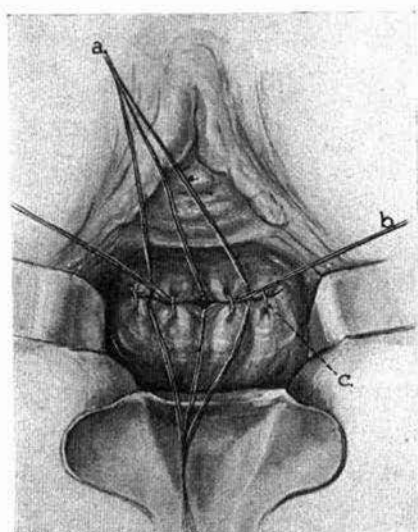


Fig. 7.

Fig. 6.—Modified vaginal hysterectomy: The ligament stumps are fixed in the midline of the vaginal vault, allowing only a small space between them. The stumps are, therefore, extraperitoneal, pulling up and supporting the central portion of the vagina and in most instances lengthening the vagina.

Fig. 7.—Modified vaginal hysterectomy: The lateral portions of the vault are closed with interrupted sutures. An iodoform gauze drain is inserted in the central opening of the vault. All sutures are now cut.

the endometrium. If carcinoma is present, the adnexa are excised by clamping the infundibulopelvic ligament, cutting, and ligating. The round ligaments alone are then utilized for fixation into the vaginal vault. If there is no carcinoma in the uterus or pathology in the adnexa each tube with its broad ligament, the round and uteroovarian ligaments are ligated (No. 2 chromic catgut).

13. The anterior vaginal wall with its peritoneum is sutured to the posterior wall with its peritoneum including the ligaments (Fig. 6). The lateral parts of the vaginal wall are sutured with one or two interrupted No. 1 chromic catgut suture. Thus, the ligaments and vessel stumps are extraperitoneal (Fig. 7). An iodoform gauze is inserted partly into the small peritoneal opening between the ligament stumps. The gauze is allowed to remain in place for forty-eight hours.

14. Any anterior or posterior plastic repair may now be done in the usual way.

#### POSTOPERATIVE CARE

1. One thousand cubic centimeters of 10 per cent glucose in normal saline solution intravenously.

2. Morphine sulfate,  $\frac{1}{6}$  gr. as necessary for forty-eight hours, then codeine sulfate and luminal for pain.

3. Fluids after nausea.

4. Catheterize every eight hours, or if patient urinates in small amounts, catheterize for residual urine every twelve hours.

5. Soft diet on second day and then solid food is added as indicated. Oil retention enema on third night followed by warm tap water enema the following morning. Mineral oil is given twice a day.

6. Patient is out of bed on the eighth day, walks on the ninth and may go home on tenth or twelfth day.

#### COMPLICATIONS

Low grade infections in the vault of the vagina as indicated by fever and foul seropurulent vaginal discharge have been observed which have responded to low pressure antiseptic douches. No marked infection such as peritonitis or pelvic abscess and no postoperative hemorrhages either immediate or late have been observed. In the subsequent postoperative examination granulation tissue in the wound or rarely a prolapsed fimbriated end of a tube have been seen.

The advantages of vaginal hysterectomy are: First, less shock, because of less exposure of the peritoneal cavity, and shorter operating time; second, no opening or closing of the abdominal wall, especially in an obese individual; third, no abdominal sear with risk of ventral postoperative hernia or evisceration; fourth, opportunity to overcome cystocele, rectocele, or enterocele; fifth, postoperative care is simple; sixth, drainage is better; seventh, convalescence is rapid and, therefore, shorter hospitalization. The contraindications are: First, fixation of the uterus due to large fibroids (larger than twelve weeks' pregnancy); second, pelvic inflammatory disease or previous pelvic operations; third, malignant disease of the corpus uteri in nullipara; and fourth, necessity for abdominal exploration.



The technique described by me adds to the advantages of vaginal hysterectomy by enabling one to remove large uteri, by preventing contamination of the peritoneal cavity, and by avoiding the spill of carcinomatous tissue from an unsuspected carcinoma of the uterus.

#### REFERENCES

- (1) *Datnow, M.*: Proc. Royal Soc. Med. 127: 761, 1934. (2) *Green-Armyltage, V. B.*: J. Obst. & Gynaec. Brit. Emp. 46: 848, 1939. (3) *Kennedy, J. W.*: Practical Surgery of the Abdominal and Pelvic Regions, Philadelphia, 1934, F. A. Davis Company. (4) *Lynch, F. W., and Maxwell, A. F.*: Pelvic Neoplasms, New York, 1931, D. Appleton-Century Co. (5) *McKay, W. J. S.*: The History of Ancient Gynecology, London, 1901, Bailliere, Tynndall & Cox.

#### DISCUSSION

**DR. N. SPROAT HEANEY.**—In the case described in the film, this procedure seemed to facilitate the hysterectomy greatly as the operator was enabled thereby to exert continuous traction and remove the uterus more rapidly than if the usual technique of morcellation had been followed. For this purpose I believe that his method is of distinct advantage. I do not believe that it is of importance in avoiding contamination from a carcinomatous or infected endometrium, particularly in view of the fact that he did not exercise the common precaution of blocking the cervical canal by sutures or clamps to prevent a spill through the cervical opening. Pulling down continuously as he did, increases the chance of escape of any infected material that may be in the uterine cavity, through the cervical canal. I wonder how often Dr. Lash is able to remove a block of the uterus containing the endometrial cavity without entering the endometrial cavity, since in fibroids of any size the uterine cavity is so tortuous that its location cannot be determined.

**DR. H. O. JONES.**—Dr. Lash removes the endometrial cavity but he leaves a certain amount of endometrial tissue between the Fallopian tube and the cavity of the uterus. As we know from Sampson's work this tissue has a proliferative activity, and it seems to me that it would be very dangerous to leave that portion of the Fallopian tube in.

Like Dr. Heaney, I cannot see any advantage and I can see many disadvantages in the use of this procedure.

**DR. FREDERICK H. FALLS.**—Dr. Lash has not pointed out that a similar operation of this kind may save difficulty in certain vaginal hysterectomies which cannot be done in a routine manner because of certain complications which preceded the indication for the operation, such as pelvic inflammatory disease. We have done a number of operations with a technique similar to that described by Dr. Lash in patients who had had an interposition operation and in whom the uterus had begun to show fibroid or malignant degeneration. One of our chief concerns is to remove the uterus without injury to the bladder. We take out practically all of the myometrium and do an extraperitoneal vaginal hysterectomy. In another group of patients which special indications created we have done vaginal hysterectomies on uteri that have had previous ventral suspensions. We have used this same technique Dr. Lash has shown and then left a small portion attached to the abdominal wall.

To avoid contamination, instead of sewing the cervix we pull it down and with a cautery cook the interior of the uterus. By doing that we thoroughly sterilize the cavity of the uterus, and then we can do what we want with the uterus. I do not think it is good technique to put iodoform gauze through the cervix of the uterus.

**DR. W. H. RUBOVITS.**—I can see some definite advantages in the operation that Dr. Lash performs. There is a definite advantage to reducing the size of the large uterus which we formerly did, either by splitting the uterus in the midline and removing one-half of the uterus at a time or by some form of morcellation. I can see no better way than the operation Dr. Lash describes of cutting away a

large portion of the uterus through the avascular area which will remove the endometrial cavity and a large block of the fibroid uterus.

DR. LASH (closing).—The suggestion of closing the cervix is an excellent one. I have tried to avoid the necessity of that by putting iodized gauze into the canal and using a volsellum. I do not use this operation in an infantile uterus, but in a large uterus. Whenever it is possible, the uterus is removed intact.

The reason we took out this uterus in the illustrated case, was that the patient, a 44-year-old woman, was bleeding and had multiple fibroids and large cystic ovaries.

It is true that we have to traverse the tubal cavity in removing the endometrial cavity, but we try to get the major portion of the myometrium in removing the myometrium with the endometrium. Two cubic centimeters of pituitrin will make the myometrium practically bloodless.

I would like to reiterate that this operation is not to be done on the normal uterus where the corpus can be removed in toto. It is the uterus the size of a twelve to fourteen weeks' pregnancy that should be removed this way. In certain instances, as Dr. Falls brought out, we can really remove the uterus in the presence of inflammatory disease where there are some adhesions present.

---