

A CLASSIFICATION OF FORCEPS OPERATIONS ACCORDING TO STATION OF HEAD IN PELVIS

(Including Results in 3,883 Forceps Deliveries)

By EDWARD H. DENNEN, M.D., New York, N. Y.

THE system of classification now in use describing the station of the head in the pelvis when forceps are applied is far from satisfactory.

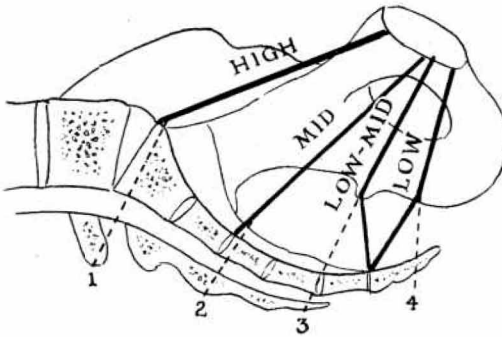
The long distance from low to mid pelvis and the short distance from mid to high pelvis have led to numerous errors in classification. The logical approach to the problem is to relate the station of the head (the biparietal diameter) to the four major planes of the pelvis (Fig. No. 1). They are: the plane of the inlet (superior straight) which is bounded by the promontory of the sacrum and the upper, inner border of the symphysis; the plane of greatest pelvic dimensions (mid-plane) which extends between the middle of the inner border of the symphysis and the junction of the second and third sacral vertebrae; the plane of least pelvic dimensions (plane of ischial spines) which is bounded antero-posteriorly by the lower, inner border of the symphysis and the sacrococcygeal joint, and laterally by the ischial spines; the plane of the outlet, quadrilateral in shape, which is bounded by the sacrococcygeal joint, the ischial tuberosities and the inferior border of the symphysis. The corresponding operative deliveries should be entitled high, mid, low-mid and low forceps.

A *high* forceps (Fig. No. 2) is one which the biparietal diameter is in the inlet or superior straight of the pelvis and the leading bony point of the head is just above the plane of the ischial spines. Anything higher should be labeled a forceps to an unengaged head.

A *mid* forceps is one done on a head, the leading bony part of which is at or just below the plane of the ischial spines with the biparietal diameter below the superior straight. The head nearly fills the hollow of the sacrum.

A *low mid* forceps is one in which the biparietal diameter is at or below the plane of the ischial spines with the leading point within a finger's breadth of the perineum between contractions. The head completely fills the hollow of the sacrum.

A *low* forceps is one in which the bony head is on the perineum between contractions and is visible during a contraction. The biparietal diameter is judged to be below the plane of the ischial spines



1. Plane of Inlet
2. Plane of greatest pelvic dimensions
3. Plane of least pelvic dimensions
4. Plane of Outlet

Figure 1

with the sagittal suture in or nearly coinciding with the antero-posterior diameter of the outlet. This is in agreement with the definition of low forceps by Eastman, Titus, McCormick and Greenhill.

The average case fits into one of these categories. However, exceptions must be made for extreme molding, extension and asynclitism

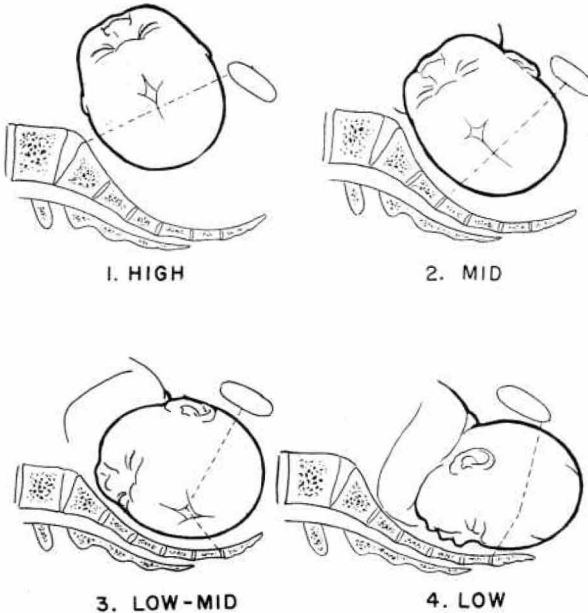
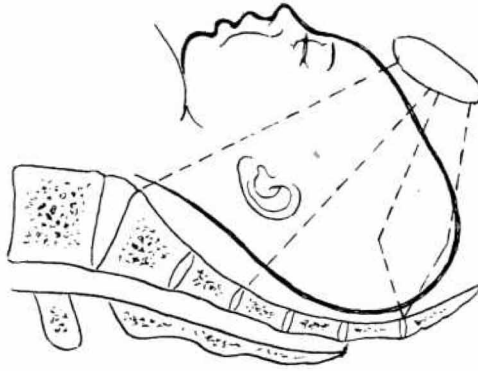


Figure 2

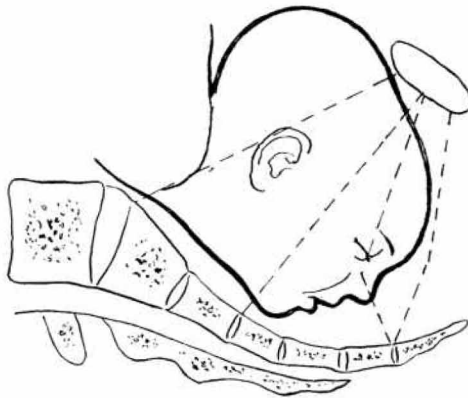


EXTREME MOULDING MID O.P.

Figure 3

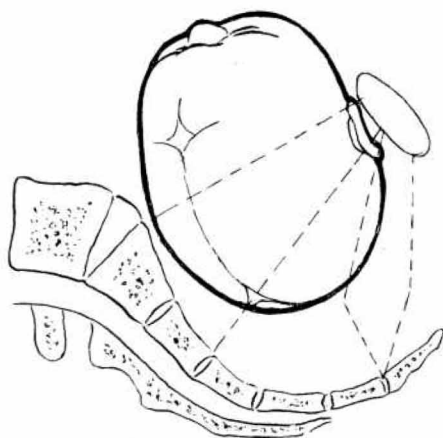
and for deformities of the pelvis which predispose to these conditions. In such instances, the biparietal diameter usually is at a higher level in its relationship to the leading point of the head than in the average case. Unless these variable factors are taken into consideration, errors in diagnosis of the exact station are frequent.

Extreme moulding lengthens the long axis of the head. Hence the biparietal diameter is at a correspondingly greater distance from the leading point (Fig. No. 3). The estimation of this distance is of the greatest importance since the biparietal diameter is the widest diameter of the foetal head which must pass through the maternal pelvis, and its level designates the true station of the head.



HIGH POST. CHIN

Figure 4



ANT. PARIETAL PRESENTATION HIGH L.O.T.

Figure 5

With the leading point at the plane of the ischial spines, the biparietal diameter may be at the inlet. Consequently, what is thought to be the head in mid station is in reality in high station. Also, in cases with the leading point on the perineum, the biparietal diameter may be at or above the ischial spines. What is often thought to be an easy low forceps is later proved to be a difficult delivery of a head at or above the low-mid station.

Faulty attitudes such as varying degrees of extension of the head, including the extremes of brow and face presentation, and the abnormal attitude of asynclitism influence the level of the biparietal diameter with relation to the leading point.

In extensions of the head, the biparietal diameter is farther from the leading point than in normal occipital presentations (Fig. No. 4). Hence the station of the biparietal diameter is higher than would be expected in an occiput with the leading point at the same level. The greater the extension, the more the variation. In asynclitism, either the anterior or the posterior parietal bone is presenting (Fig. No. 5). Therefore, one extremity of the biparietal is considerably lower than the other. The actual station of the head depends upon the level of the "pivot point" which is the midpoint of the biparietal diameter. The location of this point must be judged by the degree of asynclitism and the level of the leading point. The more asynclitic the head, the

greater the chance of error in diagnosis of station. One is apt to consider the head at a lower level than is the case.

Clinically this is more frequent in asynclitism with the anterior parietal bone well under the symphysis, and the hollow of the sacrum empty. When the posterior parietal bone presents, the anterior pelvis is usually empty, since the anterior parietal bone overrides the symphysis, and can be palpated above it.

The degree of asynclitism can best be determined by the shape and the location of the sagittal suture. The greater the degree of asynclitism, the more the shape of the sagittal suture changes from a straight line to the shape of the letter "U". With the anterior parietal bone presenting, the "U" is upright and the most dependent portion of the "U" becomes closer to the sacrum, and farther away from the symphysis as the asynclitism increases. In a posterior parietal bone presentation, the "U" is inverted and the superior point of its base is closer to the symphysis than to the sacrum.

Deformities of the pelvis may predispose to and accentuate molding, extensions and asynclitism. These deformities may involve any of the major planes of the pelvis and consequently, affect the accuracy of the diagnosis of station.

At the inlet or high plane, molding is common in small gynecoid and android pelves, especially with posterior positions. Asynclitism and extensions, even to the degree of face presentations, are frequently found in platypelloid pelves. With the head arrested at this level, the common mistake is to consider the head engaged when in reality the biparietal is above the inlet.

Deformities of the plane of greatest pelvic dimensions or mid plane, carry with them similar factors as those of the inlet, and affect molding, extensions and asynclitism. A transverse contraction in the anthropoid and android types frequently leads to a posterior position with more than average molding. A contracted anteroposterior diameter, due to a straight sacrum or a forward jutting sacral vertebra, leads to extension and asynclitism. Hence most of those cases should be classed as high instead of mid, as the biparietal diameter is usually at the inlet. This knowledge should influence the operator to avoid the dangerous high forceps operation.

In the plane of least pelvic dimensions, the plane of the ischial spines, or low mid-plane, the greatest percentage of dystocias is encountered. The type of pelvis that carries with it the most difficulty at this level is the android. Here the molding is accentuated. It may be so extreme as to have the leading point touching the perineum when the biparietal diameter is still above the ischial spines. The common error in diagnosis in such cases is to label the operation low forceps

instead of mid. In this extreme situation, with the biparietal above the spines, the operation cannot be classed even as low-mid.

The deformities of the low plane or outlet, particularly those with a funnel outlet, predispose to posterior positions and excessive molding. Here again, if the diagnosis of station were made on the leading point alone, the delivery would be classed as a low forceps. When correctly made on the biparietal diameter it is a low-mid forceps.

Determination of the exact level of the biparietal diameter may be difficult to make except on certain unengaged heads. In all complicated cases a vaginal examination is essential in determining the true picture. It is important that phrase "at the spines" is correctly understood. When a leading point is at the spines, it has reached a plane that includes the ischial spines laterally and the sacrococcygeal junction posteriorly. In such a situation the hollow of the sacrum is nearly filled by the head. The common error is to feed the foetal head in the anterior part of the pelvis, and to consider the vertex at the spines without investigating further to see whether the hollow of the sacrum is empty.

The difference may be between a head that is in mid pelvis and one that is high or unengaged. X-ray study in labor is a valuable aid especially in complicated cases. A sideview gives the exact level of the biparietal diameter. Also, it may show a previously unrecognized deformity of the sacrum to be the cause of dystocia. In the average case it can be assumed that the biparietal diameter is located at a certain level, depending on the level of the leading point, as has been indicated. But in cases with extreme molding, abnormal attitudes, and in deformed pelvis predisposing to these conditions, it automatically should be placed at least at the next higher plane.

The advantages of this method are many. It is a definite means of classification and is self explanatory, in that the stations of the head correspond with the four major planes of the pelvis and the operative deliveries from these stations are similarly named. Honest and human errors in diagnosis of station are reduced to a minimum.

Attempts at a forceps delivery on the unengaged head and on all but the extremely rare high head can be avoided. At the same time, it is realized that visual evidence of the foetal scalp at the perineum does not necessarily mean an easy "low" forceps delivery. Without a systematized classification, there is a great void between the low forceps, in which the head is visible, and the "mid" forceps which may be anything from a simple low-mid forceps to a complicated delivery of a head at the inlet. This is one reason why the valuable true "mid" forceps operation has fallen into discredit.

This method of classification has been used routinely at the New York Polyclinic Hospital since 1940 on more than 7,000 forceps deliveries. The 3,883 forceps operations done in the five-year period of 1946 through 1950 have been classified and the results in each group are shown in the following chart (Fig. No. 6). Also, the causes of the 38 foetal and infant deaths have been similarly classified (Fig. No. 7).

MORTALITY AND MORBIDITY (1946-1950)

According to Type of Operation in 3,883 Forceps Deliveries

Forceps	Total Infant Mortality	Corrected	Maternal Mortality	Morbidity*
High - 5	0	0	0	0
Mid - 262	8 or 3.05%	5 or 1.90%	0	2 or 0.76%
Low Mid - 1,546	17 or 1.1 %	11 or 0.71%	0	12 or 0.77%
Low - 2,070	13 or 0.62%	6 or 0.29%	1 (prem. sep plac.)	10 or 0.47%
Total - 3,883	38 or 0.97%	22 or 0.56%	1	24 or 0.62%

(in 6,544 viable cases) (minus 16 macerated (13 extra-*puerperal*) or monsters) *A.C.S. standard

CAUSES OF INFANT DEATHS IN 3,883 FORCEPS DELIVERIES

High Forceps - 0		
Mid Forceps - 8		Autopsy
Asphyxia (cord x neck 2)	3	3
Intercranial Injury	1	1
Prematurity-pneumonia	1	1
Congenital Anomalies	3	3
(diaphragmatic hernia, hydrocephalus, rudimentary Siamese twin)		
Low-Mid Forceps - 17		
Asphyxia (cord prolapsed 3, impacted shoulder 1)	6	5
Intercranial Injury	2	2
Atelectasis (prematurity 2)	3	3
Diabetes (macerated 2)	2	2
Congenital Anomalies	4	4
(Multiple Deformities, polycystic kidneys, hydrocephalus, erythroblastosis)		
Low Forceps - 13		
Asphyxia (cord x neck 4, prolapsed 2; macerated 4)	7	5
Prematurity (atelectasis 1)	2	2
Atelectasis	1	1
Congenital Anomalies	3	3
(Cardiac, absence of kidneys, erythroblastosis)		
	38	35

SUMMARY

Forceps operations should be classified in four groups, according to the relationship of the station of the head to the four major planes of the pelvis, namely: High Forceps at the Plane of Inlet; Mid Forceps at the Plane of Greatest Pelvic Dimensions; Low-Mid Forceps at the Plane of Least Pelvic Dimensions; Low Forceps at the Plane of Outlet.

In the average case, the station of the head can be determined by combining the clinical estimation of the levels of the leading bony point of the head and the biparietal diameter. Exceptions occur in excessive molding, faulty attitudes, and certain deformities of the pelvis. Therefore, correction for station must be made, at least, to the next higher plane than in the average case. The true station corresponds to the level of the biparietal diameter and in complicated cases is best determined by a lateral x-ray view of the pelvis.

With the rarely indicated High Forceps clearly defined and the long distance between Mid and Low pelvis divided into Low-Mid and Low, a more accurate picture is shown of both the type of operation performed and the results of operations at the various stations.

A five-year series of 3,883 consecutive forceps deliveries is classified according to this method, and the results in each group are shown.

DISCUSSION

DR. ARTHUR B. HUNT, Rochester, Minnesota.—From perusal of the literature on the classifications of forceps operations there seems to emerge three classifications. One, present in texts published up until the last five years and in some current texts such as Mengert's holds roughly as follows: all agree on the floating and high forceps definitions as Dr. Dennen has given them. Midforceps—application to a fetal head that has just engaged but wherein no further descent has occurred, the true presenting part being at or possibly slightly below the ischial spines. Low forceps—application of the forceps to a head whose presenting part occupies any plane from definitely below the ischial spines (station plus one) to but not on the perineum. Outlet forceps—application of the forceps to a head which distends to perineum so as to be visible at the introitus and a head that has rotated well anteriorly.

The second classification agrees also as to what determines a mid forceps operation but eliminates the term outlet forceps and substitutes for it low forceps, meaning the application to a head crowning in the anterior position on the perineum. Some who hold to this classification use the terms low and outlet forceps synonymously.

The third classification follows the second except that a mid forceps operation is any forceps application to a head descended to any plane from mere engagement until it has approached but is not at a station where the bony head is on the perineum between contractions and is visible and anterior with a contraction.

Personally, I would favor the first classification retaining the term mid forceps for one applied to a head whose presenting part is at or slightly below the spines;

a low forceps for one applied from this point down until the conditions described as outlet forceps are obtained for the following reasons: a true mid forceps initiated with the lowest part of the head at or only slightly below the spines is frequently a formidable forceps extraction, especially if indicated when the head has not rotated anteriorly. Because of this, forceps application at this level should have a distinct name and the appellation of mid forceps being almost universally applied to it in the past I therefore, can see only confusion arising by now using this term for applications of the forceps to the head at lower stations in the pelvis. Agreement is already being expressed over the opinion that the number of forceps deliveries of this more difficult type should and are being reduced by applying cesarean section to such cases where study shows that actual disproportion exists. In spite of this, cases requiring delivery by forceps at this pelvic level will arise in the absence of true disproportion. To include as a "mid forceps" one where the head is well rotated anteriorly and just off the pelvic floor includes those forceps deliveries where in difficulty in extraction is not comparable to the forceps application in the neighborhood of the ischial spines especially in the posterior position. One is fraught with the possibility of more fetal and maternal trauma than the other. Reports of series of cases using two divergent definitions for the term mid forceps may produce an unfair basis for comparisons and indeed there is some suggestion that this is already taking place. Dr. Dennen has appreciated this difficulty when he stated, "without a systematized classification there is a great void between the low forceps in which the head is visible and the mid forceps, which may mean anything from a simple low mid forceps to a complicated delivery of a head at the inlet." Dr. Dennen's classification of forceps operations seems to me to have much in its favor since it clearly defines various forceps extractions at a sufficient number of levels in descent of the head through the pelvis. After all, the station of the head still probably is the best single index of the difficulty and trauma that may be involved in forceps extraction. If he would only be willing to substitute the term outlet forceps for his term low forceps and delete the suffix mid from his term low-mid forceps, I could accept it wholeheartedly one hundred per cent. The classification has much to recommend it as it stands. The chief desirability at present in classifying forceps operations as I see it is that the three types of forceps extractions should be clearly delineated; namely, first, those with the presenting part at or slightly below the ischial spines; secondly, those wherein the presenting part is from this point on down to the perineum; and thirdly, those wherein the presenting part is visible at the vulva with the occiput anterior. What we call these three various types of forceps extractions is of less importance than that we uniformly agree to some terminology that applies when we employ forceps to the head in these three levels of the pelvis. Dr. Dennen has clearly shown from a considerable experience that these three levels of descent of the head do affect fetal results adversely as we ascend the pelvis. He reports nearly 2.0 per cent corrected fetal mortality for his mid forceps; .7 per cent for low-mid forceps; and only .3 per cent for low forceps. Our own experience is in agreement with that of the essayist. In 86 very difficult forceps deliveries that we collected from our service in a 17-year period occurring among about 3,000 operative deliveries, sixty deliveries (or over 70%) were the type that Dr. Dennen and we would call mid forceps and 18 (or about 21%) were what Dr. Dennen has designated as low-mid forceps. There was one of the extreme outlet type.

In two recent excellent textbooks I find that the term mid forceps has been extended to include forceps applied to fetal heads much lower in the pelvis than

at the level of the ischial spines. I wonder if their change in definition has not done us a bit of disservice in being too inclusive with the term mid forceps and thus given rise to confusion and difficulty in comparing results of forceps statistics from various groups.

To me (and to many of my colleagues in various places when discussing it with them) it seems more rational to apply the term low forceps to those applied in the areas of the pelvis attained by the presenting part from say, a cm. below the ischial spines down to but not on the perineum and reserve the term outlet forceps for those wherein the head is bulging the perineum and is visible in the anterior-posterior position at the vulva. To signify this latter type of forceps delivery which is more often than not an elective procedure of great simplicity by the term low forceps operation seems a bit unnecessary and over dramatic. When the head is rapidly visible at the vulva in the A-P position the greatest diameter of the head is often through or nearly through the bony pelvis. I would be greatly surprised and disappointed if anyone in this group could not very readily teach the intern of average intelligence and manual dexterity how to expertly perform this simple extraction. Although I do not find it necessary to perform routine elective forceps delivery I think the only significant danger in it is that an occasional obstetrician chronically impatient of delivery sneaks up successively higher and higher in the pelvis to effect elective delivery until he eventually has cause to regret this folly.

Dr. Dennen has gone into some detail with important comments on how one should adjust and compensate for such pathologic variants of labor as excessive moulding, deflexion and asynclitism and in my limited experience I would emphatically agree that his remarks are both sound and practical. When the paper is published we can read these comments with profit.

DR. L. MARSHALL HARRIS, Bethesda, Maryland.—Dr. Dennen's paper is a valuable contribution to the study and practice of obstetrics, not only because of the time and the study devoted to the subject, with the series of cases compiled from his experience, but also because it clarifies an existing misunderstanding, especially among residents and internes in obstetrics in the matter of definition of the station of the fetal head in its relation to the anatomical planes of the maternal pelvis.

Most of us are cognizant of the efforts and accomplishments of Doctors Eastman, Titus, Greenhill, Mengert and others during a recent meeting of this association to standardize a classification of forceps operations along the line presented by Dr. Dennen for publication in their revised texts to assist in the correction of some of the erroneous interpretations of diagnosis and operative procedures.

In view of the comparatively large number of cases, (Dr. Dennen has presented 1,546 of 3,883 cases in his series), delivered by low-mid forceps, it seems rather obvious this addition to the old classification is justified. It seems also that the revised classification, so well described and demonstrated by the author, and advanced and published by Doctor Eastman and others, is an outstanding contribution to obstetric teaching and practice.

In addition to the pelvic factors discussed in the paper it is possible that certain fetal abnormalities, such as anencephalus, hydrocephalus and others may offer a problem in the accurate diagnosis of station of the head in relation to the pelvic planes. Here, as pointed out by Doctor Dennen, the x-ray may serve as an important adjunct in diagnosis.

The author has discussed the maternal and fetal hazards incident to improper diagnosis of station and consequent faulty applications. Experience has shown that the resident, interne or the uninitiated in his haste to attempt to solve such obstetrical difficulties as prolapse of the umbilical cord, placenta praevia, prolonged labor with fetal distress, to mention a few, may without adequate consultation, undertake forceps delivery in a case where accurate information as to the station of the head, (and unfortunately in some cases dilatation of the cervix and cephalopelvic status), would have indicated the necessity for abdominal or other operative procedures.

On the Obstetrical Service at the National Naval Medical Center statistics reveal that of 2,384 deliveries during the period July, 1950 to July, 1951, we did 893 forceps deliveries. Of these there were none defined as high; 24 mid; 126 as low-mid and 743 as low, or outlet operations. The resident staff is cognizant of inaccuracy as to diagnosis; however, since adoption of this classification in July of this year it is already obvious that a more adequate evaluation is being made and the incidence of low-mid application shows a marked increase in the number reported.

It is believed that careful consideration of this paper with the classification, clear-cut definitions and commendable statistics will result in fewer "failed forceps," and will also aid in lowering infant and maternal mortality and morbidity. It emphasizes the importance of certain standardizations in classification and nomenclature, especially significant in obstetric teaching and, since the author's concept is in agreement with that of the aforementioned authors in their textbooks of obstetrics, this paper will serve to create a better understanding and more intelligent practice in forceps procedures.

I wish at this time to express my appreciation to Doctor Dennen for a copy of his "Manual of Forceps Deliveries" and to report that it serves as a very useful guide and ready reference for the staff, residents and internes on our service at the Naval Medical Center in Washington.

I wish to thank Doctor Dennen and the program committee for the opportunity to discuss this very excellent paper.

DR. N. J. EASTMAN, Baltimore, Maryland.—Mr. President, Fellows and Guests: Just two years ago, at the meeting of the Association here, the late Dr. Titus, Dr. Greenhill, Dr. McCormick and I endeavored to formulate a classification of forceps operations which would be, (1) *simple*; (2) *practicable with or without X-ray help*, and (3) *conductive* to the safest possible management of the second stage of labor. Only three types of forceps were considered.

High forceps was defined as the application of the forceps before engagement has taken place. About this definition everyone is in agreement and, clinically, it is easy to demonstrate by the fact that the presenting part has not yet reached the level of the ischial spines.

Low forceps was defined as the application of forceps when the head is visible, the skull is on the perineal floor and the sagittal suture is in the anteroposterior diameter of the pelvis. As will be noted in a moment, our 3-point definition of low forceps has not met with unanimous approval.

Mid forceps was defined as the application of forceps before the criteria of low forceps have been met, as stated above, but after engagement has taken place.

This classification of forceps was used at the Johns Hopkins Hospital in 1950 with the following results: Total forceps incidence, 33.1 per cent of all deliveries;

low forceps, 25.8 per cent of all deliveries; mid forceps, 7.3 per cent of all deliveries; no high forceps.

The chief objection to the low forceps definition has been that rotation of the sagittal suture to the anteroposterior diameter is demanded. It is argued that rotation does not necessarily indicate station. Theoretically, this is true but in actual clinical practice the head which is on the perineal floor and has rotated to an anterior is lower, on the average, than the head which has not yet rotated. Moreover, if these criteria for low forceps are met — head visible, skull on perineal floor and anterior rotation accomplished — the forceps procedure becomes a very easy maneuver which calls only for finger and wrist action. If the head has not rotated, the extraction may also be easy, of course, but again it may not be. And here is where trouble may ensue.

This leads us to the abuse of so-called "low forceps." As you all know, it is a regulation in many hospitals to demand that any general practitioner must call an obstetric specialist in consultation for any forceps procedure other than the low forceps operation. As you all know, there are several reasons why general practitioners would like to avoid calling consultation under this regulation and, consequently, the country over the term "low forceps" has become so elastic that it can be stretched about as high as the practitioner's conscience will permit. Most of you have doubtless seen in consultation some of these attempted and failed "low forceps" cases, so-called, and find, as I have, that what the practitioner had called a low forceps was actually a mid forceps with the head in transverse or R.O.P. position. It is our hope that general acceptance of our rigid definition of low forceps will lead to giving second stage patients more time to rotate the head until the case does meet these criteria. In the hands of general practitioners and specialists alike, this policy will inevitably conduce to a higher proportion of easy forceps deliveries and hence a safer second stage.

Doctor Dennen is to be complimented for having presented the first paper on classification of forceps which has appeared in many years, I believe, and his analysis of a large series of forceps deliveries shows that his classification works out satisfactorily in his clinic. He stresses the point that the lumping of all forceps operations between low and high into one group, mid forceps, as is done in our classification, leaves much to be desired; and others have made the same criticism. For accurate analysis of forceps operations, such a breakdown of mid forceps is avowedly advantageous, but I doubt if it can be done with consistent accuracy without extensive help from x-ray pelvimetry because it is just in those mid forceps cases that molding of the head may be most misleading in regard to the actual station of the bilateral diameter. But, be this as it may, our classification of forceps operations has as its main desideratum the three-point definition of low forceps, as stated, and for the sake of safer obstetrics the country over, it is our hope that eventually this definition will gain general acceptance.

DR. J. BAY JACOBS, Washington, D. C.—Some very practical views relative to the classification of forceps deliveries were presented by Dr. Dennen as well as by Dr. Eastman. I prefer Dr. Dennen's classification because it gives us the relationship between the biparietal diameter and a particular plane of the pelvis and, theoretically at least, we seem to have an understanding of the exact station of the head.

Peculiarly enough, there are more low-mid forceps deliveries performed with less fetal and maternal trauma than mid forceps deliveries, in spite of the fact that the low-mid forceps is concerned with the plane of least pelvic dimension.

This I would attribute to the fact that the head had descended lower.

Prognosis could be predicted more accurately, as suggested by Doctors Dennen and Eastman, if a lateral roentgenogram were taken; and again I would like to emphasize that this should be done in a standing posture, for when the patient is in the recumbent posture the head frequently ascends. One should also take into consideration the depth of the pelvis and here again the lateral roentgenogram is of greatest value. In a deep pelvis, one may find the biparietal diameter below the inlet even though the presenting part is some distance above the ischial spines. Without the lateral roentgenogram, one would interpret a case of this type as not engaged.

Dr. Dennen has presented very favorable statistics on a series of forceps deliveries, the results of which correspond closely with a series reported previously in his manual on the use of forceps.

Although I am an advocate of the use of forceps, I do not favor prophylactic forceps deliveries. I believe that many patients who are delivered by low-mid or outlet forceps could be nicely managed with suprafundal pressure applied at the height of a contraction under moderate anesthesia. Occasionally a combination of forceps traction and suprafundal pressure is desirable. It is my impression that this procedure is attended with less trauma. However, the frequency and the method of performance of forceps deliveries should be left to the judgment of the qualified obstetrician.

DR. THADDEUS L. MONTGOMERY, Philadelphia, Pennsylvania.—I presume it is necessary to have more exact classification, particularly of forceps, which in some areas has become an almost universal operation for delivery. One might suggest that there be added to such a classification the statement that a perineal forceps is one in which the delivery would have been completed spontaneously in fifteen or twenty minutes, with episiotomy, if the operator had been willing to wait that length of time; a low forceps is one in which the head is beginning to gradually distend the perineal muscles, as is the natural mechanism of labor; and that a low mid-forceps is the level to which the head usually recedes after a low spinal or saddle block anesthesia has been given.

I am afraid these comments will not help to clarify the discussion, although they may lay emphasis again on the fact that there is such a thing as mechanism of labor, and it is going to take a long time to prove satisfactorily that artificial delivery with forceps requiring as it does some form of anesthesia, is ultimately better for mother and baby than natural delivery.

If one reserves the operation of forceps for those instances where a properly rested mother does not make progress in labor, her safety or that of the baby being endangered, and where the pelvis is adequate for vaginal delivery, and other conditions of dilatation, etc., are appropriate, then one is not too greatly concerned whether the head is two cms. below the spine or five or six cms. below the spine, just so it is engaged. This case then becomes a problem and an indication unto itself and the minutiae of classification become relatively less important.

DR. EDWARD H. DENNEN, New York, N. Y. (closing).—This controversial subject has been considered before. Perhaps it has not been mentioned frequently enough, nor with enough emphasis because the standard classification is still low, mid and high forceps, despite the well known limitations of this type of classification. Even though it may complicate the classification somewhat, I am fully convinced that by adding another type of operation, making it 4 instead of 3,

the results will be improved. From the anatomical standpoint the pelvis with its 4 major planes requires 4 types of operation.

The question of necessity of an operation from the standpoint of an iron-clad indication is an entirely different subject. It is one that would take too long to discuss thoroughly at this time. It has been shown elsewhere by a number of people, and it was mentioned by myself, that the mortality due to accidents occurring in the second stage of labor has been reduced by the use of prophylactic forceps. The objections to that procedure are well known and some have been mentioned just now. Regardless of this, the specialist should be prepared to reduce mortality as far as possible and he is negligent if he does not intelligently carry out that procedure.

In this particular series, the incidence of forceps delivery was 59 per cent, two-thirds of which were listed as prophylactic. We are fully satisfied that the mortality would have been considerably higher if we had not carried out that procedure. This is not the work of one man. It is the work over a period of years by a fluctuating staff that averages more than 40 different operators. We can show, and have shown, that the forceps infant mortality in a particular group over a ten-year period, both gross and corrected, is nearly one-half that of the spontaneous cases in the same series. Of course, that is variable and it means that attention should be paid to the spontaneous cases. That has been done in our own clinic. If the results in the spontaneous series are consistently good, you cannot improve them with a forceps delivery. Last year our corrected spontaneous mortality was reduced to zero but that was a situation which one could not expect to continue.

I hope that interest enough will be taken in the subject of classification of forceps operations so that it can be clarified to the satisfaction of the majority. I am grateful to all of the discussants for their constructive and complimentary remarks.