

MANAGEMENT OF OCCIPITOPOSTERIOR POSITION¹

WITH SPECIAL REFERENCE TO THE APPLICATION OF THE KJELLAND FORCEPS

BY SAMUEL J. SCADRON, M.D., F.A.C.S., NEW YORK CITY

OCCIPITOPOSTERIOR positions of the vertex occur so frequently and are sometimes associated with such serious results that one ought not to make an apology for presenting the management of these cases for consideration.

The obstetrical specialty, although a limited one, is almost an exact science, particularly when we deal with the relation of the passenger to the passage as we are guided by standard measurements of the pelvis and the fetal head. In spite of this fact the mode of procedure in the management of obstetrical complications is varied, depending upon the opinions of the accoucheur.

In persistent occipitoposterior positions it is axiomatic that a successful termination depends upon flexion and rotation of the head by maneuvers least dangerous to the life of the child and subsequent damage to the mother. In this paper I wish to corroborate the successful results obtained in these cases by the new method of application of the Kjelland forceps.

The occurrence of this complication according to most writers is about 20 per cent. Geddes in 300 cases found that 10.5 per cent of the posterior positions occurred in multiparæ and 20.8 per cent in primiparæ. Fortunately, spontaneous rotation takes place in a great percentage of these cases if the case is left to nature after a reasonable test. It is evident that this malposition prolongs labor. In 1,000 cases analyzed by Rice the average prolongation of labor in primiparæ was 4 hours and in multiparæ $3\frac{1}{2}$ hours.

In spontaneous rotation the occiput comes down with the head well flexed meeting the resistance of the pelvic floor and with good uterine contraction pushes the head forward so that it turns from the opposite sacro-iliac synchondrosis to a position under the pubic arch.

In another group of cases the head is not well flexed. Instead of the anterior fontanel being opposite the acetabulum, the frontal eminence is opposite to it.

Early in labor one frequently finds the head engaged in the transverse diameter, in cases with normal pelvis, and as labor advances the head changes into the oblique. Contrary to some of the modern new theories, the older textbooks teach us that the head always engages in the oblique diameter; therefore when labor progresses slowly with incomplete flexion rotation, you get deep transverse arrest of the head in the pelvis.

The diagnosis of occipitoposterior position ought to be made early and is not difficult unless the patient is obese or has a rigid abdominal wall; one can at onset of labor diagnose the direction of the fetal ovoid, presence of small, irregular and nodular parts, situated in the median line. Auscultation may sometimes be of aid, for the heart sounds are usually heard toward the flank to which the back is directed.

Vaginal examination reveals some of the characteristics which make the diagnosis positive. The cervix is usually not taken up as the presenting part does not press firmly against the lower segment. The location of the large and small fontanel can be easily felt. The sagittal suture can be felt to lie across the oblique or transverse diameter. If labor is advanced it is sometimes difficult to diagnose the various sutures and the fontanel on account of the overlapping sutures. In that event the ear must be located and it will point in the transverse diameter or toward the sacrum, indicating the direction of the occiput.

After all is said and done regarding the diagnosis of occipitoposterior positions, the suggestive signs in the history of labor are almost pathognomonic. When a patient gives a history of early ruptured membranes, primary inertia, slow progress in labor pains, especially when referred to the back, with slight uterine contractions, one can be justified in making a snap diagnosis of mal-presentation of the head without examination.

Nearly every obstetrician has had in his personal experience or has been called to see with other

¹Read before the Harlem Medical Society, March, 1924.

men cases in which repeated unsuccessful attempts with forceps had been made, and on examination has found the cause of the failure to be an undiagnosed occipitoposterior position.

In considering the management of these cases, assuming early diagnosis, I will divide the cases into the following groups.

1. When the head is unengaged with the membranes intact and the large diameter of the head above the brim.

2. When the head is engaged in the pelvis but still above the spine of the ischium.

3. When the head is low down in the pelvis.

In the first class of cases, a great many authorities have advised external manipulation of the anterior and posterior shoulders. Personally I have never succeeded and usually leave these cases to take their normal course with watchful waiting. If, however, the membranes have ruptured, the amniotic fluid has drained away, and the cervix is not dilatable, it is advisable to introduce a hydrostatic bag to aid dilatation of the cervix and thus shorten labor.

In the second group, when the head is in the parturient canal and when the occiput remains persistently posterior in spite of a long test given for spontaneous rotation, there are several methods advocated.

1. Leaving the case to nature hoping for spontaneous rotation.

2. Manual rotation of the head with external rotation of the shoulders. A recent maneuver recommended by Lamond Lackie is one in which the operator passes his hand beyond the head intra-uterine to the shoulder, and rotates the trunk by the internal hand. This maneuver is not simple.

3. Manual rotation with forceps extraction.

4. Forceps extraction with the occiput remaining in the posterior position.

5. Podalic version.

In the third group, double application of forceps with its many modifications recommended by Scanzoni has been advised especially when the head is low down.

With regard to leaving the persistent occipitoposterior position to nature, it is advisable to permit a reasonable test of labor, by that I mean not to test the endurance of the mother but to observe her accomplishments in a definite period of time, not more than 2 hours in the second stage, and then proceed as advisable. It seems to me it is criminal neglect to wait for exhaustion of the mother or impending death of the child before interference is begun. In reference to manual rotation, one cannot always achieve

success with this maneuver alone without intra-uterine manipulation harmful to the mother. The question of version in occipitoposterior position especially when labor is well advanced with the head in mid-plane is a momentous one, for in the hands of the average obstetrician the procedure is so dangerous that it ought not to be advocated as a method of choice.

Up to the present time the methods which have rendered the best results in the treatment of these cases are extension and rotation of the head with forceps followed by extraction.

This maneuver necessitates the application and reapplication of forceps which are not always easily applied, and some have advocated a two-forceps maneuver which has given excellent results.

A word about the Kjelland forceps before I attempt to advocate their use. A great many forceps have been invented within recent years, and a great many changes in modification are continually being made, but we must admit that the forceps universally accepted as the best are those with the Tarnier axis—traction forceps. In spite of this fact the only advantage gained by this instrument is the question of traction. The biparietal application with Tarnier forceps when the head is in the mid-plane is just as difficult as with the ordinary forceps, Simpson or Elliott. This difficulty in application led Kjelland to invent a new model with which the application of forceps in mal-positions of the head was simplified and easy delivery made possible.

The new model forceps should not be applied in a contracted pelvis but only in cases in which the forceps themselves play a rôle in the delivery; in other words, they should be used only in those cases in which the ordinary models have failed or given bad results. When we have bad results with forceps delivery, we usually blame the contracted pelvis or a marked disproportion.

With ordinary forceps, it is difficult to make a biparietal application especially when the head is not well engaged or when it fills the pelvis; it is necessary to make a pelvic application to the anterior and posterior diameter of the head and the blades come in contact with the forehead which cannot stand much pressure; the blades are separated and come in contact with soft parts and vaginal folds which are fixed and when an attempt is made to rotate, the soft parts are injured. Old forceps fail because they slip when biparietal application is attempted, and it is therefore impossible to rotate in these cases. During the application the anterior fontanel is pushed forward toward the symphysis because

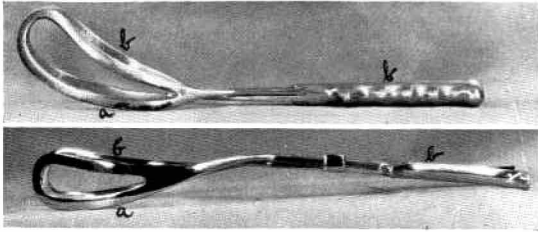


Fig. 1. Above, Elliott forceps; below, Kjelland forceps.

the blades do not grasp the head; when traction is made it therefore slips to the front. If one blade is applied to the posterior temple bone and the other to the occipital a good grip is obtained but delivery cannot be effected because the resistance of the frontal bone against the symphysis is too great.

A great many patients that have had difficult forceps deliveries with stillbirths come for subsequent examinations and antepartum care. To our surprise we find that most of them have had a normal pelvis or only a moderate degree of pelvic contraction, and there is no doubt but that the bad results were attributable to the faulty application of the forceps.

The construction of the Kjelland forceps is such that the blades can be applied more easily in transverse and oblique positions of the head. The points of difference between these and the ordinary models are the following:

1. The pelvic curve is less than in the ordinary blades making extraction easier and safer (Fig. 1, a).
2. The concavity of the pelvic curve is on a line with the handles of the blades (Fig. 1, b).
3. The lock-sliding arrangement permits accommodation (Fig. 2).
4. The connection between the blades and lock is longer than in other models, and is round and narrow so that the blades can easily be turned on the axis in utero. (Fig. 3, a).
5. The internal surfaces of the blades are convex, a cushion-like effect producing less pressure and cutting than the ordinary model (Fig. 3, b).

The application of these forceps has been successful in cases in which the ordinary forceps were difficult to handle or had failed; with the Kjelland it is possible to get the good grip necessary if the normal mechanism is to effect complete delivery with the least danger to the child. The points of the blades rests on the cheeks near the angle of the mouth and the blades embrace the biparietal protuberances; from the points of the blades the force is transmitted to that part of the head which can best withstand pressure.

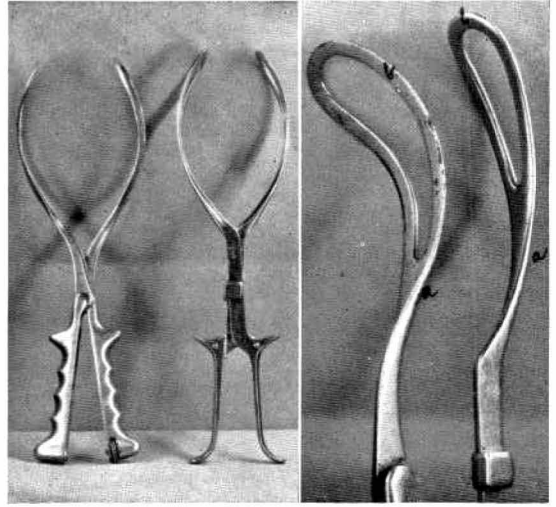


Fig. 2 (left). Another view of forceps shown in Figure 1.

Fig. 3. View showing the difference in the blades of the two forceps.

The pressure, however, is reduced to a minimum. With the ordinary forceps it is sometimes impossible to avoid having the blades grasp the neck and thereby cause compression, which is especially dangerous for the child if there is a loop of cord around the neck.

At first this method of application seems dangerous as compared with the ordinary methods, but this element of fear is soon eliminated when one convinces himself of the ease of introduction and extraction without any or very little resistance. However enthusiastic we become we must not forget that the Kjelland forceps have their limitations, as in the contracted pelvis with rigid soft parts in old primiparæ.

RULES FOR APPLICATION

To make a biparietal application when the sagittal suture lies in the transverse diameter of the pelvis and the head is in the mid-plane

1. Have the patient in the lithotomy position on the edge of the table.
2. Before applying the forceps, be absolutely positive that your diagnosis is correct as to the situation of the head, the sagittal suture, and anterior and posterior fontanels.
3. Hold the forceps in the direction which you wish them to assume in the pelvis with the concavity of the pelvic curve toward the posterior fontanel. The blade which lies anteriorly is the one which should first be applied between the symphysis and the head. (One can also use the lock as a guide to point toward the position of the

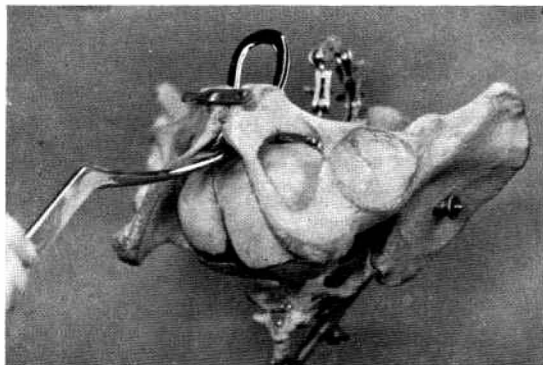


Fig. 4. Position of anterior blade. Concavity of fetal curve upward.

small fontanel.) Place two fingers of the hand under the anterior cervical lip; with the other hand grasp the handle of the blade; pass the forceps horizontally with the concavity of the fetal curve upward. Now pass the blade up against the head and the handle of the blade is lowered; pass it upward between the head and cervix under the symphysis (Fig. 4); this is done slowly and gently, as long as no resistance is met, until the middle round portion of the forceps rests in the postvaginal wall; rotate the blade on the head, rotate it toward the side to which the pelvic curves originally pointed—that is, when the concavity of the forceps grasps the convexity of the fetal head, rotate about 90 degrees. In order not to become confused as to which side the concavity of the forceps lies on, after they are introduced note that on either side of the handle there is a small button (Fig. 2). Rotate this toward the side on which the button is situated.

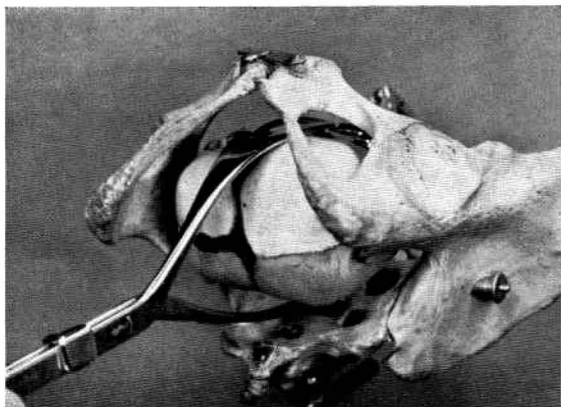


Fig. 6. Position of anterior blade after rotation of the anterior surface of fetal head. Application of posterior blade.

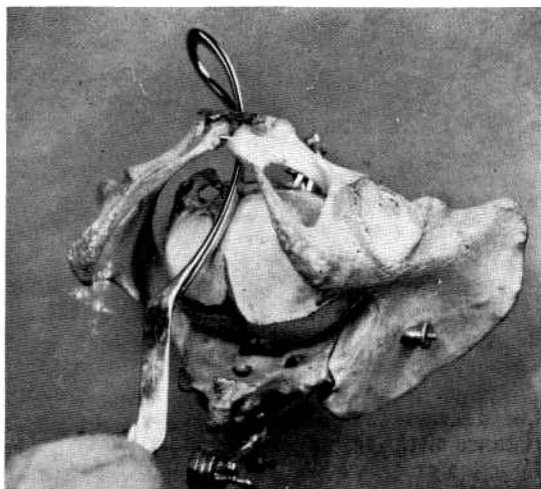


Fig. 5. Rotation of anterior blade.

After rotation the blade will slip up a little higher than at the time of introduction, if it was not originally introduced high enough. After rotation the lock lies against the postvaginal wall. No assistant is needed to hold this blade in position. The handle should rest in the center of the introitus unless the head is very high up.

The second blade is applied in the following manner: pass two fingers into the vagina to the posterior cervical lip; pass the second blade posteriorly on the side where the lock will approximate, and then introduce the blade gently to the side or in front of the promontory (Fig. 6). The blade usually meets no resistance unless the pelvis is contracted or the head impacted low down. In that event do not force the blade but gently manipulate it by lifting or lowering the handle of the blade. The lock is so constructed that it will approximate even if one blade is higher than the other. After the first attempt at traction both blades lock well. The forceps then lie in the anterior posterior diameter of the pelvis (Fig. 7). One can easily feel the direction of the handles. Do not use the symphysis as a pivot. You can now rotate the head if it is in mid-pelvis or you may make traction and rotate it nearly to the outlet. It is better to rotate first 90 degrees turning the sagittal suture from the transverse to the anterior posterior diameter. This rotation is performed without any traction, having the forceps well locked; then you make traction in the direction of the handles and the blades now lie in the transverse diameter of the pelvis (Fig. 8). As you approach the outlet it is not necessary to lift the handles to extract the head. When the

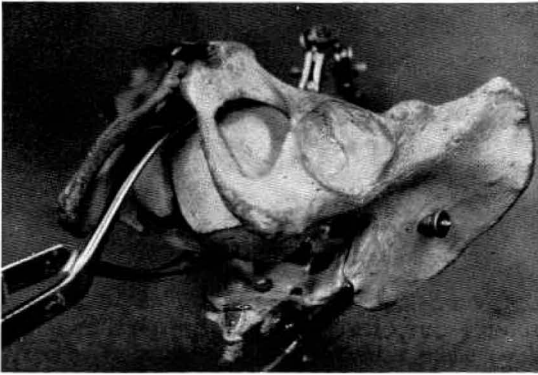


Fig. 7. Biparietal application with head in transverse diameter of pelvis.

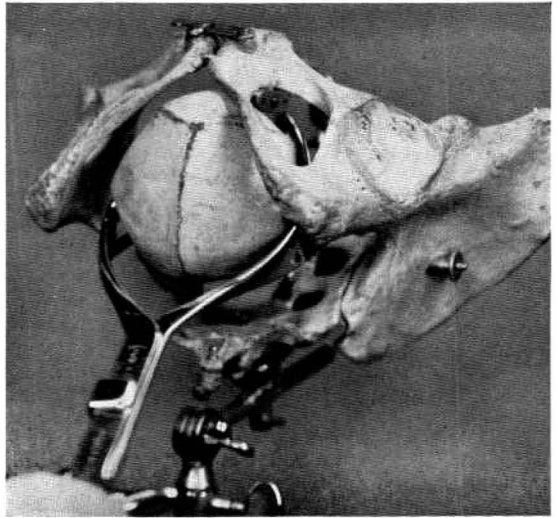


Fig. 8. Position of forceps after rotation.

head is in the occipitosacral position with the forehead anterior, you apply the blades in the same manner; the application then is only an oblique one on the fetal head and after slight traction the head accommodates itself in the transverse diameter of the pelvis. Finally proceed in same manner as just described. This method is called the inversion method. In cases in which the head is impacted low down in the transverse diameter of the pelvis, it is sometimes difficult to apply the anterior blade between symphysis and the fetal head. In that event it should be applied to the side opposite the small fontanel, as an ordinary cephalic application; then you glide the anterior blade adapting it to the side of the fetal head. The posterior blade is applied in the same manner as described above. This is called the gliding method.

The excellent results with the Kjelland forceps in mal-position of the vertex has already been reported by many authorities. Statistical reports show a low fetal mortality and very little injury to the fetal head. Bumm (Berlin) advocates very strongly the use of these forceps in occipitoposterior positions. In the Karmauner clinic in Vienna the forceps are strongly advocated not only in occipitoposterior positions but also in cases in which this complication occurs in a minor degree of contracted pelvis. They think that with the proper knowledge of the application of the forceps the prophylactic cæsarean may be abandoned.

Recently in the service of the Jewish Maternity Hospital and in my private practice we had wonderful success in the treatment of these cases with the Kjelland forceps. We collected about 100 cases in which we had most excellent, uniform results. In all the cases the mothers were discharged in good physical condition with no injuries to the bladder or perineum. Of course

prophylactic episiotomy was performed in nearly all the cases. There was no fetal mortality or injury except the ordinary marks of the blades which soon disappeared after delivery. While the number of cases in this report is small, we had some very difficult complications to deal with, and the outcome would not have been so successful with the ordinary forceps.

I will cite the following difficult cases:

CASE 1. A primipara, 24 years of age, was delivered by vertex presentation. Measurements in centimeters: interspinal, 26; intercrystal, 28; right oblique, 26; left oblique, 26; external conjugate, 20; internal conjugate, 10; the outlet was roomy.

The onset of pains occurred July 25, 1923, at 6 o'clock a.m. The patient was admitted to the hospital July 26 at 4 o'clock a.m. Vaginal examination: external and internal os, 1 finger dilated. The canal was $\frac{1}{4}$ inch long, the membranes were ruptured, the head was at the inlet in left occipitotransverse position. At 10 a.m., with 2 fingers' dilatation, the membranes spontaneously ruptured, and the head was at the inlet; the fetal heart sounds were normal. At 2 p.m. $\frac{1}{4}$ grain of morphine was administered. At 4:30 p.m., with 4 plus fingers' dilatation and strong pains the head was engaged in left occipitotransverse position. At 8:30 p.m., the temperature was 102, pulse 92, respiration 34. At 9 p.m., $\frac{1}{4}$ grain morphine was given; the dilatation was 4 plus fingers and the position unchanged. At 10 p.m., the patient was admitted to the delivery room.

Indication for interference. The first stage had lasted 40 hours and was not complete. It was a dry labor. The temperature was 102; fetal heart, 170.

Treatment. A bilateral cervical incision was made with the sagittal suture lying transversely; Kjelland forceps (inversion method) were applied and the head rotated and extracted. A right lateral episiotomy was done. Profuse bleeding followed and the placenta was extracted manually. The uterus was packed, and a hypodermatoclysis administered.

Postpartum course. Temperature 100.8 and 102 on the fourth day, 101 on the fifth and sixth day, 100 on the seventh day, and was normal thereafter. The patient remained in the hospital 14 days, and was discharged in good condition. The cervical incision and the perineum healed. The weight of the child was 8 pounds 14 ounces.

CASE 2. A primipara, age 29 years, was delivered by vertex presentation, right occipito-anterior position. Measurements in centimeters: interspinal, 23; intercrystal, 24 plus; right oblique, 25; left oblique, 25; external conjugate, 20. The promontory was not felt; the outlet was roomy. Labor was begun 11 o'clock p.m., August 26. Patient was admitted to hospital August 27, 1 o'clock a.m., because of strong contractions. Vaginal examination showed external os closed. At 9 a.m., the external os admitted 1 finger, internal os was obliterated; the membranes were intact. Morphine, $\frac{1}{4}$ grain, was administered. At 4 p.m., there was 1 finger's dilatation, thick cervix, membranes ruptured, head engaged, fetal heart normal. At 5 p.m., a hydrostatic bag (Voorhees) was introduced. August 28, at 6 o'clock a.m., the bag was expelled, the os was 4 plus fingers dilated, cervix thick, head engaged, right occipitoposterior position. At 2:40 p.m., the os was 5 fingers dilated, and meconium was passing. Delivery occurred at 3:10 p.m.

Indication for interference. Dry labor had lasted 40 hours and the first stage was not complete. The cervix was undilated. The meconium was passing, the death of the child impending, and the head was in right occipitoposterior position.

Treatment. A bilateral incision was made in the cervix; Kjelland forceps (inversion method) were applied with rotation and extraction. Postpartum course. On the third day the temperature was 103.8, pulse 126; fourth day, temperature, 98, pulse 101.6; on the thirteenth to sixteenth days both were normal. The patient remained in the hospital 17 days, and was discharged in good condition. The cervical incision healed by primary union. The weight of the child was 6 pounds 14 ounces.

CASE 3. A primipara, age 24 years, had a vertex presentation, left occipitoposterior position. Measurements in centimeters: interspinal, 23; intercrystal, 26; right and left oblique, each, 27; external conjugate, 21; the promontory was not felt. Patient was admitted August 20, 1923, 6:30 o'clock p.m.

The onset of pains was August 18 at 1 o'clock p.m. On admission the external and internal os admit 1 finger; canal, 1 centimeter long; membranes intact; vertex at inlet. At 7 p.m., castor oil, 2 ounces, was given. At 12 p.m., os was 2 fingers dilated, cervix thin, membranes intact, left occipitoposterior position, pains strong.

August 21, 1:40 a.m., the os was 4 fingers dilated, and the membranes ruptured spontaneously. At 8 a.m., the os was 4 fingers dilated, the head engaged, fetal heart normal. At 8:30 a.m., morphine, $\frac{1}{4}$ grain, was given. At 4 p.m., the os was still 4 fingers dilated, and pituitrin, 3 minims, was given. At 5 p.m., no progress had been made.

Indications for interference. The first stage of labor had lasted 46 hours and was not complete; the patient was exhausted. It was a dry labor; left occipitoposterior position.

Treatment. A bilateral cervical incision was made and Kjelland forceps (inversion method) were applied with rotation and extraction. An episiotomy was done.

The postpartum course was normal. The patient remained in the hospital 10 days and was discharged in good condition. The cervical incision and perineum healed by

primary union. The weight of the child was 7 pounds 5 ounces.

One can readily see that in these cases interference was imperative not only to save the life of the babies but also to terminate the exhaustive labors of the mothers. The ease with which the heads were rotated and extracted would thoroughly convince the obstetrician of the efficacy of this maneuver.

The technique in this maneuver is very simple. The necessary knowledge as to the direction of the fontanel and the proper placing of the sagittal sutures can certainly be easily acquired. The diagnosis is not always easy. However if there is any doubt, the whole hand should be inserted before an attempt is made to apply this maneuver. When it is impossible to make a diagnosis as to the position of the head the forceps should not be applied for failure will surely result.

ADVANTAGES

Before concluding I wish to review some of the advantages of these forceps over the ordinary forceps.

1. They are easy to apply in spite of the position of the head, and the direction of the sagittal sutures; no special experience in technique is required.

2. The position of the head is not altered by the application. This is an important fact, especially when there is slight pelvic contraction, in which case the ordinary forceps displace the head defeating nature's attempt.

3. It is necessary to introduce only two fingers instead of the whole hand as is sometimes necessary when the head is high up. This reduces the chances of infection.

4. The biparietal application does not permit the slipping of forceps. The point of the blades remains on the face near the chin and the blades run parallel with the long axis of the ovoid head and firmly grasp the head. The traction on the face is not only directed against the points but there is an even pressure of the entire instrument. There is no direct pressure over the eye, no pressure on the face, neck or facial nerve as with ordinary forceps.

5. Better rotation is obtained because the forceps can be applied in one position.

6. This application aids the normal mechanism in terminating labor.

7. Less force is required.

In conclusion, I wish to state that while these forceps have many advantages over the old, the range of indication should be no wider for them than for the ordinary blades.